

Dermatitis Caused by *Candida albicans* in a Captive Spotted Seal (*Phoca largha*)

Kyung-Yeon Eo and Oh-Deog Kwon*¹

Seoul Zoo, Gwacheon 427-702, Korea

*College of Veterinary Medicine, Kyungpook National University, Daegu 702-701, Korea

(Accepted: August 11, 2014)

Abstract : Candidiasis caused by *Candida albicans* is a localized mucocutaneous disease. It occurs worldwide in various kinds of animals. A 7-year-old male spotted seal weighing 98 kg showed facial skin lesions. The present case was characterized by erythematous, thickened, and alopecic skin lesions in the periocular region and on the commissure of the lower lip. For diagnosis, skin scraping and culture of samples from the facial skin lesions were done. Colonies were cream-colored and glistening after 3 days of culture on Sabouraud dextrose agar. Typical yeast-like cells were observed by microscopic inspection after Gram staining. Recovery was achieved with itraconazole (1 mg/kg SID) for 7 days, repeated three times at 2-week intervals.

Key words : *Candida albicans*, Dermatitis, *Phoca largha*, Spotted seal.

Introduction

The spotted seal (*Phoca largha*) belongs to the Phocidae family, the suborder Pinnipedia, and the order Carnivora (5,8). It is widely distributed in the northern Yellow Sea, Bohai Sea, East Sea, Sea of Okhotsk, Tartar Strait, Bering Sea, Sea of Japan, Chukchi Sea, and Beaufort Sea in the North Pacific Ocean, and in summer also the eastern Korean Peninsula (3, 8,11). However, it is an endangered marine mammal, and is categorized as a critically endangered species in China and Korea (3). Spotted seals have been designated as Natural Monument No. 331 and a second-class endangered wild animal species in Korea.

Candida yeasts are the most common cause of fungal skin diseases in captive marine mammals (4,9). Infection can cause purulent nasal discharge, inflammation of the lips at the mucocutaneous junction, periocular alopecia, vaginitis, and dermatitis in captive pinnipeds (2). However, to the best of our knowledge, there have been no previous reports on candidiasis in spotted seals in Korea, neither in the wild nor at zoos and aquariums. We diagnosed candidiasis caused by *Candida albicans* in a captive spotted seal. We report this case to provide information regarding the risk of dermatitis caused by *Candida albicans* in wild and zoo marine mammals in Korea.

Case

Eight seals-six harbor seals (*Phoca vitulina*) and two spotted seals (*Phoca largha*)-were housed in outdoor and indoor

freshwater pools without sand filters. The water was supplied from underground using an electric pump. All water in every pool was changed every other day. The average temperature of the water was between 15°C and 25°C. To maintain a proper water temperature (less than 24°C) the pool was flooded with pumped water in the summer. The average temperature of the water in winter was 16°C. The seals were fed once a day on a diet of Alaska pollock (*Theragra chalcogramma*), Atka mackerel (*Pleurogrammus azonus*), and Pacific mackerel (*Scomber japonicus*). The diet was supplemented with multivitamins. Among these animals, a 7-year-old male spotted seal weighing 98 kg showed facial skin lesions: erythematous, thickened, and alopecic lesions in the right periocular region and on the commissure of the lower lip (Fig 1). The lesions were examined closely and scraped to obtain samples under restraint with nets by three zoo keep-




Fig 1. The lesions were distributed in the periocular region and on the commissure of the lower lip.

¹Corresponding author.
E-mail : odkwon@knu.ac.kr

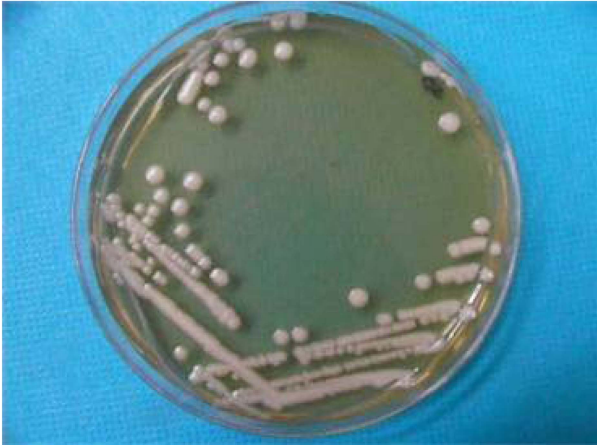

Fig 2. The colonies were cream-colored and glistening after 3 days of culture on Sabouraud dextrose agar.




Fig 3. Dark purple round to oval yeast-like cells were observed by microscopic inspection ($\times 100$) because *Candida albicans* retains crystal violet stain in routine Gram staining.



Fig 4. After administration of itraconazole, the lesions were gradually ameliorated. The photograph was taken about 6 months after drug administration.

ers. Sampling for diagnosis was done by skin scraping and culture of swabs from the facial skin lesions. The samples were cultured on Sabouraud dextrose agar for 72 h at 30°C. Colonies were cream-colored, smooth, and glistening (Fig 2).

Microscopic examination after smearing on a glass slide and Gram staining showed round to oval yeast-like cells (Fig 3). *Candida albicans* was the only organism isolated from the skin lesions; it was not isolated from the adjacent normal skin. Diagnosis was typical localized candidiasis caused by *Candida albicans*. Itraconazole (1 mg/kg SID) was administered with food (mackerel) for 7 days. This treatment was repeated three times at 2-week intervals. Recovery took about 6 months after initial treatment with itraconazole (Fig 4).

Discussion

Candidiasis is a common disease of captive marine mammals (2). In phocids it is characterized by inflammation at mucocutaneous junctions, especially the commissures of the mouth, and the periocular, perivulvar, and perianal areas (4). Multiple large areas of alopecia and erythema of the eyelids, lips, and abdomen were found in candidiasis in a harbor seal (*Phoca vitulina*) and elephant seals (*Mirounga angustirostris*) (6,10). The clinical findings in the present case were erythematous, thickened, and alopecic skin lesions in the right periocular region and on the commissure of the lower lip. They were very similar to those reported by others.

Candidiasis is diagnosed by isolation of *Candida* spp. from skin lesions (6,7). Sampling for diagnosis was done by skin scraping and culture of swabs from the facial skin lesions. The isolated yeast was identified as *Candida albicans*. We confirmed the diagnosis of fungal dermatitis from the skin lesions and culture.

According to Uchida *et al* (12), itraconazole is useful for the treatment of candidiasis. In this report, the seal was treated by oral administration of itraconazole (1 mg/kg SID) for 7 days, repeat three times at 2-week intervals, and recovered completely about 6 months after initial treatment.

Candida albicans is a common opportunistic pathogen that causes a variety of diseases in humans and animals (1,4). It is a normal inhabitant of the skin and gastrointestinal tract. Occasionally, it invades deeper portions of the mucous membranes, skin, and other tissues in humans and animals (7). Debilitation, immunosuppression, and long-term use of antibiotics predispose to candidiasis. Although the source of *Candida albicans* in the present case is uncertain, it represents a potentially serious threat to zoo marine mammal species. Therefore, all wild and zoo marine mammals should be examined carefully for signs of *Candida albicans* infection, and monitoring programs should be established to provide prompt diagnosis of clinical infections (2).

References

1. Bahnan W, Koussa J, Younes S, Abi Rizk M, Khalil B, El Sitt S, Hanna S, El-Sibai M, Khalaf RA. Deletion of the *Candida albicans* PIR32 results in increased virulence, stress response, and upregulation of cell wall chitin deposition. *Mycopathologia* 2012; 174: 107-119.
2. Dunn JL, Buck JD, Spotte S. Candidiasis in captive pinnipeds. *J Am Vet Med Assoc* 1984; 185: 1328-1330.
3. Gao X, Han J, Lu Z, Li Y, He C. De novo assembly and characterization of spotted seal *Phoca largha* transcriptome using Illumina paired-end sequencing. *Comp Biochem Physiol*

- Part D Genomics Proteomics 2013; 8: 103-110.
4. Higgins R. Bacteria and fungi of marine mammals: A review. *Can Vet J* 2000; 41: 105-116.
 5. Ishinazaka T, Suzuki M, Mizuno AW, Harada N, Mason JJ, Ohtaishi N. Immunohistochemical localization of steroidogenic enzymes and prolactin receptors in the corpus luteum and placenta of spotted seals (*Phoca largha*) during late pregnancy. *J Vet Med Sci* 2002; 64: 329-333.
 6. Nakagawa S, Masui M, Tashiro K, Tanabe K. A case of candidiasis in a harbor seal (*Phoca vitulina*). *J Jpn Assoc Zool Gard Aquat* 1967; 9: 95-98.
 7. Nakeeb S, Targowski SP, Spotte S. Chronic cutaneous candidiasis in bottle-nosed dolphins. *J Am Vet Med Assoc* 1977; 171: 961-965.
 8. Perrin WF, Würsig B, Thewissen JGM. Harbor seal and spotted seal. In: *Encyclopedia of marine mammals*, 2nd ed. London: Academic Press. 2009: 533-542.
 9. Pollock CG, Rohrbach B, Ramsay EC. Fungal dermatitis in captive pinnipeds. *J Zoo Wildl Med* 2000; 31: 374-378.
 10. Reichel K, Mayer H. Candidiasis in seals (*Mirounga leonina*). *Prakt Tierärz* 1978; 59: 110-111.
 11. Shaughnessy PD, Fay FH. A review of the taxonomy and nomenclature of north pacific harbor seals. *J Zool* 1997; 182: 385-419.
 12. Uchida K, Shimogawara K, Yamaguchi H. Correlation of in vitro activity and in vivo efficacy of itraconazole intravenous and oral solubilized formulations by testing *Candida* strains with various itraconazole susceptibilities in a murine invasive infection. *J Antimicrob Chemother* 2011; 66: 626-634.

점박이물범에 발생한 칸디다 피부염

어경연 · 권오덕*¹

서울동물원, *경북대학교 수의과대학

요 약 : 7년령, 체중 98 kg의 수컷 점박이물범에서 아랫입술과 눈 주위에 홍반, 탈모, 비후 등을 특징으로 하는 피부염이 관찰되었다. 진단을 위해 병변부위 피부소파를 실시하고 Sabouraud dextrose 배지에서 3일간 배양을 하였다. 그 결과 크림색의 윤기 있는 둥근 집락들이 관찰되었으며 집락을 슬라이드글라스에 도말하여 그람염색처리 후 현미경검사를 실시한 바 전형적인 효모양의 세포들이 관찰되었다. 특징적인 피부염의 임상증상과 현미경검사로 칸디다증으로 진단하였으며 치료를 위하여 itraconazole 1 mg/kg을 2주간의 간격으로 1주일 동안 먹이와 함께 투약하는 것을 3회 반복하였으며 투약개시 후 6개월여 뒤에 완전히 회복되었다. 그동안 국내에서 점박이물범에서의 칸디다 피부염 증례보고는 없었다. 점박이물범이 천연기념물로 지정되었을 뿐 만 아니라 국제적으로도 멸종위기에 처한 야생동물인 만큼 본 증례보고가 사육 상태 또는 야생에서 칸디다 피부염의 진단과 치료에 도움이 될 것으로 생각된다.

주요어 : 점박이물범, 칸디다, 피부염, *Candida albicans*, *Phoca largha*