

RESEARCH ARTICLE

Roles of Sonography and Hysteroscopy in the Detection of Premalignant and Malignant Polyps in Women Presenting with Postmenopausal Bleeding and Thickened Endometrium

Sabri Cavkaytar¹, Mahmut Kuntay Kokanali^{1*}, Ufuk Ceran¹, Hasan Onur Topcu¹, Levent Sirvan², Melike Doganay¹

Abstract

Background: To assess the role of sonographic endometrial thickness and hysteroscopic polyp size in predicting premalignant and malignant polyps in postmenopausal women. **Materials and Methods:** A total of 328 postmenopausal women with abnormal uterine bleeding and thickened endometrium underwent operative hysteroscopy due to detection of endometrial polyps were included in this retrospective study. Preoperative endometrial thickness measured by transvaginal ultrasonography and polyp size on hysteroscopy were noted. Hysteroscopic resection with histology was performed for endometrial polyps. Endometrial thickness and polyp size were evaluated on the basis of final diagnosis established by histologic examination. Receiver operator characteristic curves were calculated to assess the sensitivity, specificity, positive predictive value, negative predictive value and diagnostic accuracy of endometrial thickness and polyp size for detecting premalignant and malignant polyps. **Results:** Premalignant and malignant polyps were identified in 26 (7.9%) of cases. Sonographic measurement showed a greater endometrial thickness in cases of premalignant and malignant polyps when compared to benign polyps. On surgical hysteroscopy, premalignant and malignant polyps were also larger. Endometrial thickness demonstrated a sensitivity of 53.8%, specificity of 85.8%, PPV of 24.6% and NPV of 95.6% at a cut-off limit of 11.5 mm with diagnostic accuracy of 83.2%. Polyp size has a diagnostic accuracy of 94.8% with a sensitivity of 92.3%, specificity of 95.0%, PPV of 61.5% and NPV of 99.3% at a cut-off point of 19.5mm. **Conclusions:** Endometrial thickness measured by transvaginal ultrasonography is not sufficient in predicting premalignant and malignant endometrial polyps in postmenopausal women with abnormal uterine bleeding and thickened endometrium. Polyp size on hysteroscopy is a more accurate parameter, because of better sensitivity and specificity. However, while polyp size ≥ 19.5 mm seems to have a great accuracy for predicting premalignancy and malignancy, histologic evaluation is still necessary to exclude premalignant and malignant polyps.

Keywords: Endometrial polyps - ultrasonography - hysteroscopy - malignancy - postmenopausal women

Asian Pac J Cancer Prev, 15 (13), 5355-5358

Introduction

Endometrial polyps are localized intrauterine disorders that may cause especially abnormal uterine bleeding (Dreisler et al., 2009a; Lieng et al., 2010). The exact incidence of this common gynecologic pathology is unknown, since many polyps remain asymptomatic (Lieng et al., 2009).

Even though it is uncommon, both atypical hyperplasia and endometrial cancer may originate from endometrial polyps. Recently, American Association of Gynecologic Laparoscopists (2012) has reported that malignancy occurs within 0% to 12.9% of endometrial polyps. Most authors also agree that the risk of malignancy in

endometrial polyps increases with age, particularly in the postmenopausal period (Ben-Arie et al., 2004; Ferrazzi et al., 2009; Costa-Paiva et al., 2011; Uglietti et al., 2014). And also, endometrial carcinoma is one of the most curable cancers as detected in early stages (Binesh et al., 2014). Therefore, early diagnosis and accurate treatment of endometrial polyps in postmenopausal women do have great importance in gynecologic practice. However, until now, no satisfactory screening methods have been established for the prediction of malignancy in these focal endometrial lesions and a histological investigation is required in all suspected cases.

In this study, we aimed to investigate the diagnostic value of sonographic endometrial thickness and polyp size

¹Department of Gynecology, ²Department of Pathology, Dr Zekai Tahir Burak Woman's Health Education and Research Hospital, Ankara, Turkey *For correspondence: kuntaykokanali@gmail.com

of surgical hysteroscopy in prediction of premalignant and malignant polyps in postmenopausal women presenting with abnormal uterine bleeding and thickened endometrium.

Materials and Methods

This retrospective study was conducted among the women who attended to the Gynecology Department of Ankara Dr Zekai Tahir Burak Woman’s Health, Education and Research Hospital with postmenopausal uterine bleeding and allocated to opeartive hysteroscopy due to detection of endometrial polyps between January 2012 and December 2013. The study was approved the Ethics Committee of Dr Zekai Tahir Burak Woman’s Health, Education and Research Hospital.

All of the clinical, pathological and sonographic data were obtained from medical chart records. Menopause was defined as spontaneous cessation of menses for 12 months or more. Demographic data including age, reproductive history, menopausal duration and concomitant medical history associated with endometrial cancer, such as body mass index, diabetes mellitus and hypertension were recorded. Preopratively, all patients underwent transvaginal ultrasound scanning to assess the endometrial thickness. Endometrial thickness was measured as a double layer in the longitudinal plane at the thickest part within the fundus and with the entire endocervical and endometrial stripe visible by using vaginal probe 7.5 MHz. Endometrial polyps were detected by diagnostic hysteroscopy in an office setting without any anesthesia nor cervical dilatation. Hysteroscopy was defined as completed when the entire uterine cavity was visualized. Operative hysteroscopy under general or spinal anesthesia was performed for endometrial polyps by using a 10 mm Karl Storz resectoscope. Evaluation of the endocervical canal and endometrial cavity was performed. The lesions were resected by loop electrocautery that relied on a monopolar electrical current. Final diagnosis of findings was the diagnosis applied after the histopathological result was received. Standard histopathological criteria were used for the diagnosis of the lesions. Polyps were classified as benign, premalignant (non-atypical or atypical simple glandular hyperplasia, non-atypical or atypical complex glandular hyperplasia) and malignant.

Statistical analysis was performed using the Statistical Package for Social Sciences 15.0 software (SPSS Inc., Chicago, IL,USA). Normality testing (Kolmogorow-Smirnow test) was performed to determine if data were sampled from a normal distribution. Continuous variables with normal distribution are presented as mean±standard deviation. Median (minimum-maximum) value is used where normal distribution is absent. For normally distributed quantitative variables, the difference between

the groups was evaluated by one-way Anova test. For the quantitative variables that were not normally distributed, the difference between the groups was evaluated by the Kruskal Wallis test. The chi-square test was used to evaluate qualitative variables. Hystologic diagnosis was used as the gold standard and Receiver Opearating Characteristic (ROC) curve was used to calculate the sensitivity and specificity for different measures of endometrial thickness and polyp size upon hysteroscopy. P < 0.05 was accepted as statistically significant.

Results

Between January 2012 and January 2014, 328 operative hysteroscopies were performed in postmenopausal women for resection of endometrial polyps. Histologic diagnosis identified the peresence of premalignant (6.1%) and malignant (1.8%) lesions in 26 (7.9%) of cases. There were no differences of demographic properties according to histologic diagnosis of endometrial polyp in postmenopausal women (Table 1).

Sonographic measurement of endometrial thickness in postmenopausal women undergoing hysteroscopic polypectomy revealed that mean thickness was 9.1±1.5 mm in benign polyps, 11.1±1.6 mm in premalignant polyps, and 14.5±1.4 mm in malignant polyps (p<0.001). Premalignant polyps caused significantly thicker endometrium as compared with benign polyps, while the malignant polyps revealed the significant thickest endometrium (Table 2). On the surgical hysteroscopy, the mean size of malignant polyps (3.0±0.2 mm) was significantly the largest one as compared with premalignant and benign polyps (2.4±0.5 mm and 1.2±0.4 mm, respectively) (p<0.001). In addition, the mean size of premalignant polyps was significantly greater than that of benign polyps (p=0.002) (Table 2).

A ROC curve was drawn to demonstrate the selectivity of sonographic endometrial thickness and polyp size by hysteroscopic surgery for detection of premalignant and malignant polyps (Figure 1). The area under curve was 0.83±0.04 (p<0.001; 95%CI 0.76-0.90) for sonographic endometrial thickness; 0.98±0.01 (p<0.001; 95%CI 0.95-

Table 1. Demographics of Groups

	Benign (n=302)	Premalignant (n=20)	Malignant (n=6)	P
Age*	57.0±6.9	59.0±8.2	55.2±2.9	0.38
Gravida#	4 (1-12)	5 (1-8)	4 (3-6)	0.95
Parity#	3 (1-12)	4 (1-8)	3 (2-4)	0.22
BMI*	26.2±1.3	26.4±1.4	25.8±0.4	0.50
Diabetes mellitus‡	109 (38.4)	14 (20.0)	2 (33.3)	0.24
Hypertension‡	105 (37.0)	7 (35.0)	1 (16.7)	0.66
Menopausal duration*	4.7±1.0	7.2±4.1	6.6±4.0	0.39

Values are given as mean ±standard deviation, median (minimum-maximum) or number (percentage); One –Way ANOVA test; Kruskal Wallis test; ‡ Ki-Kare test

Table 2. Table 2. Sonographic Endometrial Thickness and Polyp Diameter by Surgical Hysteroscopy in Groups

	Benign -A-	Premalignant -B-	Malignant -C-	P*	p#		
					A-B	A-C	B-C
Endometrial thickness	9.1±1.5	11.1±1.6	14.5±1.4	<0.001	<0.001	<0.001	<0.001
Polyp diameter	1.2±0.4	2.4±0.5	3.0±0.2	<0.001	0.002	<0.001	<0.001

Values are given as mean ±standard deviation; *One –Way ANOVA test; # Post-Hoc Tukey test; p<0.05 is considered statistically significant

Table 4. Accuracy of ultrasound and hysteroscopy in diagnosis of premalignant and malignant endometrial polyps in postmenopausal women

Cut-off point by ROC curve	Sensitivity (%)	Spesificity (%)	PPV (%)	NPV (%)	Accuracy (%)
Endometrial thickness ≥ 11.5 mm	53.8	85.8	24.6	95.6	83.2
Polyp size ≥ 19.5 mm	92.3	95.0	61.5	99.3	94.8

PPV: positive predictive value; NPV: negative predictive value

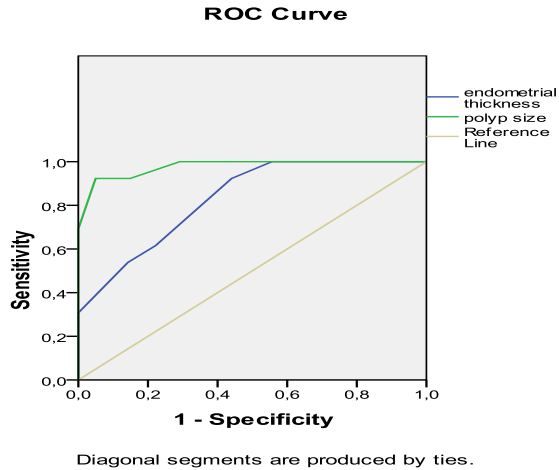


Figure 1. Receiver Operating Characteristics of Sonographic Endometrial Thickness and Polyp size of Surgical Hysteroscopy for Premalignant and Malignant Polyps

Table 3. Areas Under ROC Curve for Sonographic Endometrial Thickness and Polyp size of Surgical Hysteroscopy

	AUC	SE	P	95% CI
Endometrial thickness	0.83	0.04	<0.001	0.76-0.90
Polyp size	0.98	0.01	<0.001	0.95-0.99

AUC: Area Under Curve; SE: Standar Error; CI: Confidence Interval; * $p < 0.05$ is considered statistically significant

0.99) for polyp size (Table 3). The best cut off point for endometrial thicness established by the ROC curve was 11.5 mm, showing a sensitivity of 53.8%, specificity of 85.8%, positive predictive value (PPV) of 24.6 and negative predictive value (NPV) of 95.6 with diagnostic accuracy of 83.2%. On hysteroscopy diagnostic accuracy for polyp size was 94.8 and the best cut of point for polyp size was 19.5 mm by ROC curve, with a sensitivity of 92.3%, specificity of 95.0%, PPV of 61.5% and NPV of 99.3% (Table 4)

Discussion

Endometrial carcinoma is the most common gynecologic cancer that is often found in postmenopausal women (Turan et al., 2012). Although uncommon, endometrial polyps may be the potential origine of this malignancy, especially in postmenopausal women (Balik et al., 2012; Acmaz et al., 2014). Because of this, the detection of this common gynecologic disorder is important. In postmenopausal women, with the widespread use of ultrasound symptomatic and asymptomatic polyps are more frequently diagnosed than they were previously

(Dreisler et al., 2009a), but the role of sonography in detection of premalignant and malignant polyps is still little and controversy.

In literature, the sonographic endometrial thickness of 4-5 mm limits generally were used to exclude endometrial malignancy in symptomatic postmenopausal women, however these values were not transferable to women without abnormal uterine bleeding for exclusion of focal lesion (Gupta et al., 2002). A cut-off value of 11 mm for endometrial biopsy has been suggested for asymptomatic postmenopausal women (Smith-Bindman et al., 2004). Godoy et al. (2013) stated that ultrasound made it possible to rule out the presence of malignant polyps when the endometrial thickness was 13 mm, with a sensitivity of 69.6% and specificity of 68.5% in postmenopausal women. In another study, Dreisler et al. (2009b) showed that endometrial thickness ≥ 8.0 mm in postmenopausal period had a 96% sensitivity and 48% specificity with 70% PPV in detection of premalignant and malignant polyps. In our study, sonographic measurement of endometrial thickness was greater for premalignant and malignant polyps than for benign polyps. An endometrial thickness of ≥ 11.5 mm showed a value of 53.8% sensitivity and relatively high specificity (85.8%) in predicting malignancy in endometrial polyps.

Direct visualization of the uterine cavity is a simple and effective method for investigating endometrial pathologies. Thus, among the diagnostic methods, hysteroscopy gives the highest diagnostic efficacy in detecting endometrial polyps (Elfayomy et al., 2012). It also show great accuracy in diagnosis of focal endometrial pathologies which are hardly recognized by ultrasonography, especially thickenned endometrium that hidden the intracaviter lession (Ragni et al., 2005; Schmidt et al., 2009). Makris et al. (2007) showed that hysteroscopy with guided biopsy is the most common comparator for other techniques to diagnose polyps as it offers the highest sensitivity and specificity for conservative measures. Diagnostic hysteroscopy alone only allows subjective assessment of the size and characteristic of the lesion with reported sensitivity of 58% to 99%, specificity of 87% to 100%, PPV of 21% to 100%, and NPV of 66% to 99% when compared with hysteroscopy with guided biopsy (American Association of Gynecologic Laparoscopists, 2012).

In literature, there is few studies that have evaluated the relationship between the polyp size and the risk of malignancy. In a retrospective multicenter study included 1155 asymptomatic and 770 consecutive postmenopausal women with abnormal uterine bleeding, it was found that polyps' size with mean of >18 mm was the only variable significantly associated to an abnormal histology (cancer, polypoid cancer, and atypical hyperplasia) in

asymptomatic women (Lee et al., 2010). In a meta-analysis designed to analyze the oncogenic potential of endometrial polyps, four studies stated that larger polyps were directly associated with a greater risk of malignancy while the other four studies did not find any associations (Ferrazzi et al., 2009). More recently, Lasmar and Lasmar (2013) reported that endometrial polyps measuring more than 15mm were associated with hyperplasia. In our study, we have found that polyp size by surgical hysteroscopy was greater with premalignant-malignant polyps than with benign polyps. A polyp size of 19.5 mm showed the best sensitivity of 92.3% and specificity of 95.0% with high diagnostic accuracy (94.8%) in predicting premalignancy-malignancy in endometrial polyps.

In conclusion, sonographic endometrial thickness does not have sufficient sensitivity or specificity in predicting premalignant and malignant endometrial polyps in women with postmenopausal uterine bleeding and thickened endometrium. On the other hand, polyp size on hysteroscopy is more accurate than sonographic endometrial thickness to rule out premalignancy and malignancy of polyps. In clinical practice, polyp size of approximately 2cm or more has high sensitivity and specificity in diagnosis of premalignant and malignant endometrial polyps. But, even if the hysteroscopic measurement of endometrial polyps seems to have high diagnostic accuracy, it is still necessary to perform histologic evaluation in order to exclude premalignancy and malignancy in endometrial polyps with postmenopausal uterine bleeding and thickened endometrium.

References

- Acmaz G, Aksoy H, Albayrak E, et al (2014). Evaluation of endometrial precancerous lesions in postmenopausal obese women--a high risk group? *Asian Pac J Cancer Prev*, **15**, 195-8.
- American Association of Gynecologic Laparoscopists (2012). AAGL practice report: practice guidelines for the diagnosis and management of endometrial polyps. *J Minim Invasive Gynecol*, **19**, 3-10.
- Balik G, Kagitci M, Ustuner I, Akpinar F, Guvendag Guven ES (2013). Which endometrial pathologies need intraoperative frozen sections? *Asian Pac J Cancer Prev*, **14**, 6121-5.
- Ben-Arie A, Goldchmit C, Laviv Y, et al (2004). The malignant potential of endometrial polyps. *Eur J Obstet Gynecol Reprod Biol*, **115**, 206-10.
- Binesh F, Akhavan A, Behniafard N, Jalilian S (2014). Endometrial adenocarcinoma: clinicopathologic and survival characteristics in Yazd, Iran. *Asian Pac J Cancer Prev*, **15**, 2797-801.
- Costa-Paiva L, Godoy CE Jr, Antunes A Jr, et al (2011). Risk of malignancy in endometrial polyps in premenopausal and postmenopausal women according to clinicopathologic characteristics. *Menopause*, **18**, 1278-82.
- Dreisler E, Stampe Sorensen S, Ibsen PH, Lose G (2009). Prevalence of endometrial polyps and abnormal uterine bleeding in a danish population aged 20-74 years. *Ultrasound Obstet Gynecol*, **33**, 102-8.
- Dreisler E, Sorensen SS, Ibsen PH, Lose G (2009). Value of endometrial thickness measurement for diagnosing focal intrauterine pathology in women without abnormal uterine bleeding. *Ultrasound Obstet Gynecol*, **33**, 344-8.
- Elfayomy AK, Habib FA, Alkabalawy MA (2012). Role of hysteroscopy in the detection of endometrial pathologies in women presenting with postmenopausal bleeding and thickened endometrium. *Arch Gynecol Obstet*, **285**, 839-43.
- Ferrazzi E, Zupi E, Leone FP, et al (2009). How often are endometrial polyps malignant in asymptomatic postmenopausal women? A multicenter study. *Am J Obstet Gynecol*, **200**, 235.
- Gupta JK, Chien PF, Voit D, Clark TJ, Khan KS (2002). Ultrasonographic endometrial thickness for diagnosing endometrial pathology in women with postmenopausal bleeding: a meta-analysis. *Acta Obstet Gynecol Scand*, **81**, 799-816.
- Godoy CE Jr, Antunes A Jr, Morais SS, Pinto-Neto AM, Costa-Paiva L (2013). Accuracy of sonography and hysteroscopy in the diagnosis of premalignant and malignant polyps in postmenopausal women. *Rev Bras Ginecol Obstet*, **35**, 243-8.
- Lasmar BP, Lasmar RB (2013). Endometrial polyp size and polyp hyperplasia. *Int J Gynaecol Obstet*, **123**, 236-9.
- Lee SC, Kaunitz AM, Sanchez-Ramos L, Rhatigan RM (2010). The oncogenic potential of endometrial polyps: a systematic review and meta-analysis. *Obstet Gynecol*, **116**, 1197-205.
- Lieng M, Istre O, Sandvik L, Qvigstad E (2009). Prevalence, 1-year regression rate, and clinical significance of asymptomatic endometrial polyps: cross-sectional study. *J Minim Invasive Gynecol*, **16**, 465-71.
- Lieng M, Istre O, Qvigstad E (2010). Treatment of endometrial polyps: a systematic review. *Acta Obstet Gynecol Scand*, **89**, 992-1002.
- Makris N, Kalmantis K, Skartados N, et al (2007). Three-dimensional hysterosonography versus hysteroscopy for the detection of intracavitary uterine abnormalities. *Int J Gynecol Obstet*, **97**, 6-9.
- Ragni G, Diaferia D, Vegetti W, et al (2005). Effectiveness of sonohysteroscopy in infertile patient work-up: a comparison with transvaginal ultrasonography and hysteroscopy. *Gynecol Obstet Invest*, **59**, 184-8.
- Smith-Bindman R, Weiss E, Feldstein V (2004). How thick is too thick? when endometrial thickness should prompt biopsy in postmenopausal women without vaginal bleeding. *Ultrasound Obstet Gynecol*, **24**, 558-65.
- Schmidt T, Breidenbach M, Nawroth F, et al (2009). Hysteroscopy for asymptomatic postmenopausal women with sonographically thickened endometrium. *Maturitas*, **62**, 176-8.
- Turan T, Karadag B, Karabuk E, et al (2012). Accuracy of frozen sections for intraoperative diagnosis of complex atypical endometrial hyperplasia. *Asian Pac J Cancer Prev*, **13**, 1953-6.
- Uglietti A, Mazzei C, Deminico N, et al (2014). Endometrial polyps detected at ultrasound and rate of malignancy. *Arch Gynecol Obstet*, **289**, 839-43.