

Case Report

Mondor's Disease Developed after Ultrasound-assisted Liposuction for Treatment of Axillary Bromhidrosis

Hee Jong Lee, Eun Key Kim

Department of Plastic Surgery, Asan Medical Center, University of Ulsan College of Medicine, Seoul, Korea

Received March 27, 2014
Revised April 22, 2014
Accepted April 24, 2014

Correspondence to: Eun Key Kim
Department of Plastic Surgery, Asan
Medical Center, 88 Olympic-ro 43-gil,
Songpa-gu, Seoul 138-736, Korea
Tel: +82-2-3010-3600
Fax: +82-2-476-7471
E-mail: nicekek@korea.com

Mondor's disease is an uncommon condition characterized by a palpable, cord-shaped structure, which causes pain when pressed. Its known pathophysiology is thrombophlebitis of the superficial venous system. Although reported repeatedly, its definite cause is unknown and various possible causes have been identified, including surgery, irradiation, infection, malignancy, and trauma. We diagnosed this case to be Mondor's disease of the antecubital venous system, probably due to thermal injury of the proximal tributaries of the basilic or cephalic vein. Risk of thermal injury to the skin flap or the portal site remains a common complication, and as thermal injury to the blood vessel might also be considered, attention must be given when suctioning the area near a large superficial vessel.

Key Words: Phlebitis, Liposuction

Mondor's disease is an uncommon condition with the characteristics of a palpable, cord-shaped structure and which causes pain when pressed. It was first described by Fagge in 1869 and named in 1939.¹ The first reported case of Mondor's disease was found on patient's chest wall which is one of the most common sites along with the abdominal wall. Its known pathophysiology is thrombophlebitis of the superficial venous system. Although reported anecdotally, its definite cause is unknown and various causative conditions have been identified including surgery, irradiation, infection, malignancy, trauma, excessive exercise, pregnancy, rheumatic disease, intravenous catheter, drug abuse, and pills taken orally.^{2,3} Here we present a case of Mondor's disease of the cubital area and which developed after ultrasound-assisted liposuction of the axillary region for the treatment of bromhidrosis.

CASE REPORT

The patient was a 36-year-old female with no significant

past medical history and who underwent ultrasound-assisted liposuction for axillary bromhidrosis. She denied any similar events occurring before her current presentation. She denied any trauma, infection or inflammation on right arm, including the axilla and right cubital fossa. She denied any spontaneous or induced abortions. And her complete blood count, activated partial thromboplastin time, and prothrombin time were normal. She had not an intravenous injection in the antecubital fossa. She had an uncomplicated course after surgery and with no acute complications, such as infection or hematoma. However, she was seen four weeks later and had two, cord-like lesions on the right cubital fossa and which palpated firmly and caused pain when pressed and elbow extended. The lesions were 3 to 5 mm in width, 6 and 8 cm in length, respectively, and were visible when her arm was extended (Fig. 1). Her symptoms improved after six weeks of conservative treatment.

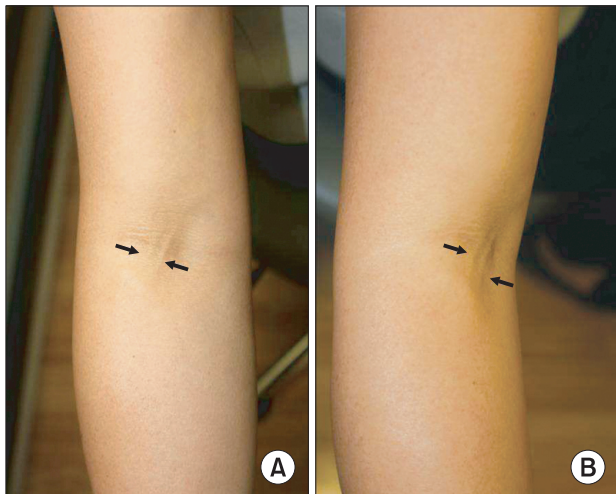


Fig. 1. The patient was a 36-year-old female and who underwent ultrasound-assisted liposuction for axillary bromidrosis. The photo was taken four weeks after operation. Black arrows indicate two cord-like lesions on the right cubital fossa. (A) Anterior-posterior view. (B) Oblique view.

DISCUSSION

The pathophysiology of Mondor's disease explains that it is initiated by minor and temporary acute inflammation causing thrombosis in the affected veins.⁴ Following the fibrosis stage, skin overlying affected veins becomes folded, thus creating lines underneath the skin. Simultaneously sclerosing endophlebitis and periphlebitis occurs in lesions in the vessel intima. This stage leads aggravation of ongoing thrombosis.^{5,6} Skin tension and the typical shape made by underlying lines are caused by adhesion of vessel to adherent skin caused by thrombosis and secondary proliferation of local fibroblasts.⁷ Mondor's disease seen on the chest wall, upper abdominal wall or axillary region is often associated with breast surgery including augmentation or reduction mammoplasties, breast reconstruction or axillary lymph node surgery, usually occurring in the lateral thoracic vein, thoracoepigastric vein, axillary vein or superior epigastric vein. This disease typically develops two to four weeks after surgery and last for two to eight weeks with a self-remitting course.⁸ No systemic therapy is required except for symptomatic treatment such as with anti-inflammatory drugs and local massage and rest of the involved site. There is no need for systemic anticoagulation.⁸ The use of liposuction for treating axillary bromidrosis is relatively recent, although it soon gained

considerable popularity due to its convenience as well as its effectiveness. Ultrasound-assisted liposuction offers the further advantage of reducing the risk of injury to the blood vessels. The reported recurrence rate is low, and with a wide region able to be treated safely without the risk of elevating a skin flap. However, its local heat is harmful to surrounding structures. Hogan⁹ postulated that direct trauma to the vein or pressure on the lateral thoracic veins leading to stasis of blood, may be the pathophysiologic cause of Mondor's disease.

We assessed our patient as having Mondor's disease of the antecubital venous system, probably due to thermal injury of the proximal tributaries of the basilic or cephalic vein. Therefore, the local venous drainage equilibrium may be modified the thermal injury at that level, leading to a consequent thrombotic event. For the prevention of tissue thermal injury, we cool the axilla by water irrigation to the skin surface and limit the ultrasound exposure to not more than 20 minutes per side. Generally, the endpoint (approximately 15 to 17 minutes after beginning ultrasound-assisted liposuction) will be when the skin turns slightly erythematous.

Not taking into account the uncertain pathogenesis of Mondor's disease, which is not yet clarified, the risk of thermal injury to the skin flap or portal site remains one of the most common complications of ultrasound-assisted liposuction and thermal injury to a blood vessel might also be considered and attention must be given when suctioning an area in which a large superficial vessel is near.

REFERENCES

1. Fischl RA, Kahn S, Simon BE. Mondor's disease. An unusual complication of mammoplasty. *Plast Reconstr Surg* 1975;56:319-22.
2. Loos B, Horch RE. Mondor's disease after breast reduction surgery. *Plast Reconstr Surg* 2006;117:129e-32e.
3. Viana GA, Okano FM. Superficial thrombophlebitis (Mondor's Disease) after breast augmentation surgery. *Indian J Plast Surg* 2008;41:219-21.
4. Johnson WC, Wallrich R, Helwig EB. Superficial thrombophlebitis of the chest wall. *JAMA* 1962;180:103-8.
5. Bejanga BI. Mondor's disease: analysis of 30 cases. *J R Coll Surg Edinb* 1992;37:322-4.
6. Mayor M, Burón I, de Mora JC, Lázaro TE, Hernández-Cano N,

- Rubio FA, et al. Mondor's disease. *Int J Dermatol* 2000;39:922-5.
7. Hacker SM. Axillary string phlebitis in pregnancy: a variant of Mondor's disease. *J Am Acad Dermatol* 1994;30:636-8.
 8. Sun SH, Lee TJ. Mondor's disease after immediate breast reconstruction with silicone implant. *J Korean Soc Plast Reconstr Surg* 2010;37:87-90.
 9. Hogan GF. Mondor's disease. *Arch Intern Med* 1964;113:881-5.