

# Kaposi's Varicelliform Eruption in Atopic Dermatitis treated with Korean medicine

Dong-Jin Lee<sup>1</sup>, Kang Kwon<sup>1</sup>, Seung-Ho Sun<sup>2</sup>, Hyung-Sik Seo<sup>1\*</sup>

<sup>1</sup> Department of Ophthalmology, Otolaryngology and Dermatology, Korean Medicine Hospital, Pusan National University, Yangsan, Korea

<sup>2</sup> Department of Internal Medicine, Korean Medicine Hospital, Sangji University, Wonju, Korea

## Key Words

atopic dermatitis, *bee venom* pharmacopuncture, eczema herpeticum, herbal medicine, *hwangyeonhaedoktang* pharmacopuncture, Kaposi's varicelliform eruption

## Abstract

**Objectives:** This case report is to present a complete recovery from Kaposi's varicelliform eruption (KVE) that occurred in a patient with atopic dermatitis by applying Korean Medicine therapies.

**Methods:** *Hwangyeonhaedoktang* pharmacopuncture (HP), 0.3 mL, and 25% *bee venom* pharmacopuncture (BVP), 0.1 mL, were injected, 0.2 mL each, at both BL13 acupoints once a day in the morning. Acupuncture was applied at Sama Upper, Middle and Lower of the Master Tung acupuncture points and at ST44 on the left lateral for 30 minutes twice a day. The affected face was gauze dressed with mixture of 2.0 mL HP and 1.0 mL 25% BVP with 20 mL of normal saline twice a day. Herbal Medicine, *Seungmagalgeuntang*, was administered three times a day after each meal.

**Results:** Rashes and papules on the face were completely cleared after 10 days of treatments.

**Conclusion:** KVE, an acute and urgent dermatitis, can

be effectively treated with Korean medicine.

## 1. Introduction

Kaposi's varicelliform eruption (KVE) is a cutaneous dissemination of viral infection in the setting of an underlying chronic skin condition. Particularly, the infection, which is caused by the herpes simplex virus (HSV), is called "eczema herpeticum". Preceding skin conditions mostly include atopic dermatitis (AD) [1]. The number of reported cases of KVE has increased as the incidence rate of AD is still on the rise. The use of steroids or topical tacrolimus has been reported to be the main risk factor causing KVE in patients with AD [2, 3].

Also, patients are becoming aware that AD is a chronic skin disease that is recalcitrant to conventional Western treatments, and that the prolonged use of steroids may lead to various side effects. Therefore, many patients in Korea are willing to turn to alternative methods of treatment, especially Korean medicine (KM) [4].

Several case reports on the treatment of KVE with oral or intravenous antiviral therapies of Western medicine have been published [1, 5, 6], but no reports on the treatment of KVE with KM therapies, excluding Western medicine, have been published. As we successful

Received: Jan 18, 2014 Accepted: Feb 12, 2014

© This is an Open-Access article distributed under the terms of the Creative Commons Attribution Non-Commercial License (<http://creativecommons.org/licenses/by-nc/3.0/>) which permits unrestricted noncommercial use, distribution, and reproduction in any medium, provided the original work is properly cited.

© This paper meets the requirements of KS X ISO 9706, ISO 9706-1994 and ANSI/NISO Z39.48-1992 (Permanence of Paper).

\*Corresponding Author

Hyung-Sik Seo, Department of Ophthalmology, Otolaryngology and Dermatology, School of Korean Medicine, Pusan National University, Yangsan, Kyungnam 626-770, Korea  
Tel: +82-55-360-5630 Fax: +82-55-360-5689  
E-mail: [aran99@pusan.ac.kr](mailto:aran99@pusan.ac.kr)

## 2. Case report

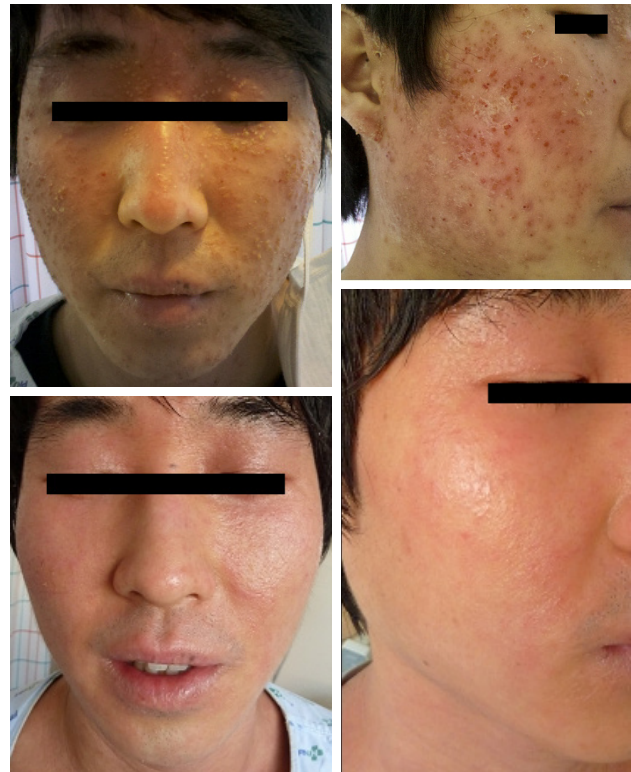
The patient was a 25-year-old male who has suffered with AD from infancy and who had temporarily recovered at the age of fourteen after a long period of continuous conventional treatments. No other medical history was seen except for allergic rhinitis. In August 2011, he had a right malleolus lateralis fracture and was admitted to a local orthopedics clinic. However, during the three weeks of admission, his skin condition was exacerbated after taking analgesic and antibiotic drugs every day. After that, he restarted conventional medication to alleviate the relapsed AD, but to no avail. On the 21<sup>st</sup> of December 2012, he experienced epigastric discomfort with mild fever, chills and fatigue after eating pork-boiled rice soup. The next day, rashes, pustules, vesicles and oozing abruptly appeared on his face and neck. On the 23<sup>rd</sup>, he was diagnosed in our clinic as having KVE and was hospitalized for a week. He did not take any conventional medication during whole process of the disease.

Herbal medicine, *Seungmagalgeuntang* 120 mL per pack, was administered three times a day 30 minutes after each meal. Its ingredients are *Pueraria Lobata* 8 g, *Paeonia Lactiflora* 4 g, *Cimicifuga Foetida* 4 g, *Glycyrrhiza Uralensis* 4 g, *Zingiber Officinale* 4 g, and *Allium Fistulosum* 4 g. *Hwangyeonhaedoktang* pharmacopuncture (HP), 0.3 mL, and 25% *bee venom* pharmacopuncture (BVP), 0.1 mL, were perpendicularly injected at both BL13, 0.2 mL at each site, at depths of 5 mm once a day in the morning. The affected face was dressed with gauze containing a mixture of 2.0 mL of HP and 1.0 mL of 25% BVP with 20 mL of normal saline twice a day.

On the admission day, extensive vesicles and pustules, some of which had ruptured, oozed and crusted, appeared all over the face. The patient complained of a mild headache and a heat sensation on the face, but his vital signs were normal. Particularly, itching increased to the level of 4 on the numerical rating scale (NRS) during that nighttime while none had been seen during the day. The next day, the headache and the heat sensation totally disappeared. On the 4<sup>th</sup> day, most of the vesicles, papules, oozing and crust disappeared, but redness and scales still remained. Nighttime itching decreased to half, NRS 2. On the 7<sup>th</sup> day, facial redness and scales were all cleared. Itching almost disappeared, so he was discharged after a complete recovery (Fig. 1).

## 3. Discussion

Austrian dermatologist Moriz Kaposi gave the first de-



**Figure 1** Pictures comparing the pre and post treatment faces.

scription of KVE as a complication of infant eczema, which is characterized by widespread chickenpox-like vesicles superimposed on an underlying skin condition [7]. In 1941, Seidenberg suggested that the HSV was the primary cause of this disease [8]. The diagnosis of KVE is mainly clinical, but can often be delayed because KVE is easily mistaken for an aggravated skin condition of an existing disease.

KVE is clinically characterized by the sudden appearance of monomorphic, umbilicated, grouped vesiculopustular lesions on the face, particularly around the eyes, neck, axillae, chest and upper extremities. The eruption is usually accompanied by fever and regional lymphadenopathy. Generally, the localized type of KVE heals naturally without permanent scarring; however, the systemic type of KVE can be fatal.

An impaired barrier function of the epidermis and an immunological abnormality have been proposed as causes for the development of the infection [9]. Especially, the suppressed function of T cells causes AD patients to become vulnerable to viruses [10], as increased IL-4 secreting cells in the lesion interrupt the immune reaction to HSV by inhibiting Th-1 cell activity [11]. Furthermore, KVE has been thought to occur due to decreased levels of IL-18, which is known to have profound influences on the pathological conditions of immune diseases [12]. Skin lesions

of AD are often damaged by scratching and can spread to their surroundings because HSV is commonly found even on unaffected regions, such as both hands [13]. However, KVE does not always follow a preceding eczematous skin disease [14], and sometimes refers to an extensive infection of HSV in patients with decreased immunity. Taken altogether, the exact pathogenesis of KVE remains to be elucidated.

Tacrolimus, an immunosuppressant widely used for treating AD, is known to cause disruptions in the topical skin immune system, finally leading to secondary infections [15]. Also, Stroud [16] reported that large amounts of steroids proportionately increased the severity scale of HSV.

Kim *et al.* [17] reported that 66.7% of AD patients were reluctant to use steroids because of their well-known side effects. Chin *et al.* [4] investigated the frequency of undergoing alternative treatments among AD patients and concluded that 84% had experienced alternative medicine and, 73.8% had taken herbal medications. The coexistence of Eastern and Western medicines in Korea is assumed to have provided more opportunity for choosing KM as a primary alternative.

The authors mixed HP and 25% BVP solutions as a main intervention in this case. The antiviral effect of mellitin, a main component of BVP, has been suggested in several research reports [18, 19], to play a key role in inhibiting viral activities, even those of HIV. To relieve the inflammatory responses caused by the virus, we selected HP, which is a typical antiphlogistics in KM. Various articles [20, 21] have reported on its proven anti-inflammatory effects and mechanisms. Selected acupoints, both BL13, are relevant to the lung, which governs the skin system.

The herbal medicine, *Seungmagalgeuntang* is a formula in the classic work – *Bangyakhappyeon* written by Hwang Do-yeon, and was documented as mainly curing warm diseases or seasonal common colds. Smallpox (痘瘡), an infectious viral disease, is also treated based on this formula [22].

Sama Upper, Middle and Lower of Master Tung acupuncture is used to treat skin diseases [23] and ST44 eliminates heat sensation of the face [24].

KVE is an acute, life-threatening, exigent skin disease. This case is significant in that an acute skin infection was completely cured with KM alone. In conventional Western medicine, the localized type of KVE can be cured within 7 to 10 days, on average, if antiviral agents are properly administered [4-6]. That viral disease can be treated with complementary and alternative medicine (CAM) methods in the same amount of time is meaningful, and if CAM is combined with conventional medicine, better control of more severe viral diseases can be expected. However,

this case is only one case of mixed therapies, so more case studies will be needed.

## Acknowledgment

This work was supported by a clinical research grant from Pusan National University Hospital in 2014.

## Conflict of interest

The authors declare that there are no conflicts of interest.

## References

- Hasegawa K, Obermeyer Z, Milne LW. Eczema herpeticum. *J Emerg Med.* 2012;43(5):341-2.
- Lubbe J, Sanchez-Politta S, Tschanz C, Saurat JH. Adults with atopic dermatitis and herpes simplex and topical therapy with tacrolimus: what kind of prevention? *Arch Dermatol.* 2003;139(5):670-1.
- Ambo M. Relapsing Kaposi's varicelliform eruption and herpes simplex following facial tacrolimus treatment for atopic dermatitis. *Acta Derm Venereol.* 2002;82(3):224-5.
- Chin HW, Jang HS, Jang BS, Jo JH, Kim MB, Oh CK, *et al.* [A study on utilization of alternative medicine for patients with atopic dermatitis]. *Korean J Dermatol.* 2005;43(7):903-11. Korean.
- Cavaliere M, Giaccherio D, Cardot-Leccia N, Passeron T, Lacour JP. Kaposi's varicelliform eruption in a patient with pityriasis rubra pilaris (pityriasis rubra pilaris herpeticum). *J Eur Acad Dermatol Venereol.* 2013;27(12):1585-6.
- Dekio I, Chinuki Y, Furumura M, Morita E. Recurrent Kaposi's varicelliform eruption successfully controlled by low-dose oral valaciclovir. *J Dermatol.* 2012;39(2):197-9.
- Barton RL, Brunsting LA. Kaposi's varicelliform eruption: review of the literature and report of two cases of its occurrence in adults. *Arch Dermatol Syphilol.* 1944;50:99.
- Lynch FW, Steves RJ. Kaposi's varicelliform eruption. *Arch Dermatol Syphilol.* 1947;55(3):327-36.
- Goodyear HM, Davies JA, Mcleish P, Buchan A, Skinner GRB, Winther M, *et al.* Growth of herpes simplex type 1 on skin explants of atopic eczema. *Clin Exp Dermatol.* 1996;21(3):185-9.
- Rystedt I, Strannegard IL, Strannegard O. Recurrent viral infections in patients with past or present atopic

- dermatitis. *Br J Dermatol*. 1986;114(5):575-82.
11. Raychaudhuri SP, Raychaudhuri SK. Revisit to Kaposi's varicelliform eruption: role of IL-4. *Int J Dermatol*. 1995;34(12):854-6.
  12. Nakanishi K, Yoshimoto T, Tsutsui H, Okamura H. Interleukin-18 regulates both Th1 and Th2 response. *Annu Rev Immunol*. 2001;19:423-74.
  13. Amatsu A, Yoshida M. Detection of herpes simplex virus DNA in non-herpetic areas of patients with eczema herpeticum. *Dermatology*. 2000;200(2):104-7.
  14. Sterling JC. Virus infection. In: Burns T, Breathnach S, Cox N, Griffiths C. *Rook's textbook of dermatology*. 7th ed. Massachusetts: Blackwell; 2004. p. 2535-8.
  15. Osawa K, Etoh T, Ariyoshi N, Ishii I, Ohtani M, Kariya S, *et al*. Relationship between Kaposi's varicelliform eruption in Japanese patients with atopic dermatitis treated with tacrolimus ointment and genetic polymorphisms in the IL-18 gene promoter region. *J Dermatol*. 2007;34(8):531-6.
  16. Stroud GM. Recurrent herpes simplex and steroid dosage - In a patient with the nephrotic syndrome due to primary systemic amyloidosis. *Arch Dermatol*. 1961;84(3):396-401.
  17. Kim HB, Cho YJ, Yoo KH, Kim DY, Kim JH, Kim HJ, *et al*. [Survey on the management of atopic dermatitis]. *Kor J Asthma Allergy Clin Immunol*. 2012;32(1):16-20. Korean.
  18. Falco A, Barrajón-Catalán E, Menéndez-Gutiérrez MP, Coll J, Micol V, Estepa A. Melittin-loaded immunoliposomes against viral surface proteins, a new approach to antiviral therapy. *Antiviral Res*. 2013;97(2):218-21.
  19. Hood JL, Jallouk AP, Campbell N, Ratner L, Wickline SA. Cytolytic nanoparticles attenuate HIV-1 infectivity. *Antivir Ther*. 2013;18(1):95-103.
  20. Li L, Zeng H, Shan L, Yuan X, Li Y, Liu R, *et al*. The different inhibitory effects of Huang-Lian-Jie-Du-Tang on cyclooxygenase 2 and 5-lipoxygenase. *J Ethnopharmacol*. 2012;143(2):732-9.
  21. Zeng H, Liu X, Dou S, Xu W, Li N, Liu X, *et al*. Huang-Lian-Jie-Du-Tang exerts anti-inflammatory effects in rats through inhibition of nitric oxide production and eicosanoid biosynthesis via the lipoxygenase pathway. *J Pharm Pharmacol*. 2009;61(12):1699-707.
  22. Hwang DY. [Bangyakhappyeon]. Seoul: Younglimsa; 2007. p. 195-6. Korean.
  23. Choi MH. [Master Tung's acupuncture & moxibustion]. 2nd ed. Seoul: Iljungsa; 2005. Chapter 08, Eight-eight region; p.134-5. Korean.
  24. Textbook committee of the Korean acupuncture & moxibustion society. [Acupuncture & moxibustion (vol. 2)]. 2nd ed. Gyunggi: Jipmoondang; 2008. Chapter 01, Head & Face; p. 5. Korean.