

Tuberculous Tenosynovitis of the Elbow - A Case Report

Chi-Hun Oh, Jung-Ho Park, Jung-Wook Kim

Department of Orthopedic Surgery, Korea University Ansan Hospital, Korea University College of Medicine, Ansan, Korea

A 29-year-old man visited our clinic owing to a persistent swelling in the anterior part of the left elbow joint that began one year ago. Through magnetic resonance imaging (MRI), we observed tenosynovitis with multiple rice bodies, and so we performed an excisional biopsy and tenosynovectomy. Through pathology and culture tests, we identified tuberculosis in the tissue biopsy that we harvested intraoperatively. Following the anti-tuberculosis medication relieved the patient's symptoms without recurrence. Since tuberculosis of the elbow occurs only rarely, and the symptoms mimic those of rheumatoid synovitis or of non-specific chronic synovitis, early diagnosis and appropriate treatment are often delayed. The authors report this rare case of tuberculous tenosynovitis of the elbow with a review of the relevant literature.

(Clin Shoulder Elb 2014;17(2):80-83)

Key Words: Elbow; Tuberculous tenosynovitis; Tenosynovectomy; Anti-tuberculosis medication

Recently, the improvements in the level of nutrition and hygiene, as well as the developments in anti-tuberculosis drugs have led to the decline of tuberculous arthritis and tenosynovitis. Musculoskeletal tuberculosis comprises less than 5% of all tuberculosis cases, and are often restricted to the spine and weight bearing joints.¹⁾ Those that occur in the elbow joint comprises 2–5% of all osseous tuberculous cases.²⁾ Osseous tuberculous is reported often, but tuberculosis tenosynovitis is extremely rare. Thus in this paper, the authors report the observation of a 29-year-old man with tuberculosis tenosynovitis in the left elbow joint with a review of the relevant literature.

Case Report

A 29-year-old man visited our clinic owing to discomfort from swelling in the anterior part of the left elbow joint that began one year ago. The patient did not have a history of external trauma, but reported that the swelling occurred after a blood donation one year ago, and that he received acupuncture in the said area on numerous occasions thereafter. At the time of visit, a physical examination of the patient showed no clinical symptoms, such as fever or weight loss, apart from the localized swell-

ing in the anterior part of the left elbow joint. Both active and passive range of movement of the elbow was normal, apart from the presence slight discomfort. Bone tenderness, temperature changes, or Tinel's sign were not observed.

The basic radiologic test was normal apart from the swelling in soft tissue of the anterior part of the elbow. The magnetic resonance imaging (MRI) showed a mass of exudate surrounding the forearm biceps tendon with marked extension to the distal part of the radial tuberosity. Furthermore, proton density weighted images and fat suppressed T2-weighted images showed multiple low signal rice bodies (Fig. 1) within the mass lesion. Whilst, the basic radiologic test of the chest and respiratory function test were normal, the sputum cytology and culture tests were both negative. Blood tests were normal.

Tenosynovectomy was carried out in the anterior part of the elbow joint under the assumption that a tuberculous tenosynovitis in the bicep tendon was present. During the operation, it was observed that the tendon sheath in the distal part of the biceps tendon had thickened, and a cyst of synovial lining tissue had formed around the biceps anchor. During the operation, many rice bodies were observed when the synovial lining cyst of the granulation tissue was opened (Fig. 2). A wide-range tenosyno-

Received August 16, 2013. **Revised** April 8, 2014. **Accepted** April 9, 2014.

Correspondence to: Jung-Ho Park

Department of Orthopedic Surgery, Korea University Ansan Hospital, 123 Jeokgeum-ro, Danwon-gu, Ansan 425-707, Korea

Tel: +82-31-412-5040 -, **Fax:** +82-31-439-3852, **E-mail:** canall@korea.ac.kr

Financial support: None. **Conflict of interests:** None.

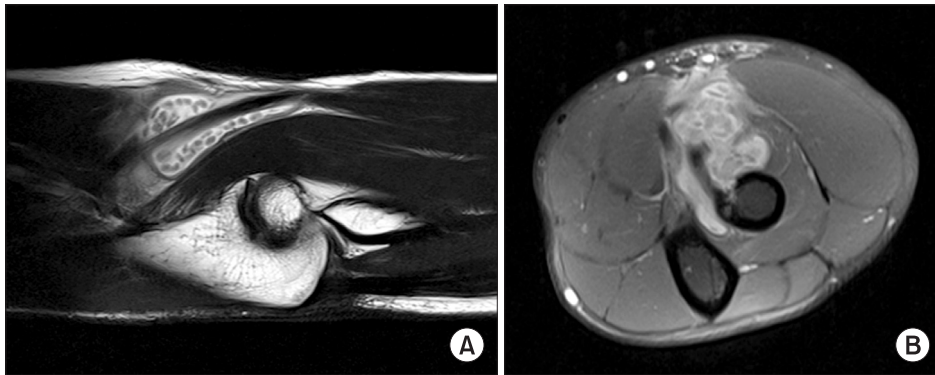


Fig. 1. (A) The proton density-weighted sagittal image shows a mass surrounding the biceps tendon that extends to the distal part of the radial tuberosity. (B) The T2-weighted axial image shows multiple low signal rice bodies within the mass lesion.

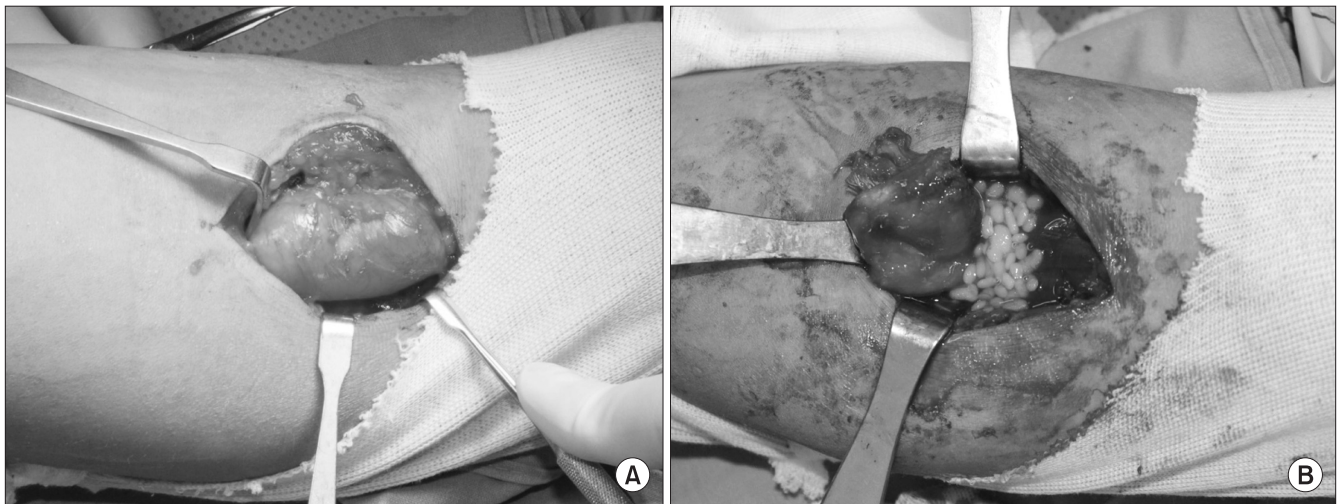


Fig. 2. In operation, many rice bodies were observed in the synovial lining cyst of the granulation tissue.

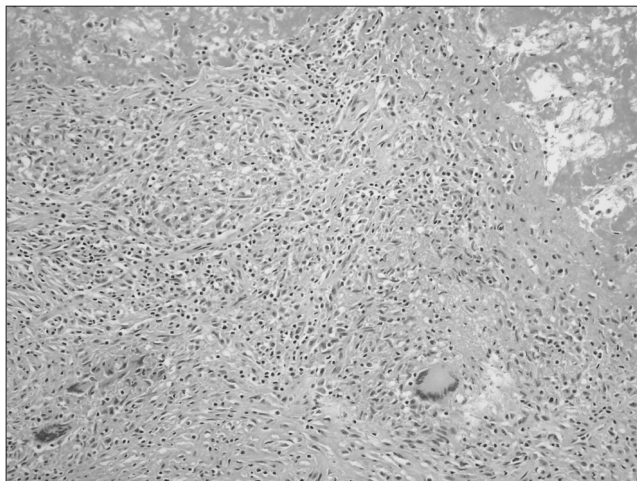

Fig. 3. A Langerhans cell is surrounded by lymphocytes and epithelioid cells in hematoxylin-eosin staining. Chronic caseating granulomatous inflammation is also seen ($\times 200$).

vectomy and debridement was carried out, during which tissue biopsy was obtained for pathological and microbiological tests. In the pathological test, staining of the tendon sheath and the

multiple rice bodies with hematoxylin-eosin showed localized caseation necrosis and chronic caseating granulomatous inflammation (Fig. 3). Real-time polymerase chain reaction (PCR) and Periodic Acid Schiff staining of the *Mycobacterium tuberculosis*-infected tissue showed a negative result, but Acid-fast staining showed a positive result. Immediately, the patient was started on anti-tuberculosis medication composed of 2 months of quadruple therapy (isoniazid, rifampin, Ethambutol, pyrazinamide), followed by 7 months of triple therapy that excludes pyrazinamide. After surgery, the incision area from the operation healed normally, and at two weeks, the suture stitch was removed after which early joint exercise was started. Follow-up via outpatient visits are being carried out at each following month after surgery. Even at 10 months after surgery, there was no recurrence or degeneration of condition. At the final follow-up, the elbow and wrist joint functions were normal, indicated by a normal range of motion and muscle strength.

Discussion

Tuberculous tenosynovitis is a relatively rare disease. At the

early stages it occurs progressively without clear symptoms, during which swelling and inflammatory changes in the tendon sheath forms gradually, followed by symptoms such as pain and restriction in joint movement. Due to such characteristics of the disease, early diagnosis followed by the appropriate treatment is critical.³⁾

In the Republic of Korea, osetoarticular tuberculosis in the elbow joint and tuberculous tenosynovitis in the flexor tendon of the wrist joint have been reported,^{4,5)} but tuberculous tenosynovitis in the elbow joint is yet to be reported. One exception is in foreign literature where Asaka et al.⁶⁾ have reported one case of tuberculous tenosynovitis in the elbow.

The area of the body most susceptible to tuberculous tenosynovitis is the wrist joint, in which the flexor tendon is twice as more susceptible than the extensor tendon.⁷⁾ The clinical symptom is the gradual development of a swelling that is most commonly painless but can sometimes be painful and restrict joint movement. Though uncommon, numbness and muscle weakness have also been noted. On the other hand, infection of the respiratory system and other musculoskeletal infections are rare co-morbidities, as are whole-body fevers and weight loss.⁷⁾ Furthermore, the symptoms are also similar to symptoms of rheumatoid arthritis and non-specific chronic tenosynovitis. Therefore, delay of diagnosis is common as is the start of appropriate treatment.³⁾

The diagnosis of tuberculous tenosynovitis is carried out via the positive culture test of the bacteria. The rate of diagnosis from a culture test varies depending on the form of clinical specimen used. Testing on joint fluid gives a diagnosis rate of less than 50%, whilst a biopsy sample of the tendon sheath obtained from surgery gives a rate greater than 90%.⁸⁾ A biopsy sample is also helpful in that a further pathology test may be carried out to differentiate conventional granulomas or the presence of acid fast bacilli via Acid-fast staining. However, bacterial culture tests take at least 6 weeks during which the diagnostic rate of Acid-fast staining falls and cannot differentiate well from atypical mycobacterial infections. Therefore, a clinical diagnosis of tuberculosis is crucial. Bush and Schneider³⁾ suggest two clinical situations in which tuberculous tenosynovitis should be strongly suspected. First, through a physical examination, is the presence of a progressive, painless tenosynovitis with either an abnormal basic radiologic screening of the chest or a history of mycobacterium tuberculosis infection or exposure. Second, through a surgical examination, is whether the tenosynovitis has a relatively widespread area and a severe adherence, and in particular when multiple rice bodies are also present. Furthermore, MRI are recommended through which the presence of multiple rice bodies can be confirmed. If such clinical observations are observed together, tuberculosis must be strongly suspected and anti-tuberculosis medication must be started on as soon as possible.

The most effective treatment of tuberculous tenosynovitis is when thorough tenosynovectomy and anti-tuberculosis chemotherapy is carried out in parallel.³⁾ *Mycobacterium tuberculosis* infected tissue undergoes necrosis, which has a negative impact on blood flow. Therefore, the injection of anti-tuberculosis drug alone is insufficient for complete recovery, and surgical treatment alone also has high rates of recurrence. Boyes⁹⁾ reported a recovery rate of 70% when surgery is carried out alone, whilst a 15% recurrence rate is seen when chemotherapy is carried out in parallel. However, these recurrences were recovered with conservative treatment. The injection of anti-tuberculosis drugs are recommended for at least 9 months, which generally comprises of, 2 months of quadruple therapy (isoniazid, rifampin, Ethambutol, pyrazinamide) followed by at least 4 months of triple therapy that excludes pyrazinamide.

In musculoskeletal infections, the infection spreads from other tuberculosis-infected organs, such as the lungs and the lymph nodes, from which the mycobacterium tuberculosis travels through blood to invade the subchondral bone or the tubular bone. In some cases, infection occurs by the invasion of the synovial sheaths or via direct inoculation.¹⁰⁾ In our study, we suspect that infection may have occurred via needles used in acupuncture, which the patient received after the occurrence of a swelling that formed since donating blood one year ago. However, in order to elucidate a causal relationship further epidemiological investigation is required.

The frequency of tuberculosis tenosynovitis is very low, but it could be the cause of a painless swelling in elbow joints of certain patients. Further, if history of an intralesional injection is present or the patient does not respond to appropriate treatment, the possibility of tuberculosis tenosynovitis must be considered during diagnosis.

References

1. Alvarez S, McCabe WR. Extrapulmonary tuberculosis revisited: a review of experience at Boston City and other hospitals. *Medicine (Baltimore)*. 1984;63(1):25-55.
2. Dhillon MS, Goel A, Prabhakar S, Aggarwal S, Bachhal V. Tuberculosis of the elbow: A clinicoradiological analysis. *Indian J Orthop*. 2012;46(2):200-5.
3. Bush DC, Schneider LH. Tuberculosis of the hand and wrist. *J Hand Surg Am*. 1984;9(3):391-8.
4. Moon MS, Bae TY, Kim JB, Chon JG. Cystic tuberculosis in olecranon, mimicking the bone tumor: A case report. *J Korean Shoulder Elbow Soc*. 2008;11(2):193-5.
5. Jung JM, Kim JO, Yun YH, et al. Tenosynovectomy for chronic flexor tenosynovitis at the wrist. *J Korean Soc Surg Hand*. 2004;9(2):83-8.
6. Asaka T, Takizawa Y, Kariya T, et al. Tuberculous tenosynovitis in the elbow joint. *Intern Med*. 1996;35(2):162-5.

7. Lee KE. Tuberculosis presenting as carpal tunnel syndrome. *J Hand Surg Am.* 1985;10(2):242-5.
8. Andersson MI, Willcox PA. Tuberculous tenosynovitis and carpal tunnel syndrome as a presentation of HIV disease. *J Infect.* 1999;39(3):240-1.
9. Boyes JH. *Bunnell's surgery of the hand.* 5th ed. Philadelphia: J. B. Lippincott Co; 1970. 632.
10. Watts HG, Lifeso RM. Tuberculosis of bones and joints. *J Bone Joint Surg Am.* 1996;78(2):288-98.