

RESEARCH ARTICLE

Lobaplatin Combined Floxuridine/Pirarubicin-based Transcatheter Hepatic Arterial Chemoembolization for Unresectable Primary Hepatocellular Carcinoma

Chang Zhao¹, Xu-Jie Wang^{2*}, Song Wang^{2*}, Wei-Hua Feng², Lei Shi², Chun-Peng Yu²

Abstract

Purpose: To assess the effect and safety of lobaplatin combined floxuridine /pirarubicin in transcatheter hepatic arterial chemoembolization(TACE) of unresectable primary liver cancer. **Patients and Methods:** TACE combined with the chemotherapy regimen was used to treat 34 unresectable primary liver cancer patients. DSA/MRI/CT/blood routine examinations were used to evaluate short term activity and toxicity after 4-5 weeks, the process being repeated if necessary. **Results:** Among the 34 cases, 1 (2.9%) showed a complete response, 21 (61.7%) a partial response, 8 (23.5%) stable disease, and 4 progressive disease, with a total effective rate of 67.6%. The content of alpha fetoprotein dropped by over 50% in 20 cases (58.8%). The rate of recovery was hepatalgia (88.2%), ascites (47.1%), appetite (55.9%), Performance Status(30.4%). The median follow-up time (MFT) was 281 days (63-558 days), and median progression-free survival was 118.5 days (95%, CI:88.8-148.2days). Adverse reactions (III-IV grade) were not common, with only 4 cases of vomiting and 2 cases of thrombocytopenia (III grade). **Conclusions:** Lobaplatin-based TACE is an effective and safe treatment for primary liver cancer.

Keywords: Primary hepatic carcinoma - chemoembolization - platinum chemotherapy - clinical response

Asian Pac J Cancer Prev, 15 (5), 2057-2060

Introduction

Hepatocellular carcinoma (HCC) is a common malignant tumor. The majority of patients have reached the advanced or distant metastasis when diagnosed, and have lost the opportunities of surgical operation. Transcatheter arterial chemoembolization (TACE) is an important nonsurgical treatment (Llovet et al., 2002). TACE combined with platinum chemotherapy has been widely used in clinical and achieved good curative effects (Wang et al., 2013). Because of its unique mechanism of action, good stability, wide antitumor spectrum, strong anti-tumor activity, low liver toxicity and without cross resistance, Lobaplatin (LBP, an third generation platinum anticancer drugs) has got better curative effects on gastrointestinal tumors. Only a few published articles have addressed the use of LBP-based TACE in the treatment of unresectable HCC, This article aims to observe the feasibility and safety of LBP-based TACE in the treatment of unresectable HCC.

Materials and Methods

Patient Population

Between January 2012 to June 2013, 34 patients with HCC were enrolled to be treated with one or more cycles of

LBP-based TACE, male 29 cases, female 5 cases, average age for 57.2±10.7 years, 12 cases were biopsy-proven, 22 cases were in line with the China Cancer Association liver cancer Professional Committee amendment liver cancer clinical diagnosis standard (Yang, 2001), Patients were considered for TACE who were deemed to be unresectable but had white cell >4.0x10⁹/l, platelet count >80x10⁹/l, liver cirrhosis child-pugh A Level or B Level with 7 scores, the preoperative informed consent form. Patients were not enrolled who had a large number of ascites, portal vein embolization, liver metastasis, or less than 3 months expected survival time. More information of patients included HBsAg - positive in 25 cases, HCVAg positive in 2 cases, hepatitis cirrhosis in 29 cases, drug cirrhosis in 2 cases, unknown origin cirrhosis 1 cases. Patients baseline characteristics are shown in Table 1.

Methods

Seldinger technique was used in TACE. After the introduction of a 5 French sheath into the femoral artery, the angiograms were performed in the hepatic artery, superior mesenteric artery, and inferior phrenic artery (when necessary) with the 4F catheter. Depending on the quantity, size, location, and feeding arterials of tumors, the Microcatheter was advanced further into the segmental arteries, high concentration of chemotherapeutic drugs

¹Department of Interventional Therapy, Affiliated Tumor Hospital of Guangxi Medical University, Nanning, ²The Affiliated Hospital of Qingdao University, Qingdao, China *For correspondence: 1506425915@126.com, derekqyf@126.com

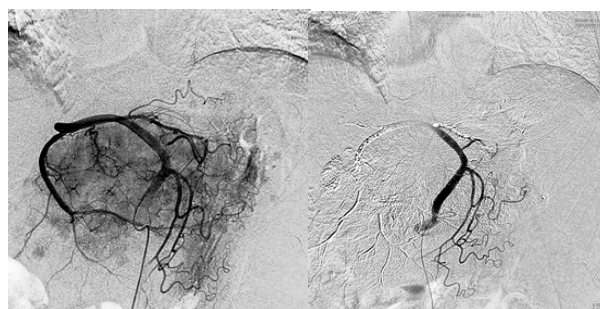
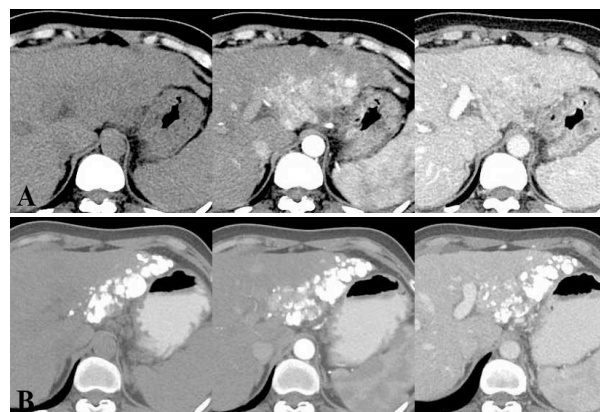
Table 1. Summary of Baseline Patient Characteristics

Characteristics	Value	Percentage (%)
Sex		
Male	29	85.2
Female	5	17.3
Mean age(y) \pm SD	57.2 \pm 10.7	
Liver Cirrhosis type		
Posthepatic cirrhosis	29	90.6
Grug Cirrhosis	2	6.3
Unknown Causes Cirrhosis	1	3.1
Child-Pugh classification		
A	29	85.3
B	5	14.7
AFP (ng/ml)		
\geq 400	15	44.1
<400	19	55.9
Tumor number		
Single	14	41.2
Multiple	20	58.9
Tumor Max diameter (cm) \pm SD	8.9 \pm 4.2	
Ascites	18	52.9
ECOG classification		
0	11	32.4
1	23	67.6
The portal vein tumor thrombus	3	8.8

were infused selectively through the microcatheter, included 30 - 50mg lobaplatin for injection (Hainan Changan International Pharmaceutical Co., Ltd., 10 mg), 0.5 g-1.0 g of floxuridine (Zhejiang Hisun pharmaceutical Limited by Share Ltd, 0.25 g) saline solution, and the mixture of 20-40mg pirarubicin hydrochloride for injection (Zhejiang Hisun pharmaceutical Limited by Share Ltd, 10 mg) and 5-15ml imported lipiodol, PVA particles (100-500 μ m) were selectively used for rich vascular hepatic tumors and arteriovenous fistula in embolization. Devascularization was confirmed with additional angiography of the hepatic artery. After TACE, Antiemetic, hepatoprotection, and antacid drugs were used routinely. Pain, nausea, vomiting, fever, sensory and other adverse reactions were recorded, Liver function test, blood routine, AFP test and imaging studies (DSA angiography, CT, MRI) were performed in the 4-6 weeks after treatment. According to the examination results, the treatment was repeated with the same modality. The follow-up of living conditions was recorded for all patients.

Definitions and Data Analysis

Recent efficiency evaluation: Tumor response was retrospectively evaluated by Response Evaluation Criteria In Solid Tumors (RECIST) (Wang et al., 2013), classified into four grades: complete response (CR), indicating disappearance of any intratumoral enhancement in all target lesions; partial response (PR), indicating decrease of less than 30% in the sum of the greatest dimension of viable (ie, enhancing) target lesions; stable disease (SD), indicating not enough shrinkage or increase to qualify as a partial response or as progressive disease; and progressive disease (PD), indicating an increase of more than 20% in the sum of the greatest dimension of viable (ie, enhancing) target lesions After the initial CT scan, subsequent follow-up contrast-enhanced CT scans were repeated every 2-3 months. Objective response rate (ORR)= CR+PR.

**Figure 1. The DSA Images of TACE****Figure 2. The Comparison of CT Images Before Treatment and after Treatment 1 Month**

Toxicity evaluation: According to WHO anticancer drugs in acute and subacute toxicity grading standards, Toxicities were classified into four grades (0-IV).

Recording Progression-Free-Survival (PFS): PFS was recorded from the day after first TACE to June 2013, Statistical analysis was conducted with SPSS 17.0 software.

Clinical symptoms evaluation: Clinical symptoms evaluation included the abatement of hepatalgia (According to WHO pain classification standards, classified into 0-III grade, the postoperative pain degrade more than one level was recorded), ascites disappearance (disappearance was recorded), appetite (intake increasing more than 100g was recorded) and Performance status improvement (According to ECOG classification standards, the postoperative Physical situation degrade more than one point was recorded).

Results

Efficiency evaluation

34 cases were successfully treated with at least one time TACE treatment, and totally 78 times treatments were successfully completed (2.3 times per person on average). The angiography was performed for 34 patients. The demonstrated abnormal dense stain in the tumors suggested rich blood supply. 17 cases showed extrahepatic blood supply for hepatic tumor, mainly from the branch of phrenic artery, superior mesenteric artery and intercostals artery. 3 cases showed hepatic artery - portal vein fistula stain. 3 cases showed the stain of a small amount of tumor thrombus in portal vein. The curative effect was evaluated in the 4-6 weeks after treatment, Among the 34 cases, 1 case (2.9%) showed a complete response, 21

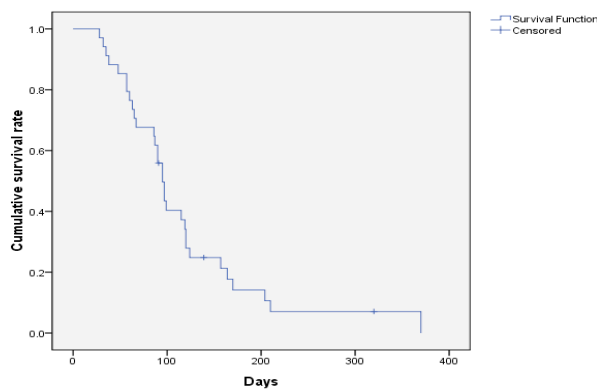


Figure 3. Progression-Free-Survival

cases (61.7%) showed a partial response, 8 cases (23.5%) showed stable disease, and 4 cases showed progressive disease who were advised to take sorafenib. The objective response rate was 67.6%. The content of AFP dropped by over 50% in 20 cases (58.8%). After 2 times treatments, 2 cases showed more than 70% decrease in target lesions in contrast-enhanced CT scans, who were advised to get surgical resection, and there were no recurrence in 1 year follow-up. The rate of recovery was separately hepatalgia (88.2%), ascites (47.1%), appetite (55.9%), Performance Status (30.4%) in 4-6 weeks after treatment. The median follow-up time (MFT) was 281 days (63-558 day, The PFS was 118.5 days), 95%, CI: 88.8-148.2 days) (Figure 1-3).

Toxicity

After the treatments, 34 cases showed different degree of toxicity (mainly I-II level), no IV grade toxicity. The III grade toxicity included: gastrointestinal reaction (nausea, ventosity) in 4 cases (11.8%), bone marrow toxicity (thrombocytopenia) in 2 cases (5.9%), no nervus and renal toxicity was recorded. 1 case showed Mallory-Weiss syndrome which was caused by vomiting after TACE, and the drugs of hemostasis, gastric acid inhibition and antiemetic have been used and got good effectiveness. 18 cases showed different degree of thrombocytopenia, of which 1 case with hemorrhage symptoms and low platelet ($36 \times 10^9/l$) was treated with 2 units of platelets and elevating platelet drugs (Compound Zaofan Pills and Shengxuebao mixture), others cases were only treated with Compound Zaofan Pills and Shengxuebao mixture, which had good recovery in 2 weeks after treatments.

Discussion

TACE, due to its Minimal invasive and good outcome, had become one of the important palliative treatments for the patients with advanced HCC (Si et al., 2013; Wang SY, et al., 2013; Cui L, et al., 2012; Kong WD, et al., 2012). With the development of the high efficiency and low toxicity antitumor drugs, More kinds of chemotherapy regimens include LBP (a third generation platinum) were used with TACE and got the better effect.

Lobaplatin (D-19466; 1, 2-diammino-methyl-cyclobutaneplatinum (II)-lactate) effects on the formation of DNA-drug adducts, mainly as GG and AG intra-strand cross-links, which could influence the proliferation of

DNA. LBP arrests cell cycle progression in G1 and G2/M phases time-dependently which might be associated with the down-regulation of cyclin B, CDK1, CDC25C, phosphorylated CDK1 (pCDK1), pCDK4, Rb, E2F, and pRb, and the up-regulation of p53, p21, and p27. In this way, LBP has shown good antitumour activity. In vivo, LBP remains good stability and low toxicity, some tumors resistant to cisplatin are still sensitive to LBP. LBP has activity in a wider range of tumour types (McKeage, 2001; Wu, et al., 2010; Deng et al., 2013; Huang et al., 2013). LBP has been approved good inhibitory effect for the hepatocellular carcinoma cell lines (SMMC-27721, HepG2 and Bel2-7402) in the experiments in vitro (Qian et al., 2009). Compared with Oxaliplatin and carboplatin, LBP can be completely dissolved in the 4.5ml omnipaque +0.5ml water, and has better solubility (12mg/ml). The mixture particle of lipiodol, water and LBP is made and used more easily in TACE through the catheter, and also makes drugs effective deposition in the lesion. The results of these studies proved the basic theory for that LBP-based TACE might be more useful for advanced HCC patients. In 2009, Shi Ming (Shi et al., 2009) et al reported the clinical comparative study about TACE combined with the regimen of LBP, epirubicin, mitomycin and the regimen of only epirubicin in the treatment of HCC patients, Median Survival Time (MST) was recorded. The MST of former group (15.9months) was longer than the latter group (5 months). In 2010, Bin Zhou (Bin Zhou, et al. 2010) et al experimented with Chemoembolization with Lobaplatin Mixed with Iodized Oil for 28 cases in unresectable recurrent hepatocellular carcinoma after liver transplantation, which had higher efficiency and longer survival than the group without treatment. In 2012, Zhang Peng (Zhang et al., 2013) et al did a further study about the treatment with LBP for unresectable HCC patients, The thermochemotherapy and embolization via hepatic artery was used in the treatment for 20 cases of unresectable HCC patients. They finally got the result of a total effective rate of 55.0% and thought the use of thermochemotherapy and embolization via hepatic artery an effective and safe treatment for HCC. In our study, we firstly used the lobaplatin-based TACE in the treatment for unresectable HCC patients, and received the 67.6% of the total efficiency and 118.5 days median progression free survival time, postoperative AFP declined significantly, hepatalgia, ascites, appetite and other clinical symptoms improved significantly, the adverse reactions were minor and well tolerated, the quality of life of patients was significantly improved after treatments. Compared with the other studies, the information of this result is more detailed and exact, and the short-term efficacy seems better.

The adverse reactions of LBP were mostly reported in the intravenous clinical application, the most common adverse reaction was the Dose-limiting toxicity of thrombocytopenia. The adverse reactions of digestive system (including nausea, vomiting and bloating) were milder than cisplatin, and also there were no significant renal toxicity and neurotoxicity. These results have been confirmed in the phase I, II phase clinical study and other clinical studies. In the phase II clinical study performed by

Jiang Wenqi et al about LBP monotherapy in the treatment of breast cancer (Jiang et al., 1998), 42 cases of recurrent or metastatic breast cancer patients were enrolled. The total efficiency was 45.2%, the thrombocytopenia (II-IV grade) was 14.5%, the kidney toxicity and neurotoxicity was low. In present study, the adverse reactions were similar to that reported in the literatures, mainly including the gastrointestinal toxicity and thrombocytopenia, the rate of III grade was only 11.8%, 5.9% respectively, due to local perfusion application. Even though the thrombocytopenia was only in a few patients after the treatment, the low platelet count patients should be more cautious in using LBP. The patients who show I-II grade thrombocytopenia in this group were only treated with the drug therapy (Compound Zaofan Pills and Shengxuebao mixture). The patients with III-IV grade thrombocytopenia without bleeding complications were treated with recombinant human interleukin-11 (subcutaneous injection of Juheli). The patients with Platelet count $<20 \times 10^9/L$ or count $<50 \times 10^9/L$ with spontaneous hemorrhage should be monitored closely and treated timely with platelet transfusion, which usually could effectively controlle and cured those adverse reactions mentioned above. The kidney toxicity and neurotoxicity was not recorded in this study.

In conclusion, TACE with the lobaplatin-based Chemotherapy Regimen for HCC seems to have the better short-term efficacy and the lower toxicity. It is an effective and safe treatment for the unresectable HCC, which is worthy to be extended to clinical application. Because of the small number of cases enrolled in the group and the short follow-up time, the further effect still need further clinical studies.

References

- Cui L, Liu XX, Jiang Y, et al (2012). Comparative study on transcatheter arterial chemoembolization, portal vein embolization and high intensity focused ultrasound sequential therapy for patients. *Asian Pac J Cancer Prev*, **13**, 6257-61.
- Deng QQ, Huang XE, Ye LH, et al (2013). Phase II trial of Loubo (R) (Lobaplatin) and pemetrexed for patients with metastatic breast cancer not responding to anthracycline or taxanes. *Asian Pac J Cancer Prev*, **14**, 413-7.
- Huang XE, Wei GL, Huo JG, et al (2013). Intrapleural or intraperitoneal lobaplatin for treatment of patients with malignant pleural effusion or ascites. *Asian Pac J Cancer Prev*, **14**, 2611-4.
- Jiang WQ, Lin TY, Xu RH, et al (1998). A Phase II Clinical Trial of Lobaplatin as a Single Agent in the Treatment of Breast Cancer. *Pract J Cancer*, **13**, 294-295.
- Kong WD, Cao JM, Xu J, et al (2012). Impact of low versus conventional doses of chemotherapy during transcatheter arterial chemo-embolization on serum fibrosis indicators and survival of liver cancer patients. *Asian Pac J Cancer Prev*, **13**, 4757-61.
- Llovet JM, Real MI, Montaña X, et al (2002). Arterial embolisation or chemoembolisation versus symptomatic treatment in patients with unresectable hepatocellular carcinoma: a randomised controlled. *Lancet*, **359**, 1734-9.
- McKeage MJ (2001). Lobaplatin: a new antitumour platinum drug. *Expert Opin Investig Drugs*, **10**, 119-28.
- Therasse P, Arbuck SG, Eisenhauer EA, et al (2000). New Guidelines to Evaluate the Response to Treatment in Solid Tumors. *J Natl Cancer Inst*, **92**, 205-16.
- Si Y, Hu X, Du H, et al (2013). Transarterial chemoembolization for patients with unresectable hepatocellular carcinoma: A retrospective study of a 5-year experience in a single institution. *Hepatogastroenterology*, **60**, 1405-8.
- Wang SY, Zhu WH, Vargulick S, et al (2013). Nausea and vomiting after transcatheter arterial chemoembolization for hepatocellular carcinoma: incidence and risk factor analysis. *Asian Pac J Cancer Prev*, **14**, 5995-6000.
- Wang Y, Shen Y (2013). Unresectable hepatocellular carcinoma treated with transarterial chemoembolization: clinical data from a single teaching hospital. *Int J Clin Exp Med*, **6**, 367-71.
- Wu Q, Qin SK, Teng FM, et al (2010). Lobaplatin arrests cell cycle progression in human hepatocellular cells. *J Hematol Oncol*, **3**, 43.
- Zhou B, Shan H, Zhu KS, et al (2010). Chemoembolization with Lobaplatin Mixed with Iodized Oil for Unresectable Recurrent Hepatocellular Carcinoma after Orthotopic Liver Transplantation. *Vasc Interv Radiol*, **21**, 333-8.