

RESEARCH ARTICLE

Lack of Relation of AKAP12 with p53 and Bcl-2 in Colorectal Carcinoma

Dinc Suren¹, Mustafa Yildirim², Arsenal Sezgin Alikanoglu¹, Vildan Kaya^{3*}, Mustafa Yildiz⁴, Utku Donem Dilli⁴, Cem Sezer¹

Abstract

Background: AKAP12 inhibits oncogenic proliferation, invasion, chemotaxis and neovascularization. Bcl-2 and p53 are two important apoptotic markers that play roles in apoptotic processes. It has been found that AKAP12 blocks the cell cycle and induces apoptosis in fibrosarcoma cells. In our study we assessed the relationship of AKAP12 with apoptotic markers, Bcl-2 and p53. **Materials and Methods:** Our study included 45 cases that were histopathologically diagnosed with colorectal carcinoma from the tissue samples acquired by surgical resection. AKAP 12, Bcl-2, and p53 expression was examined by immunohistochemistry. **Results:** A total of 45 colorectal adenocarcinoma patients - 17 (37.8%) females and 28 (62.2%) males - were included in this study. AKAP12 expression was found to be negative in 8 patients (17.8%), and positive in 37 patients (82.2%). Bcl-2 was found positive in 6 patients (13.3%) and p53 in 29 patients (55.6%). AKAP12 expression had no significant relation with Bcl-2 and p53 expression (p:0.939, p:0.079, respectively). **Conclusions:** Although various studies have pointed to apoptotic activity of AKAP12, the literature is limited regarding relations with p53 or Bcl-2 expression. In the present study, we found no relation in colorectal carcinomas.

Keywords: Colorectal carcinoma - apoptosis - AKAP12 - p53 - Bcl-2

Asian Pac J Cancer Prev, 15 (8), 3415-3418

Introduction

Gravin was first defined as a minor antigen related with poor prognosis in Myasthenia Gravis patients (Gordon et al., 1992; Sasaki et al., 2001). Afterwards it was defined as an orthologous protein of SseCKS which is related with Protein Kinase C (PKC) in rodents (Lin et al., 1995). After demonstration of Gravin joining to RII isoform of Protein Kinase A (PKA), it was named as A kinase Anchoring protein 12 (AKAP12) (Navert et al., 1997).

AKAP12 is coded at 6q24-25.2, and hotspot deletions of these areas are expressed in prostate, breast and ovarian carcinomas. Three distinct isoforms of AKAP (named as AKAP12/A, AKAP12/B, AKAP12/C) have been detected (305,287 and 250 kDa, respectively) (Gelman, 2002). AKAP12 functions as a scaffolding protein. It is related with PKC, PKA RII, cyclins, colmodulin, β 1-4 galactransferase polipeptide 1, src, β 2 adrenergic receptors, and F-actin (Shih et al., 1999). AKAP12 inhibits oncogenic proliferation, invasion, chemotaxis and neovascularization (Gelman et al., 2010).

Down regulation of AKAP12 that functions as a tumor suppressor gene has been found in association with lung adenocarcinoma, breast carcinoma, gastric carcinoma, esophageal carcinoma, and acute leukemia (Yildirim et

al., 2007; Jin et al., 2008; Tessema et al., 2008; Chai et al., 2009; Mitra et al., 2009).

Duration of development of invasive cancer from normal colon epithelium is about 7-12 years (Kim et al., 2007). Many genetic and epigenetic factors play a role in this process. Apoptosis is one of these factors (Li et al., 2013; Zhu et al., 2013; Acebedo et al., 2014).

Bcl-2 and p53 are two important apoptotic markers. When considered together they are accepted to be the prognostic factors in colon carcinoma (Zhao et al., 2005). It was showed that AKAP12 ceases the cell cycle, and induces apoptosis in cells of fibrosarcoma (Yoon et al., 2007). In our study we searched the relationship of AKAP12 with apoptotic markers Bcl-2 and p53.

Materials and Methods

Patient selection

Our study included 65 cases that were histopathologically diagnosed with colorectal carcinoma (CRC) from the tissue samples acquired by surgical resection in Antalya Education and Research Hospital between 2008 and 2010. We excluded 20 patients whose follow-ups and treatments were not carried out in our hospital. Samples of the remaining 45 patients were used for histopathological

¹Pathology, ⁴Medical Oncology, Antalya Education and Research Hospital, Antalya, ²Medical Oncology, Ministry of Health Batman Regional Government Hospital, Batman, ³Radiation Oncology, Süleyman Demirel University School of Medicine, Isparta, Turkey
*For correspondence: vildansimsir@yahoo.com

staging according to the 7th edition of American Joint Committee on Cancer (AJCC). AKAP 12, Bcl-2, and p53 expressions were examined by immunohistochemical method. The information about demographic data such as age, sex, stage of disease, and treatments were obtained by searching patient files retrospectively.

Tissue preparation and immunohistochemical staining

Resection materials obtained after colorectal surgery were placed in 10% formaldehyde immediately after the process and fixed for 24 hours. After fixation, pathologically sampled tumor samples were buried into paraffin after routine tissue follow-up. Immunohistochemical staining was applied on cross-sections containing nominal tumor samples that were evaluated with hematoxylin and eosin staining. Cross-sections of 4 μ m thickness prepared for immunohistochemical staining were deparaffinized in an oven at 60°C for 2 hours. Afterwards, they were kept in xylene for 30 minutes and 100% alcohol for 30 minutes, and washed with water. Laminas were kept in a solution buffered with 10% citrate in the microwave at maximum power (800 watts) for 15 minutes. Afterwards, the power was decreased by half for an additional 20 minutes in the microwave. Laminas brought out of the microwave were kept at room temperature for 20 minutes. Endogenous peroxidase activity was removed by being kept in 3% hydrogen peroxide for 10 minutes. Laminas washed with phosphate-buffered saline (PBS) were kept with protein blockage after having been treated with 3 \times 5 PBS. After being kept in primary antibodies; AKAP12 (mouse monoclonal, clone 100/D5, dilution 1:50, Abcam, Cambridge, USA), p53 (mouse monoclonal, clone B p53; 12, dilution 1:100, Invitrogen, Carmennillo, Canada), and Bcl-2 (mouse monoclonal, clone clone100/D5, dilution 1:50, Thermo Scientific, Fremont, USA) for 60 minutes, they were washed in PBS for 5 minutes. Afterwards, they were treated with biotinylated secondary antibody (Vector Laboratories, Burlingham, CA) for 20 minutes and washed with PBS for 5 minutes. They were then kept with peroxidase conjugated antibody for 20 minutes. Afterwards, they were washed in PBS for 5 minutes. They were kept in chromogenic DAB for 5 minutes. Laminas were washed under tap water and then counterstained with hematoxylin. They were dehydrated, dried, and covered with Entellan. For negative controls, the primary antibodies were omitted.

Evaluation of immunohistochemically stained sections

Expression rates for the positive tumor cells in the specimens were evaluated by 2 pathologists who were unaware of the patients' clinical features (DS, ASA). In each case, normal colorectal mucosa adjacent to carcinoma showed weak apical cytoplasmic staining with AKAP12. This cytoplasmic staining observed in non-neoplastic surface and gland epithelium was used as the positive internal control for AKAP12 in the evaluation of cases. Vascular structures, fibroblasts, smooth-muscle cells of muscular layers, neural structures, and adipocytes within the cross-section showed no staining. Absence of expression in these structures was used as the negative internal control in immunohistochemical evaluation. The

staining pattern for carcinoma cells were cytoplasmic with AKAP12. Immunohistochemical staining determined in $\geq 10\%$ of the carcinoma cells was considered as positive while the rate of stained carcinoma cells determined in $< 10\%$ was considered as negative. Positive cases were further classified according to the intensity of staining in comparison with adjacent non-neoplastic epithelium (Figure 1A). If the intensity of the staining was similar to adjacent non-neoplastic epithelium, it was scored as mild (1+), cases with strong staining were scored as severe (3+), remaining cases were scored as moderate (2+) staining (Figure 1B,1C,1D).

The p53 expression was assessed according to nuclear staining of the tumor cells. The Bcl-2 expression was determined by nuclear and cytoplasmic staining of the tumor cells. For both of these markers, $\geq 10\%$ staining in the samples was considered as positive, whereas $< 10\%$ staining was assessed as negative (1E,1F).

Statistical analysis

Statistical analyses were carried out using SPSS software for Windows 15.0. Differences between groups were observed by using chi-squared test. P values under 0.05 were considered significant.

Results

A total of 45 colorectal adenocarcinoma patients -17 (37.8%) females and 28 (62.2%) males- were included in this study. Mean age of the patients was 60.4 years (95% confidence interval 56.4-64.3 years) One patient (2.2%) was in stage I, 14 patients (31.1%) were in stage II, 25 patients (55.6%) were in stage III, and 5 patients (11.1%) were in stage IV. The only distant metastasis site for the patients with metastatic disease was liver.

Lymph node involvement determination rate was 64.4% (29 patients). When patient samples were evaluated in terms of histological grades, 4 patients (8.9%) had grade 1 tumor, 36 patients (80%) had grade 2 tumor, and 5 patients (11.1%) had grade 3 tumor. Lymphovascular

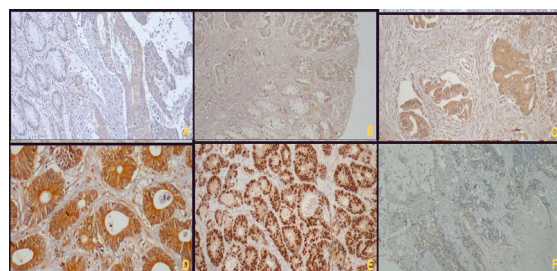


Figure 1. A) Unlike the Cytoplasmic Staining of Tumor Cells, weak apical staining in non-neoplastic epithelium (AKAP12 $\times 40$); B) Mild Cytoplasmic Staining, score 1+: Staining is as intense as adjacent non-neoplastic mucosa (AKAP12 $\times 40$); C) Moderate Cytoplasmic Staining, score 2+ (AKAP12 $\times 100$); D) Strong Cytoplasmic Staining, Score 3+ (AKAP12 $\times 200$); E) p53 Nuclear Positivity in Many of Tumor Cells (p53 $\times 100$); F) More Than 10% of the Tumor Cells Shows Nuclear and Cytoplasmic Staining with Bcl-2 (Bcl-2 $\times 40$)

Table 1. The Relationship of AKAP12 Expression with p53 and Bcl-2 Expression

		Positive (N/%)	Negative (N/%)	Total (N/%)
p53	AKAP12 Positive	22 (88)	9 (64.3)	31 (79.5)
	AKAP12 Negative	3 (12)	5 (35.7)	8 (20.5)
	Total	25 (64.1)	14 (35.9)	39
Bcl-2	AKAP12 Positive	5 (83.3)	32 (82.1)	37 (82.2)
	AKAP12 Negative	1 (16.7)	7 (17.9)	8 (17.8)
	Total	6 (13.3)	39 (86.7)	45

invasion (LVI) was determined in 28 patients (62.2%), perineural invasion (PNI) was determined in 17 patients (37.7%), and lymphocytic response (LR) was determined in 14 patients (31.1%). LR was considered as positive in case of detecting lymphoid infiltrate in the tumor tissue.

The weak cytoplasmic staining of AKAP12 was observed in apical parts of non-neoplastic surface and glandular epithelium. This staining pattern was seen in all of the cases. All of the carcinoma cases showed cytoplasmic AKAP12 expression. According to staining intensity; AKAP 12 expression was determined as 1(+) in 8 patients (17.8%), was determined as 2(+) in 23 patients (51.1%), and was determined as 3(+) in 14 (31.1%) patients. When 1(+) staining intensity was considered as negative, and 2(+) and 3(+) staining intensities were considered as positive; AKAP12 expression was found negative in 8 patients (17.8%), and positive in 37 patients (82.2%).

There were no significant relations between AKAP12 expression, and age, sex, LVI, PNI, LR, T stage, lymph node involvement, metastasis or stage (p: 0.078, p: 0.24, p: 0.37, p: 0.46, p: 0.98, p: 0.117, p: 0.812, p: 0.661, p: 0.481 respectively). There was a significant relation between AKAP12 expression with histological grade (p: 0.026). 32 patients (86.5%) of AKAP12 positive group, and 4 patients (50%) of AKAP12 negative group had grade 2 tumor.

Bcl-2 expression was found positive in 6 patients (13.3%). There were no significant relations between Bcl-2 expression, and sex, age, tumor grade, LVI, PNI, or LR (p: 0.507, p: 0.366, p: 0.421, p: 0.129, p: 0.868, p: 0.827, respectively).

p53 was found positive in 29 patients (64.5%). p53 expression had no significant relation with sex, age, tumor grade, LVI, PNI, or LR (p: 0.986, p: 0.134, p: 0.287, p: 0.294, p: 0.391, p: 0.304, respectively).

AKAP12 expression had no significant relation with Bcl-2, or p53 expression (p: 0.939, p: 0.079, respectively).

Discussion

In our study, we showed that AKAP12 expression is not related with apoptotic markers; Bcl-2 and p53 in patients with CRC.

It is known that AKAP12 affects the apoptotic pathways. AKAP12 inhibits the kinase activity of PKC by joining it (Lin et al., 1996; Chaplin et al., 1998). It causes separation of isoenzymes of PKC from the

plasma membrane. By this way cytoplasmic levels and intracellular localization of cyclin D1 changes (Lin et al., 2000). Cyclin D1 is synthesized during transition from G1 to S phase and it breaks down rapidly when the cell enters S phase (Vermeulen et al., 2003). AKAP12 prevents cyclin D1 in G1 phase and ceases the cell cycle.

Yoon et al. (2007) transferred AKAP12 into the human fibrosarcoma cells and searched the changes in gene expression in their study. They found an increase in Caspase 3 activity of the cells into which AKAP12 was transferred. They showed that proapoptotic bax expression increased while antiapoptotic Bcl-2 expression decreased. In this study, it is showed that AKAP12 changes the levels and intracellular localization of cyclin D1 (Yoon et al., 2007). We could not find such a relation between AKAP12 and Bcl-2.

In a study of CRC cultures, re-expression of AKAP 12 induces apoptosis. It was suggested that AKAP12 plays a role in colon carcinogenesis (Liu et al., 2011). Daoud et. al searched the down regulating and up regulating genes by p53 re-expression in human colon cancer cells by microarray method and they found that AKAP 12 is one of the up regulating genes (Daoud et al., 2003). In cells with DNA damage, p53 stops the cell cycle during transition from G1 to S phase. By this way, cells with DNA damage cannot proliferate and they are destroyed by apoptotic pathway. However DNA damaged cells expressing mutated p53 continue to proliferate (Jalali et al., 2011). In normal cells, p53 is expressed in small amounts that cannot be detected by immunohistochemical method. As a result of various mutations and deletions in p53 localized in short arm of chromosome 17, mutant p53 develops. Mutant p53 can be expressed in high levels in tumor cells (Kerns et al., 1992). It is not known whether AKAP12 detected by immunohistochemical method is mutant or functional. Although there is no statistically significant difference between the groups, in p53 positive group (group consisting of mutant p53); the rate of AKAP12 expression was found as 83.6 % (Table 1). Immunohistochemical staining of normal colonic mucosa as well as the tumor cells supports the idea that this AKAP12 is a normally functioning AKAP12.

Bcl-2 gene is firstly identified in patients with B cell follicular lymphoma establishing t(14;18) translocation, but its expression is not related to this translocation. Bcl-2 increases the life cycle of the cell by inhibiting apoptosis and therefore increases the exposure to mutagenic factors. In most of the human tumors a relation between Bcl-2 expression and survival has been shown (Yildirim et al., 2012). In studies searching Bcl-2 expression in colon cancer, expression rates were found between 31%-70% (Menezes et al., 2010). In our study; Bcl-2 expression rate was similar to these results. Similar to the relation between AKAP12 and p53, we found that AKAP12 was negative in 90.3% of the Bcl-2 negative group, and the relation was not statistically significant (Table 1). Briefly, AKAP12 expression showed no significant difference in p53 positive/Bcl-2 negative group.

Development and progression of cancer is a complex process. There are many biological markers such as oncogenes, regulators of cell cycle, DNA repair genes

that play a role in the initiation, progression, invasion and development of metastasis. They are used in determining prognosis and response to therapy. Apoptosis also plays an important role in carcinogenesis. Various studies defined the apoptotic activity of AKAP12. There are few studies in the literature searching the relation of AKAP12 with p53 or Bcl-2 expressions. In our study, we searched the relation of AKAP12 with both p53 and Bcl-2 in CRC, and found that there is no relation between either of them.

References

- Acebedo AR, Amor EC, Jacinto SD (2014). Apoptosis-inducing activity of HPLC fraction from *Voacanga globosa* (Blanco) Merr. on the human colon carcinoma cell. *Asian Pac J Cancer Prev*, **15**, 617-22.
- Chapline C, Cottom J, Tobin H, et al (1998). A major, transformation-sensitive PKC-binding protein is also a PKC substrate involved in cytoskeletal remodeling. *J Biol Chem*, **273**, 19482-99.
- Choi MC, Jong HS, Kim TY, et al (2004). AKAP12/Gravin is inactivated by epigenetic mechanism in human gastric carcinoma and shows growth suppressor activity. *Oncogene*, **23**, 7095-103.
- Daoud SS, Munson PJ, Reinhold W, et al (2003). Impact of p53 knockout and topotecan treatment on gene expression profiles in human colon carcinoma cells: a pharmacogenomic study. *Cancer Res*, **63**, 2782-93.
- Gelman IH (2010). Emerging Roles for SSeCKS/Gravin/AKAP12 in the control of cell proliferation, cancer malignancy, and barrierogenesis. *Genes Cancer*, **1**, 1147-56.
- Gelman IH (2002). The role of SSeCKS/gravin/AKAP12 scaffolding proteins in the spatiotemporal control of signaling pathways in oncogenesis and development. *Front Biosci*, **7**, 1782-97.
- Gordon T, Grove B, Loftus JC, et al (1992). Molecular cloning and preliminary characterization of a novel cytoplasmic antigen recognized by myasthenia gravis sera. *J Clin Invest*, **90**, 992-9.
- Jalali MM, Heidarzadeh A, Zavarei MJ, Sarmast H (2011). p53 overexpression impacts on the prognosis of laryngeal squamous cell carcinomas. *Asian Pac J Cancer Prev*, **12**, 1731-4.
- Jin Z, Hamilton JP, Yang J, et al (2008). Hypermethylation of the AKAP12 promoter is a biomarker of Barrett's-associated esophageal neoplastic progression. *Cancer Epidemiol Biomarkers Prev*, **17**, 111-7.
- Kerns BJ, Jordan PA, Moore MB, et al (1992). p53 overexpression in formalin-fixed, paraffin-embedded tissue detected by immunohistochemistry. *J Histochem Cytochem*, **40**, 1047-51.
- Kim GP, Colangelo LH, Wieand HS, et al (2007). National Cancer Institute. Prognostic and predictive roles of high-degree microsatellite instability in colon cancer: a National Cancer Institute-National Surgical Adjuvant Breast and Bowel Project Collaborative Study. *J Clin Oncol*, **25**, 767-72.
- Li HY, Zhang Y, Cai JH, Bian HL (2013). MicroRNA-451 inhibits growth of human colorectal carcinoma cells via downregulation of Pi3k/Akt pathway. *Asian Pac J Cancer Prev*, **14**, 3631-4.
- Lin X, Nelson PJ, Frankfort B, et al (1995). Isolation and characterization of a novel mitogenic regulatory gene, 322, which is transcriptionally suppressed in cells transformed by src and ras. *Mol Cell Biol*, **15**, 2754-62.
- Lin X, Tomblor E, Nelson PJ, Ross M, Gelman IH (1996). A novel src- and ras-suppressed protein kinase C substrate associated with cytoskeletal architecture. *J Biol Chem*, **271**, 28430-8.
- Lin X, Nelson P, Gelman IH (2000). SSeCKS, a major protein kinase C substrate with tumor suppressor activity, regulates G(1)->S progression by controlling the expression and cellular compartmentalization of cyclin D. *Mol Cell Biol*, **20**, 7259-72.
- Liu W, Guan M, Hu T, Gu X, Lu Y (2011). Re-expression of AKAP12 inhibits progression and metastasis potential of colorectal carcinoma *in vivo* and *in vitro*. *PLoS One*, **6**, 24015.
- Menezes HL, Jucá MJ, Gomes EG, et al (2010). Analysis of the immunohistochemical expressions of p53, Bcl-2 and Ki-67 in colorectal adenocarcinoma and their correlations with the prognostic factors. *Arq Gastroenterol*, **47**, 141-7.
- Mitra PS, Basu NK, Owens IS. (2009) Src supports UDP-glucuronosyltransferase-2B7 detoxification of catechol estrogens associated with breast cancer. *Biochem Biophys Res Commun*, **382**, 651-6.
- Nauert JB, Klauck TM, Langeberg LK, Scott JD (1997). Gravin, an autoantigen recognized by serum from myasthenia gravis patients, is a kinase scaffold protein. *Curr Biol*, **7**, 52-62.
- Sasaki H, Kunimatsu M, Fujii Y, et al (2001). Autoantibody to gravin is expressed more strongly in younger and nonthymomatous patients with myasthenia gravis. *Surgery Today*, **31**, 1036-7.
- Shih M, Lin F, Scott JD, Wang HY, Malbon CC (1999). Dynamic complexes of beta2-adrenergic receptors with protein kinases and phosphatases and the role of gravin. *J Biol Chem*, **274**, 1588-95.
- Tessema M, Belinsky SA (2008). Mining the epigenome for methylated genes in lung cancer. *Proc Am Thorac Soc*, **5**, 806-10.
- Vermeulen K, Berneman ZN, Van Bockstaele DR (2003). Cell cycle and apoptosis. *Cell Prolif*, **36**, 165-75.
- Yildirim M, Paydas S, Tanriverdi K, et al (2007). Gravin gene expression in acute leukaemias: clinical importance and review of the literature. *Leuk Lymphoma*, **48**, 1167-72.
- Yildirim M, Suren D, Goktas S, et al (2012). The predictive role of Bcl-2 expression in operable locally advanced or metastatic gastric carcinoma. *J BUON*, **17**, 106-9.
- Yoon DK, Jeong CH, Jun HO, et al (2007). AKAP12 induces apoptotic cell death in human fibrosarcoma cells by regulating CDKI-cyclin D1 and caspase-3 activity. *Cancer Lett*, **254**, 111-8.
- Zhao DP, Ding XW, Peng JP, Zheng YX, Zhang SZ (2005). Prognostic significance of Bcl-2 and p53 expression in colorectal carcinoma. *J Zhejiang Univ Sci B*, **6**, 1163-9.
- Zhu JH, Hong DF, Song YM, et al (2013). Suppression of cellular apoptosis susceptibility (CSE1L) inhibits proliferation and induces apoptosis in colorectal cancer cells. *Asian Pac J Cancer Prev*, **14**, 1017-21.