

<Case Report>

The treatment of lower extremity defects with severe proliferative tissue using an adjustable horizontal mattress suture in a Tosa dog

Suyoung Heo, Namsoo Kim*

Department of Veterinary Surgery, College of Veterinary Medicine, Chonbuk National University, Jeonju 561-756, Korea

(Received: December 4, 2013; Revised: March 21, 2014; Accepted: April 28, 2014)

Abstract : A 2-year-old male Tosa was admitted for treatment of a non-healing wound on the right forelimb. Skin tests were unremarkable; however, the lesion contained severe proliferative tissue. Surgical treatment was conducted due to the extensive skin defect and granulation tissue present. Following removal of the proliferative tissue, the wound was closed using the adjustable horizontal mattress suture method with multiple punctate relaxing incisions. The proliferative tissue healed completely after the surgical treatment. This technique can be considered an alternative treatment for the proliferative tissue when conditions require a skin graft or flap after surgical treatment.

Keywords : adjustable horizontal mattress suture, dog

Various surgical techniques are used for reconstruction of skin defects in veterinary medicine [2]. If the lesion is small and without any skin tension, a primary closure can be used; however, a skin graft or flap may be needed when the lesion is too wide for initial skin apposition. Unfortunately, there are few surgical options available when the injury occurs at the lower portions of the extremities, due to limited skin laxity. Furthermore, most axial pattern flaps cannot reach the distal regions of the forelimbs [1]. Tension relieving techniques may be used for wounds involving less than 30% circumference of the limb. Of these, adjustable horizontal mattress suture (AHMS) can close a massive skin defect in the extremities without requiring a skin graft or flap [1, 4]. Free and mesh graft insertions are recommended alternative options; however, these alternative techniques require a second surgery and an experienced surgeon [1, 2].

This case report describes the use of AHMS with multiple punctate relaxing incisions for the treatment of lower extremity defects, using a case example of a Tosa dog with excessive proliferative tissue.

A two-year-old, 42 kg, intact male Tosa was admitted to the Animal Medical Center at Chonbuk National University for the treatment of a non-healing wound on the right forelimb. This dog had a history of dog bite wounds to the bilateral forelimbs that occurred 2 months prior to presentation. A skin wound on the left forelimb was treated at a local clinic 1 month prior to this visit. On physical examination, the patient exhibited intermittent weight-bearing lameness on the right forelimb, and a non-healing wound was observed in the right

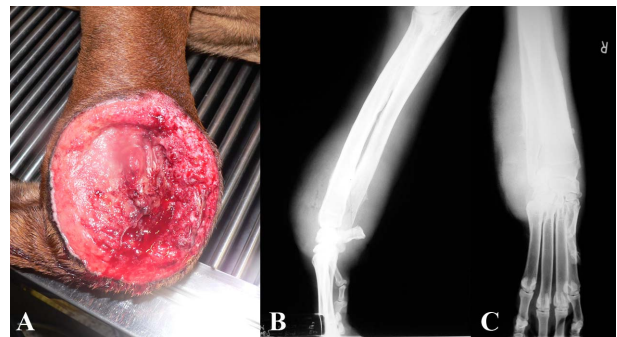


Fig. 1. (A) Right carpal joint demonstrates an extensive skin defect, ulcer, and proliferative tissue associated with acral lick dermatitis. (B) The radiographs of the right forelimb show swelling of the soft tissue and a topical bone reaction.

carpal joint region, with extensive skin defect, ulcer, and chronic granulation tissue (Fig. 1A). The results of a number of tests for various skin diseases were unremarkable. Radiography revealed swelling of soft tissue and a topical bone reaction in the affected limb (Figs. 1B and C). We diagnosed the lesion as a bite wound which failed to heal, and pursued surgical treatment due to the extensive skin defect and granulation tissue. The wound was managed open, using a wet-to-dry contact dressing, with daily debridement and lavage for 5 days.

Prior to surgery, premedication was carried out with atropine (0.02 mg/kg SC, Atropine Sulfate Daewon; Daewon Pharm, Korea) and butorphanol (0.3 mg/kg IM, Butophan

*Corresponding author

Tel: +82-63-270-2800, Fax: +82-63-270-3780

E-mail: namsoo@chonbuk.ac.kr

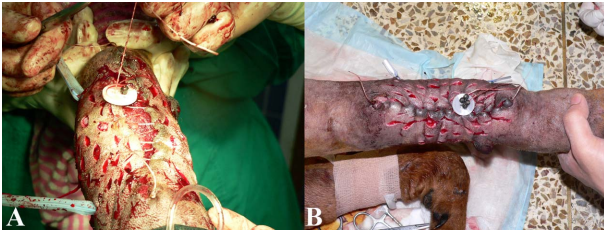

Fig. 2. Intraoperative view. (A) An adjustable horizontal mattress suture was placed using a sewing button and split shot. (B) The wound could be apposed 6 days after the operation.

Inj; MyungMoon Pharm, Korea). General anesthesia was induced with propofol (6 mg/kg IV, Anepol IN; HaNa Pharm, Korea) and was maintained with isoflurane (Forane Soln; JW pharmaceutical, Korea) delivered in oxygen. Cephalexin (22 mg/kg IV q 2 h, Methilexin Inj; Union Korea Pharm, Korea) was administered prior to induction of anesthesia.

The limb was prepared for aseptic surgery with the patient in a lateral recumbent position. The open wound was debrided with sterile gauze. The peripheral epithelium and excessive fibrous tissue were excised. The wound could not initially be apposed because of a large defect and contraction. On each side of the wound, a 1-0 nylon suture was placed intradermally using a continuous suture pattern. At one end of the wound, two split shots were secured with a sewing button to maintain tension. After a length of Penrose drain was placed in the wound, the suture was pulled up and tension was maintained between the two wound edges using multiple punctate relaxing incisions (Fig. 2A). The split shot was closed and a Robert-Jones splinting bandage was applied to protect the wound. Tension on the suture was gradually increased and held for 6 days. Wound healing and relaxing incisions were uneventful. An Elizabethan collar was applied to prevent licking of the wound site. There was no evidence of wound complications or bone reactions 6 months postoperatively. Further follow-up was not possible because the dog died from unrelated circumstances involving bite wounds from another dog.

It is a challenge to reconstruct a skin defect on the lower extremities due to the lack of tissue [1]. Furthermore, there is severe proliferative tissue in these lesions, as seen in our case; this tissue must be removed for successful management of the lesion. In cases such as these, a skin graft or flap may be needed, as the massive skin defect mostly occurs on the lower portion of the limb. It is difficult to use the axial pattern flap on skin defects of the lower extremities. The skin grafts that can be used for reconstruction of serve defects in the lower extremities are classified as split and full-thickness

grafts. Full-thickness skin grafts are more indicated for small animals and this technique is easily harvested by surgeons without requiring special equipment [1, 5]. Full-thickness skin grafts are classified as sheet, mesh, strip, or seed forms. The mesh form graft is preferred on the lower portions of limbs, in clinical practice. This form has multiple advantages, including ease of use, success of graft take, and final cosmetic outcome [1, 3, 5]. However, a second surgery is required to get the skin graft to the donor site. AHMS can be used for large defects on the lower limbs without requiring a skin graft or flap [4]. This technique gradually stretches the skin using an intradermal suture with a sewing button and a split shot. In addition, AHMS can be performed using relaxing incisions [4]. Unfortunately, AMHS can create a biological tourniquet when used for the treatment of lower extremity skin defects. However, this disadvantage is easily corrected by loosening the AHMS sutures and relaxing the incisions.

Lower limb wounds are common skin conditions in clinical medicine; however, skin defects with severe proliferative tissue in the lesion, as seen in our case, is unusual. We have successfully treated this lower extremity defect with severe proliferative tissue using AHMS and multiple punctate relaxing incisions. This technique can be considered an alternative to surgical treatments in lower extremity defects that require a skin graft or flap.

Acknowledgments

This research was supported by Basic Science Research Program through the National Research Foundation of Korea (NRF) funded by the Ministry of Education, Science and Technology (1301001074).

References

1. **Fowler D.** Distal limb and paw injuries. *Vet Clin North Am Small Anim Pract* 2006, **36**, 819-845.
2. **Pavletic MM.** Atlas of Small Animal Wound Management and Reconstructive Surgery. 3th ed. pp. 17-29, Wiley-Blackwell, Ames, 2010.
3. **Siegfried R, Schmökel H, Rytz U, Spreng D, Schawalder P.** Treatment of large distal extremity skin wounds with autogenous full-thickness mesh skin grafts in 5 cats. *Schweiz Arch Tierheilkd* 2004, **146**, 277-283.
4. **Swaim SF, Henderson RA.** Small Animal Wound Management. 2nd ed. pp. 143-190, Lippincott Williams & Wilkins, Baltimore, 1997.
5. **Tong T, Simpson DJ.** Free skin grafts for immediate wound coverage following tumour resection from the canine distal limb. *J Small Anim Pract* 2012, **53**, 520-525.