

RESEARCH ARTICLE

Expression of Osteopontin in Non-small Cell Lung Cancer and Correlative Relation with Microvascular Density

Ting-Ting Yu[&], Zhi-Gang Han, Li Shan^{*}, Jie Tao, Tao Zhang[&], Shuai-Fei Yuan, Hong-Li Shen

Abstract

Background and Objective: Lung cancer is one of the malignant diseases which most seriously threat humankind survival and development. This study aimed to assess osteopontin (OPN) expression in non-small cell lung cancer (NSCLC) and any relationship with clinicopathological features. **Methods:** Immunohistochemistry was used to determine OPN expression and microvascular density (MVD) in 120 cases of NSCLC also undergoing clinical assessment. **Results:** Moderately positive expression of OPN was found in 34.6% (41/120) and strong expression in 47.5% (57/120) of the NSCLCs; OPN expression in carcinomas was higher than in pericarcinoma tissues ($P < 0.05$). While no obvious association was observed with NSCLC patient age, gender, maximum diameter of the tumor and pathological type, OPN expression was more commonly detected in poorly differentiated carcinoma tissue and lymph node metastasis as well as at advanced clinical stage ($P < 0.05$); OPN expression in cancer tissue was positively correlated with MVD ($r = 0.839$, $P = 0.000$). **Conclusion:** OPN plays an important role in promoting tumor angiogenesis and progress of NSCLCs and has the possibility to become the new target for therapy.

Keywords: Lung cancer - osteopontin - microvascular density - immunohistochemistry

Asian Pac J Cancer Prev, 15 (1), 29-32

Introduction

Osteopontin (OPN) is a protein secreted by bone stromal cell with bone specificity and rich sialic acid, which mainly plays a role of bridge between the cell and its substrate. Several research results at home and abroad show that as a new cytokines, the high expression of OPN in breast cancer, renal cancer, esophageal cancer, endometrial cancer and a variety of digestive tract tumors is closely related to the growth, migration and invasion of tumor cell (Huang et al., 2012; Hartung et al., 2013; Sun et al., 2013). Currently, domestic and foreign literature on expression of OPN in non-small cell lung cancer (NSCLC) and its relationship with patients' clinicopathological parameters, especially the researches on the correlation between OPN and microvascular density (MVD) is rarely reported. In this study, immunohistochemical method is used to detect the OPN in NSCLC and analyze the relationship between OPN and patients' clinicopathological parameters and MVD.

Materials and Methods

Object of study

120 cases of NSCLC samples treated with excision surgery in Affiliated Tumor Hospital of Xinjiang Medical

University from May, 2008 to September, 2012 were randomly selected. Each patient's clinical data was complete and pathological wax block was intact; all the patients were not received preoperative radiotherapy, chemotherapy, targeted, intervention and biological anti-tumor treatment; 87 were men and 33 were women aged from 32 to 74 (mean age 57.6 ± 11.5); the patients were classified as follows: 44 cases were squamous cell carcinoma, 69 cases were adenocarcinoma, and 7 cases were other pathological types; non cancerous lung tissue (> 5 cm away from tumor) was taken as the control pericarcinoma tissue.

Immunohistochemical method

All the postoperative pathological specimens were fixed with formaldehyde, organized with routine paraffin embedding and cut serial sections with the thickness of 4 μ m; the detection was performed according to the S-P steps of immunohistochemical method. The immunohistochemical kit was purchased from Shanghai Dingjie Biological Technology Co., Ltd; NSCLC tissue sections were conventionally dewaxed and placed in citrate buffer (pH = 0.6) for the antigen retrieval under high pressure and at high temperature. 3% hydrogen peroxide was added to the solution, which was incubated at room temperature for 5min. PBS rinse solution was used to

Department of Chemotherapy, Tumor Hospital Affiliated to Xinjiang Medical University, Urumqi, China [&]Equal contributors ^{*}For correspondence: xjshanli@163.com

Table 1. Relation Between OPN Expression and Clinicopathological Parameters

	n	OPN			X ²	P
		(-) n=22	(+) n=41	(++) n=57		
Age(year)						
<60	69	11(15.4)	20(29.5)	38(55.1)	1.168	0.558
≥60	51	10(19.6)	18(35.3)	23(45.1)		
Gender					0.44	0.813
Male	87	15(17.2)	31(35.6)	41(47.1)		
Female	33	7(21.2)	10(30.3)	16(48.5)		
Tumor size(cm)					0.091	0.956
<3	72	13(18.1)	24(33.3)	35(48.6)		
≥3	48	9(18.8)	37(35.4)	22(45.8)		
Pathology typing					1.307	0.86
Squamous carcinoma	44	7(15.9)	15(34.1)	22(50.0)		
Adenocarcinoma	69	13(18.8)	23(33.3)	33(47.8)		
Other types	7	2(28.6)	3(42.9)	2(28.6)		
Lymph node metastasis					7.136	0.028
Present	43	3(0.7)	14(32.6)	26(60.5)		
Absent	77	19(24.7)	27(35.1)	31(40.3)		
Differentiation					26.349	<0.001
Well	32	15(46.9)	10(31.3)	7(21.9)		
Moderate	43	5(11.6)	15(34.9)	23(53.5)		
Low	45	2(4.4)	16(35.6)	27(60.0)		
Pathological stage (TNM)					9.521	0.049
I	53	15(28.3)	20(37.7)	18(34.0)		
II	39	5(12.8)	12(30.8)	22(56.4)		
III	28	2(7.1)	9(32.1)	17(60.7)		

repeatedly wash the sample and calf serum was added for blocking. After the addition of human-mouse anti-human OPN monoclonal antibody (Maixin-Bio, Fuzhou, China; dilution: 1:200), the sample incubated at the restrictive temperature (4 °C) for 12 h. At the 2nd day, streptomycin antibiotic-peroxidase solution was added and the sections were incubated at the room temperature for 5min. After washing in PBS, according to the manufacturer's instructions, immunoreactivity was visualized using 3, 30-diaminobenzidine (DAB). The sections then were processed with hematoxylin counterstaining and rinsed by distilled water, and mounted by neutral gum. For every staining, the known positive sections were used as positive controls and PBS was used to replace the primary antibody as negative controls.

Judgment of results of OPN

The prepared immunohistochemical sections were evaluated by two independent pathologists in our hospital with single blind method, and if dispute appeared, it was determined by one senior pathology expert; when tan or brown granules occurred in the cytoplasm of cancer cells, OPN staining was recognized as being positive. The microscope was used to observe the staining of cancer cell and count.

The stained slides were assessed for OPN reactivity as follows: the total number of cells and positive cells in five HPF (×200) were calculated to obtain the percentage of positive cells, including: 0, negative, positive cells <5%; 1, weakly positive, positive cells from 5% to 25%; 2, moderate positive, positive cells from 26% to 50%; 3, strong positive, positive cells >50%. According to staining, weak staining=0, moderate staining=1 and strong staining=2. The final score was determined by positivity scores of stained cells and intensity scores of staining;

negative, total score ≤2; moderate positive (+), from 3 to 4; strong positive (+ +), from 5 to 6. Two pathologists reviewed and scored all cases.

MVD count

Most widely used Weidner judgment standard was applied and CD34 staining counted MVD (the reagent was human-mouse anti-human CD34 monoclonal antibody purchased from Beijing Zhongshan Biological Technology Co., Ltd); each section was processed with micro-vascular count from 3 different views in 3 intensive areas of capillaries for the ultimate average value. The obtained value was the relative value of vascular count per unit area, namely, MVD referred to the number of micro-vascular per unit area.

Statistical methods

The data was analyzed with SPSS17.0 statistical software package; t test was used to analyze measurement data of two groups; one way ANOV was used in comparing the measurement data of the group; the relation between expression rate of OPN and patients' different clinical characteristics was analyzed with X² test; the correlative analysis between OPN expression and MVD counting was performed with Spearman rank correlation method; inspection level $\alpha=0.05$, $P < 0.05$ was considered with statistically significant difference.

Results

OPN expressions in carcinoma tissues and pericarcinoma tissues

Positive expression of OPN was mostly in the cytoplasm of NSCLC patients' carcinoma tissues with tan or brown granules; immunohistochemical results showed

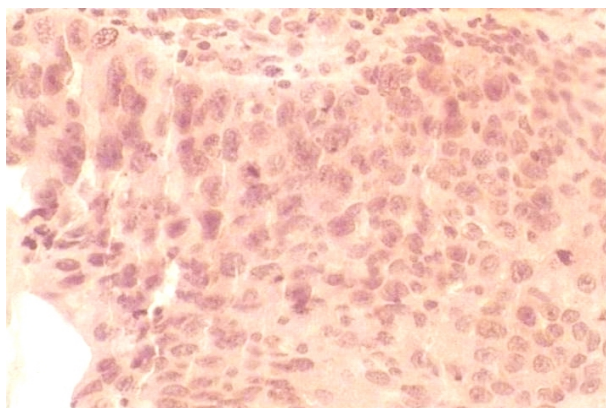


Figure 1. Expression of OPN in Lung Squamous Cell Carcinoma (×200)

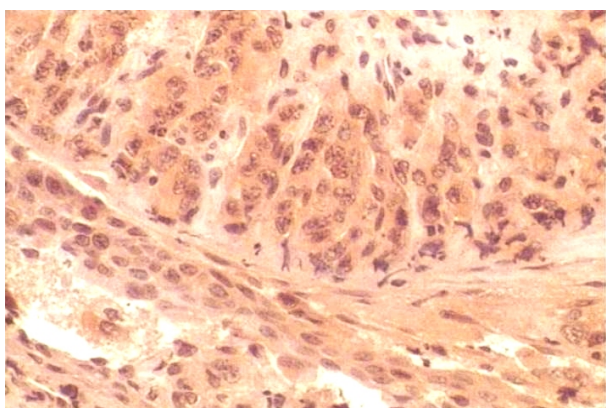


Figure 2. Expression of OPN in Lung Adenocarcinoma (×200)

that positive expression rate of OPN in pericarcinoma tissues was 18.3% (22/120), while in carcinoma tissues was 81.7% (98/120), with statistically significant difference ($P < 0.05$); moderate positive expression rate of OPN in carcinoma tissues was 34.6% (41/120) and strong positive expression rate was 47.5% (57/120) (Figure 1-2).

Relation between OPN expression and clinicopathological parameters

No significant correlation was observed between OPN expression and NSCLC patient's age, gender, maximal tumor size and pathology type ($P > 0.05$); the positive expression rate of OPN of patients with regional lymph node metastasis was 93.0% (40/43) and in patients without regional lymph node metastasis was 75.3% (58/77), with statistically significant difference ($X^2=5.773$, $P=0.016$); positive expression rates of patients of high, medium and low differentiation were 53.1% (17/32), 88.4% (38/43) and 95.6% (43/52), respectively, with statistically significant difference ($X^2=16.39$, $P<0.01$); positive expression rate of patients in stage III was significantly higher than that in the patients of stage II and I (92.9% vs 86.6% vs 71.1%, $X^2=6.343$, $P=0.042$) (Table 1).

Correlation between OPN and MVD expression

CD34 staining was in the vascular endothelial cells with tan staining, and positive staining occurred in a large number of endothelial cells in tumor stroma, and microvascular distribution was uneven (Figure 3). MVD count of NSCLC was 50.4 ± 14.6 , obviously higher than that

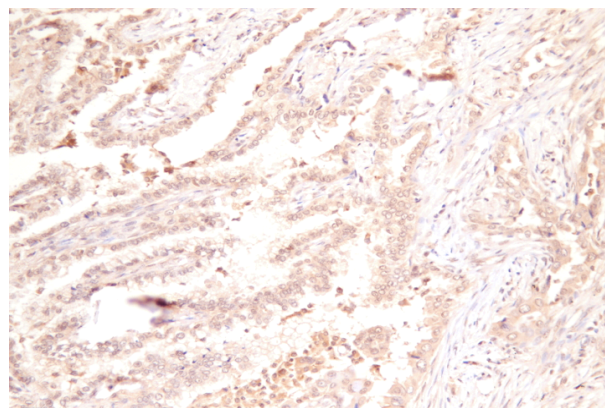


Figure 3. The MVD Counts in NSCLC(×100)

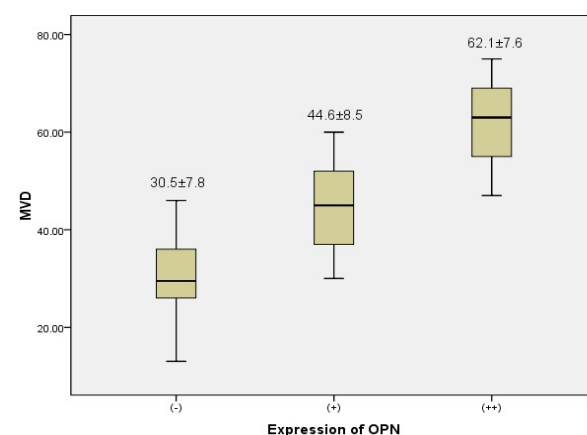


Figure 4. MVD According to the Combination of OPN Expressions

in pericarcinoma tissues (14.8 ± 5.1) ($P < 0.01$); the effect of different expression level of OPN in NSCLC with MVD count was analyzed and the correlative relation was studied (Figure 4). The results showed that OPN expression in carcinoma tissues was positively related to MVD expression, namely, MVD count increased with high expression of OPN ($r = 0.839$, $P = 0.000$).

Discussion

OPN, a secreted phosphorylated glycoprotein with thrombin cracking site, $\alpha 9\beta 1/\alpha 4\beta 1$ combined domain and several binding sites of materials such as Ca^{2+} , can produce a variety of life activities, whose C terminal is coupled with transmembrane glycoprotein CD44. At the same time, OPN can promote the body's immune cells back to the nest to further force malignant tumor cell with distant invasion and metastasis (Elli et al., 2012; Qin et al., 2013; Rao et al., 2013). The abnormal expression of OPN in the body has a certain organization, cell specificity and is adjusted and controlled by several factors such as hormones, cancer suppressor genes, proto-oncogenes, carcinogenic promoting materials and growth factors, etc. Under normal circumstance, OPN expression occurs in breast, respiratory, digestive tract, urinary tissue and normal body fluid, whose main physiological functions include (Luo et al., 2011; Lund et al., 2013; Samitas et al., 2013): (1) combine with integrin receptors on the surface of cell membrane and extracellular matrix to participate in the adhesion and distant metastasis; (2) promote the rise

of vascular endothelial growth factor, assist the migration of endothelial cells and induce the endothelial generation of neovascularization; (4) it is the important factor of bone mineralization to combine with substrate adhesion molecules to regulate the formation or reconstruction of bone tissue or calcific materials; (4) induce inflammation and immune response through Th1, Th2 and IL-12; (5) activate some nuclear factors such as α B to further inhibit the cell apoptosis; (6) interact with integrin to induce the transduction of normal cell mediated signal.

At present, many studies show that abnormal expression of OPN is closely related with the occurrence and development of tumor such as liver cancer, breast cancer, colon cancer and some gynecological malignant tumor, whose possible mechanism is that OPN promotes the formation of neovascularization, chemotactic transfer and adhesion of cytokines as well as extracellular matrix degradation, and inhibits the cell apoptosis in different degree, especially tumor cells (Matušan et al., 2011; Huan et al., 2012; Tsai et al., 2012). At the same time, the research (Qiu et al., 2012) has confirmed that OPN is the important factor to induce the smooth migration of vascular muscle cell induced by angiotensin II. The results of this study show that compared with pericarcinoma tissues, abnormal expression of OPN occurs in the NSCLC patient's carcinoma tissues, which indicates that OPN may participate in the occurrence and development of NSCLC. Through further stratified analysis, OPN expression is not obviously related with NSCLC patient's gender, age, tumor size and pathology type; but OPN expression commonly occurs in NSCLC patients with poorly differentiated carcinoma tissue, lymph node metastasis and advanced clinical staging, with statistically significant difference, which shows abnormal expression of OPN is closely related with outside invasion and distant metastasis, but does not enhance the continued proliferation ability of tumor in a certain fixed position and affect the formation of ecological niche before metastasis. This phenomenon may result from that OPN promotes the neovascularization and lymphatic vessel as well as the increase of vascular permeability and eventually causes lymphatic and blood metastasis. Therefore, we not only study the abnormal expression of OPN in NSCLC but also the relation between OPN expression in cancer tissue and MVD. The tumor micro-vascular density is used to suggest the quantity of neovascularization and is a quantitative indicator of degree of tumor neovascularization; suggest the tumor recurrence, metastasis potential and long-term survival. Besides, it is considered that OPN expression is closely related with growth, metastasis and prognosis of tumor (Ito et al., 2009; Maeda et al., 2012). This study found that the density of MVD in NSCLC cancer tissue was significantly higher than clinicopathological parameters, with obvious difference between two groups. The correlative analysis showed that OPN was positively correlated with MVD expression in NSCLC ($P < 0.01$), which showed that OPN plays a very important role in neovascularization and may provide material basis for the vascularization of tumor in the process of growth and metastasis of tumor, while vascularization further provides necessary pathways for the tumor cell metastasis.

To sum up, high expression of OPN is associated with the differentiation degree of tumor cells in lung cancer, distant metastasis of lymph nodes and clinical characteristics of neovascularization of the tumor and may play a role of promotion and maintenance in vascularization of the tumor.

References

- Elli M, Dagdemir A, Bozkurt C, et al (2012). Serum osteopontin and CD44 levels in lymphoreticular malignancies in children. *Bratisl Lek Listy*, **113**, 534-8.
- Hartung F, Weber GF (2013). RNA blood levels of osteopontin splice variants are cancer markers. *Springer Plus*, **2**, 110.
- Huan JL, Xing L, Qin XJ, et al (2012). Expression and clinical significance of osteopontin in calcified breast tissue. *Asian Pac J Cancer Prev*, **13**, 5219- 23.
- Huang J, Pan C, Hu H, Zheng S, Ding L (2012). Osteopontin enhanced hepatic metastasis of colorectal cancer cells. *PLoS One*, **7**, e47901.
- Ito S, Miyahara R, Takahashi R, et al (2009). Stromal aminopeptidase N expression: correlation with angiogenesis in non-small-cell lung cancer. *Gen Thorac Cardiovasc Surg*, **57**, 591-8.
- Lund SA, Wilson CL, Raines EW, et al (2013). Osteopontin mediates macrophage chemotaxis via α 4 and α 9 integrins and survival via the α 4 integrin. *J Cell Biochem*, **114**, 1194-202.
- Luo X, Ruhland MK, Pazolli E, Lind AC, Stewart SA (2011). Osteopontin stimulates preneoplastic cellular proliferation through activation of the MAPK pathway. *Mol Cancer Res*, **9**, 1018-29.
- Maeda R, Ishii G, Ito M, et al (2012). Number of circulating endothelial progenitor cells and intratumoral microvessel density in non-small cell lung cancer patients: differences in angiogenic status between adenocarcinoma histologic subtypes. *J Thorac Oncol*, **7**, 503-11.
- Matušan-Iljiša K, Damante G, Fabbro D, et al (2011). Osteopontin expression correlates with nuclear factor- α B activation and apoptosis down regulation in clear cell renal cell carcinoma. *Pathol Res Pract*, **207**, 104-10.
- Qin LF, Wang WC, Fang H, et al (2013). Expression of NF- α B and osteopontin of synovial fluid of patients with knee osteoarthritis. *Asian Pac J Trop Med*, **6**, 379-382.
- Qiu ZB, Xu H, Duan C, Xin C (2012). Osteopontin is required for angiotensin II-induced migration of vascular smooth muscle cells. *Pharmazie*, **67**, 553 -8.
- Rao G, Wang H, Li B, et al (2013). Reciprocal interactions between tumor-associated macrophages and CD44-positive cancer cells via osteopontin/CD44 promote tumorigenicity in colorectal cancer. *Clin Cancer Res*, **19**, 785-97.
- Samitas K, Zervas E, Xanthou G, Vily P, Gaga M (2013). Osteopontin is increased in the bronchoalveolar lavage fluid and bronchial tissue of smoking asthmatics. *Cytokine*, **61**, 713-5.
- Sun BS, You J, Li Y, Zhang ZF, Wang CL (2013). Osteopontin knockdown suppresses non-small cell lung cancer cell invasion and metastasis. *Chin Med J (Engl)*, **126**, 1683-8.
- Tsai WC, Tsai WC, Lee HS, et al (2012). Association between Osteopontin and EGFR Expression with Clinicopathological Parameters in Hepatocellular Carcinoma. *Chin J Physiol*, **55**, 412-20.