

## MINI-REVIEW

# FOX A1: a Promising Prognostic Marker in Breast Cancer

Qing Hu<sup>1</sup>, Zhou Luo<sup>2</sup>, Tao Xu<sup>2</sup>, Jun-Ying Zhang<sup>3</sup>, Ying Zhu<sup>2</sup>, Wei-Xian Chen<sup>2</sup>, Shan-Liang Zhong<sup>4</sup>, Jian-Hua Zhao<sup>4\*</sup>, Jin-Hai Tang<sup>5\*</sup>

### Abstract

Accurate diagnosis and proper monitoring of cancer patients remain important obstacles for successful cancer treatment. The search for cancer biomarkers can aid in more accurate prediction of clinical outcome and may also reveal novel predictive factors and therapeutic targets. One such prognostic marker seems to be FOX A1. Many studies have shown that FOX A1 is strongly expressed in a vast majority of cancers, including breast cancer, in which high expression is associated with a good prognosis. In this review, we summarize the role of this transcription factor in the development and prognosis of breast cancer in the hope of providing insights into utility of FOX A1 as a novel biomarker.

**Keywords:** FOX A1 - prognosis - biomarker - breast cancer - systematic review

*Asian Pac J Cancer Prev*, **15** (1), 11-16

### Introduction

Breast cancer is the most common type of female malignancy all over the world. Despite improvement in surgical techniques and oncology treatments, the prognosis of breast cancer is still poor (Desantis et al., 2013). At present, several independent prognostic factors including tumor size, histological subtype and grade, lymph node metastases, hormone receptor status and human epidermal growth factor receptor-2 (HER-2) status have major prognostic value (Hayes 2005). Although these parameters reflect biological features of the tumor and patient, they don't allow adequate prediction of outcome for the individual patient. So the discovery of new prognostic factors should aid in a more accurate prediction of clinical outcome and may also reveal novel predictive factors and therapeutic targets.

Estrogen receptor (ER) expression is an important prognostic and predictive factor in breast cancer and has relevant implications for the biology of this type of carcinomas. However, not all ER-positive breast cancers behave alike (Knight et al., 1980). Knowing why and how some ER-positive breast cancers behave differently than others are important for both research and clinical viewpoint.

One such prognostic markers and novel therapeutic targets seems to be forkhead-box protein A 1 (FOX A1). Many studies have shown that FOX A1 is strongly expressed in a vast majority of cancers, including breast cancer. High expression of FOX A1 is associated with a good prognosis (Wolf et al., 2007; Badve et al., 2007;

Thorat et al., 2008; Habashy et al., 2008; Albergaria et al., 2009; Liu et al., 2010; Hisamatsu et al., 2012; Ijichi et al., 2012; Mehta et al., 2012; Kawase et al., 2013). Moreover, FOX A1 expression correlates with ER-positive breast cancer especially luminal subtype A breast cancer. In this review, we summarize the role of FOX A1 in the development, and prognosis of breast cancer in the hope of providing insights into the utility of FOX A1 as a novel biomarker of breast cancer.

### Structure and Physiological Function of FOX A1

The term 'Forkhead' originated from studies involving founding members of this family in drosophila. The drosophila forkhead was identified in a screen of embryonic-lethal mutations that gave rise to ectopic head structures. FOX A1, also known as HNF3 $\alpha$  (hepatocyte nuclear factor 3 $\alpha$ ), is originally identified for its transcriptional regulation of the genes liver-specific transthyretin (Ttr) and  $\alpha$ 1-antitrypsin (Serpina1) (Costa et al., 1989). As a member of the fox family of transcription factors, FOX A1 express not only in the liver, but also in the breast, pancreas, bladder, prostate, colon and lung and can bind to the promoters of more than hundred genes associated with regulation of cell signaling and the cell cycle (Wolf et al., 2007). FOX A1 contains an amino acid DNA-binding domain or FOX/winged helix domain. This unique DNA binding domain located at the center of the protein consists of three  $\alpha$ -helices and two large loops or wings, which appears like a butterfly in crystal structure.

<sup>1</sup>Department of General Surgery, <sup>3</sup>Department of Oncology, Xuzhou Medical College, Xuzhou, <sup>2</sup>Department of Oncology, Nanjing Medical University, <sup>4</sup>Clinical Laboratory Center, <sup>5</sup>Department of General Surgery, Jiangsu Cancer Hospital, Nanjing, China \*For correspondence: doczhaojianhua@163.com, doctangjinhai@163.com

FOXA1 contains conserved nuclear localization sequences and homology in the N- and C-terminal transactivation domains, also. Thus, FOXA1 binding to nucleosomes induces an open chromatin configuration enabling the recruitment of other transcriptional regulators (Bernardo and Keri, 2012). This function has led to FOXA1 being coined as ‘pioneering’ or ‘licensing’ factor.

### Roles of FOXA1 in Breast Cancer

The ability of FOXA1 to remodel heterochromatin provides a mechanistic basis for how FOXA1 initiate transcriptional cascades involved in both development and disease. Specifically, FOXA1 is required for development of the mammary gland and is necessary for ER-positive breast. Emphasising its importance, FOXA1 is required for the expression of 50% of ER-regulated genes (Carroll and Brown, 2006). When FOXA1 is silenced in the ER-positive breast cancer, there is a significant loss in global chromatin accessibility coupled with a concurrent loss of ER binding at more than 90% of all ER binding events (Hurtado et al., 2011). This result emphasizes how essential FOXA1 is for ER to function in breast cancer.

Previous studies have shown that FOXA1 can act either as a growth stimulator or as a repressor. As a stimulator, it functions as a pioneer factor that binds to chromatinised DNA, opens the chromatin and enhances binding of oestrogen receptor-alpha (ERα) to its target genes such as TFF1 (trefoil factor 1; pS2) (Beck et al., 1999). In addition to modulating ER activity, FOXA1 also directly binds to the ESR1 (oestrogen receptor 1) promoter and is required for expression of ER mRNA and protein in breast cancer cells (Bernardo et al., 2010). Combined, these results revealed that FOXA1 is not only required for ER activity but also for its expression. As a repressor, two mechanisms were identified that may be involved in the growth inhibitory: blocking the metastatic progression and differential regulation of the ER pathway (Wolf et al., 2007). It has been shown that FOXA1 over-expression can block the metastatic progression by influencing expression of the BRCA1 associated cell cycle inhibitor, p27 and promoting E-cadherin expression. FOXA1 binds to the promoter of p27 and synergizes with BRCA1 (breast-cancer susceptibility gene to decrease cell number. Similarly, FOXA1 directly stimulates transcription of the E-cadherin gene (CDH1), and the associated induction of E-cadherin expression decreases the migratory capacity of breast cancer cells. Activation of CDH1 occurs in the absence of ER, supporting the notion that FOXA1 has ER-independent roles in dictating a more differentiated luminal cell phenotype. On the other hand, FOXA1 inhibited the ER pathway in ERα-positive cells and slowed cells’ growth. A brief figure about the role of FOXA1 can be seen in Figure 1.

The dual role of FOXA1 in breast cancer has shown controversial results with both growth stimulation and inhibition: tumor promoter at initial stages, but tumor suppressor in later stages. Although at outset, anything that increases ERα activity can be considered to have a negative role in breast cancer, FOXA1 does not appear to fall into that category (Nakshatri and

Badve, 2007). Due to complex interaction between ER and its associated signaling pathways, the crosstalk between FOXA1 and ER has been suggested to favor the expression of differentiation-associated genes rather than proliferation-associated genes (Badve and Nakshatri, 2009). So FOXA1 may result in well-differentiated breast cancer and over-expressed ER, which indicated a good prognosis in breast cancer. In addition, FOXA1 proved essential for the cellular response to tamoxifen, even in those that have transitioned to tamoxifen resistance (Hurtado et al., 2011). These new findings, plus the inhibited role, the observations may therefore provide a molecular explanation for the correlation of FOXA1 with a favourable prognosis in breast cancer.

### Methods of Analyzing FOXA1

Since Wolf et al., were the first to investigate the expression of FOXA1 in breast cancer by immunohistochemistry (IHC) (Wolf et al., 2007), a number of publications soon followed. Thus, the expression of FOXA1 was mainly analyzed by IHC. Briefly, after dewaxing, hydration, and antigen retrieval, slides were incubated in primary antibody and the reaction was visualized using En Vision and System-HRP. Immunostained slides were scored as percentages of nuclear staining in a maximum of 1,000 cells per sample. Percentage (P) and intensity (I) of nuclear expression were multiplied to generate numerical score (S = P×I) (Habashy et al., 2008).

A report from the St. Gallen International Expert Consensus recommended use of proliferation markers (e.g., Ki67 index) or multigene assays to help select appropriate systemic treatment and judge prognosis, in addition to traditional parameters such as stage, grade, and status of ER, PR, and HER2 (Goldhirsch et al., 2009). Although multigene prognosis assays such as Oncotype Dx and Mammaprint offer excellent approaches to determine gene expression profiles, these assays are very expensive, have not been prospectively validated, and are difficult to use in daily practice. In addition, some of these assays require use of fresh tissue for processing (Kim and Paik 2010). Intriguingly, FOXA1 negatively correlated with recurrence score leading the authors to suggest FOXA1 immunostaining could function as a more cost-effective pathological marker than the Oncotype DX. Of note, FOXA1 is not a component of Oncotype DX (Ademuyiwa et al., 2010). Accordingly, FOXA1

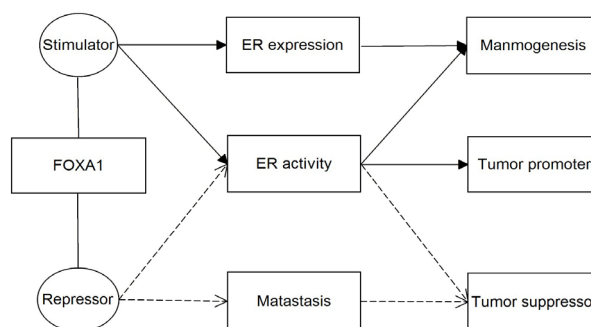


Figure 1. The Role of FOXA1 in Breast Cancer

**Table 1. Main Results Between FOXA1 and Clinicopathological Parameters**

Parameters	Wolf et al	Badve et al	Thorat et al	Habashy et al	Albergaria et al	Liu et al	Hisamatsu et al	Ijichi et al	Metha et al
Age	0.48	NA	NA	0.42	NA	0.08	0.56	0.92	<0.01
Histological type	NA	NA	0.62	NA	<0.01	NA	NA	NA	<0.01
Histological grade <sup>b</sup>	0.04	<0.01	0.03	0.07	0.00	0.00	0.00	0.02	<0.01
Tumor size	0.31	NA	0.16	<0.01	0.01	0.11	NA	0.05	<0.01
Nodal status	0.17	0.64	0.72	0.13	0.02	0.19	0.10	0.92	<0.01
ER <sup>a</sup>	0.03	<0.01	<0.01	<0.01	<0.01	0.00	<0.01	0.03	<0.01
PR <sup>a</sup>	0.25	<0.01	<0.01	<0.01	<0.01	0.00	0.00	0.02	<0.01
HER2	NA	0.79	0.80	0.93	0.02	0.08	0.09	0.37	NA
Ki67 <sup>b</sup>	0.09	NA	NA	NA	NA	0.01	0.01	NA	<0.01
CK14 <sup>b</sup>	NA	NA	<0.01	0.01	0.01	NA	NA	NA	NA
CK5/6 <sup>b</sup>	NA	NA	<0.01	<0.01	0.03	NA	NA	NA	NA

NA, not applicable; IHC, immunohistochemistry; LVI, lymphovascular invasion; ER, estrogen receptor; PR, progesterone receptor; HER2, human epidermal receptor 2; EGFR, epidermal growth factor receptor; CK14, cytokeratin 14; CK5/6, cytokeratin 5/6; <sup>a</sup>positive correlation; <sup>b</sup>negative correlation

**Table 2. Review of Literature for Foxa1 Demonstrating Predictive Significance in Survival**

Study	Year	Country	Num	Positive rate	Method	Follow-up (months)	Survival analyses	OS	BCCS	DFS	RFS
Badve et al	2007	Canada	438	74.3%	IHC	185	Kaplan–Meier	NA	Positive	NA	NA
Thorat et al	2007	UK	245	75.5%	IHC	67	Kaplan–Meier	Positive	NA	NS	NA
Habashy et al	2008	UK	880	55.0%	IHC	125	Kaplan–Meier	NA	Positive	NS	NA
Albergaria et al	2009	UK	249	41.5%	IHC	60	Kaplan–Meier	NA	NA	Positive	NA
Liu et al	2010	China	213	70.4%	IHC	62	Kaplan–Meier	Positive	NA	Positive	NA
Hisamatsu et al	2011	Japan	239	71.4%	IHC	120	Kaplan–Meier	Positive	NA	NA	Positive
Ijichi et al	2012	Japan	113	74.1%	IHC	60	Kaplan–Meier	Positive	NA	NA	Positive
Metha et al	2012	Canada	4444	85.9%	IHC	120	Kaplan–Meier	NA	Positive	NA	Positive
Kawase et al	2013	Japan	42	NA	IHC	44	Kaplan–Meier	NA	NA	Positive	NA

Num, number of patients; HR, hazard ratio; 95%CI, 95% confidence interval; IHC, immunohistochemistry; UK, united kingdom; OS, overall survival; BCCS, breast cancer specific survival; DFS, disease-free survival; RFS, relapse-free survival; NA, not available; NS, not significant

expression may offer a more useful marker for clinic-based assessment of cancers than the Oncotype Dx assay. However, before FOXA1 expression can be implemented in clinical practice, it is important to verify the clinical relevance of FOXA1 expression in various cohorts of patients with breast cancer.

### Expression of FOXA1 in Breast Cancer

The clinical significance of FOXA1 protein expression in breast has been investigated by multiple groups. FOXA1 expression was observed in a few luminal epithelial cells of the normal breast. The expression was restricted to the nucleus with little or no cytoplasmic staining (Badve et al., 2007). However, the intensity of staining in the breast cancer ranged from weak (11.5%), moderate (19.3%), or strong (55.1%) (Mehta et al., 2012). To date, a number of publications (Table 2) about 7000 human breast cancers provided expression data for FOXA1. The incidence of FOXA1 expression ranged from 41.51%–85.90% in breast cancer and the mean incidence was 77.97% (calculate according to the published articles in Table 2), indicating that the expression of FOXA1 was high level in breast cancer.

FOXA1 significantly associated with ER expression in each study. Moreover, FOXA1 positively correlated with the luminal subtype and negatively correlated with the basal subtype. In fact, FOXA1 expression was shown to be

an important predictor of survival, in addition to the robust association with clinicopathological features. Interestingly, univariate analysis showed that the evaluation of FOXA1 expression had an important value in the assessment of the prognostic risk for breast cancer patient, recurrence, with a magnitude of association similar to the observed for the classical prognostic factors, such as tumor size and lymph node stage, tumor grade, and ER and HER-2 expression. It was worth noting show that FOXA1 and ER $\alpha$  should be used together in order to subclassify breast carcinomas and to predict the outcome of breast cancer patients. (Albergaria et al., 2009). However, whether FOXA1 expression is an independent predictor of survival in the multivariate model is still controversial (Albergaria et al., 2009; Mehta et al., 2012).

The Ki67 index is one of the most important proliferative markers used to assess prognosis, and perhaps more importantly, can reveal the potential value of adding chemotherapy to hormone therapy in patients with hormone receptor (HR)-positive cancer (Yerushalmi et al., 2010). However, there are some problems to be considered for Ki67 index. First, there is currently no widely accepted cutoff value of Ki67 index to determine the necessity of chemotherapy and to accurately assess hormone sensitivity. Second, there is still insufficient evidence to show that adding chemotherapy to hormone therapy improves the prognosis of patients with HR-positive/HER2-negative breast cancer with high Ki67 index or

high risk score on multigene assays. Encouragingly, high FOXA1 expression is significantly correlated with good prognosis in HR-positive breast cancers, regardless of the Ki67 index. Intriguingly, among HR-positive/HER2-negative patients with high FOXA1 expression, there was no difference in recurrence-free survival (RFS) between patients given hormone therapy alone and those given chemotherapy plus hormone therapy (Hisamatsu et al., 2012). These results suggest that adding cytotoxic chemotherapy to hormone therapy offers limited benefit versus hormone therapy alone for patients with high FOXA1 expression. Thus, FOXA1 expression might offer a useful marker for HR-positive/HER2-negative breast cancer to identify patients with good prognosis who may not require chemotherapy.

Recently, expression of FOXA1, as well as other prognostic factors such as ER and Ki67 in pre- and post-treatment specimens in order to investigate their prognostic and predictive potential in women with ER-positive HER2-negative early breast cancer who had been treated with anthracycline and taxane-containing neoadjuvant chemotherapy was analyzed. Expression levels ER, PR and Ki67 were significantly lower in post-treatment tumors compared with those in pretreatment samples. Although expression levels of FOXA1 were also reduced in post-treatment tumors compared to pretreatment specimens, these changes were not significant. Lymph node status, ER and Ki67 expression in pre-treatment tumors were significantly associated with improved clinical and pathological response, while high FOXA1 expression in post-treatment specimens strongly correlated with superior distant disease-free survival (Kawase et al., 2013). The report showed that FOXA1 expression after neoadjuvant chemotherapy was an independent prognostic factor for distant disease-free survival in ER-positive HER2-negative breast cancer.

### Correlation of FOXA1 Expression with Clinicopathological Characteristics

All relevant studies about the correlation of FOXA1 expression with main clinicopathological characteristics have been reviewed. FOXA1 expression was compared with age, histological type, histological grade, tumor size, nodal status, luminal subtype markers like expression of ER, PR, HER2, Ki67, basal subtype markers like CK5/6, CK14. In most of the studies, there was no correlation between FOXA1 expression and clinicopathological parameters such as age, tumor size, nodal status, HER2 (Wolf et al., 2007; Badve et al., 2007; Thorat et al., 2007; Habashy et al., 2008; Liu et al., 2010; Hisamatsu et al., 2012; Ijichi et al., 2012). However, FOXA1 expression was positively correlated with ER, PR and negatively correlated with high histological grade, Ki67, CK5/6, CK14 (Wolf et al., 2007; Badve et al., 2007; Thorat et al., 2007; Habashy et al., 2008; Albergaria et al., 2009; Liu et al., 2010; Hisamatsu et al., 2012; Ijichi et al., 2012; Mehta et al., 2012). Previously performed survival analyses showed that ER-positive or PR-positive was associated with significantly better survival. Tumors with higher grade, larger size, nodal metastases, HER2-positive, high

levels of Ki67, CK5/6 and CK14 correlated significantly with poor survival in breast cancer (Perou et al., 2000). Further, Luminal A tumors were defined as ER- or PR-positive, negative for HER2, and low Ki67. Tumors negative for all three receptors, ER, PR, and HER2, but positive for either of CK5/6 were defined as basal subtype. In fact, luminal subtype breast cancers are good prognosis tumors and basal subtype are poor prognosis tumors (Sorlie et al., 2001). These findings were consistently reproduced in the present study. In addition, FOXA1 expression was negatively correlated with the other clinicopathological parameters such as CK17, E-cadherin and Nottingham Prognostic Index (NPI) which indicated a poor prognosis (Thorat et al., 2007; Habashy et al., 2008; Albergaria et al., 2009). So according to the present correlation, high level of FOXA1 expression indicates that it may be a candidate predictive and classified marker in breast cancer. Main results between FOXA1 and clinicopathological parameters can be seen in Table 1.

### Impact of FOXA1 Expression on Survival of Breast Cancer

FOXA1 over-expression was observed in a variety of cancers and correlated with a favorable clinical outcome. At present, most of studies conducted in UK, Canada, and Japan. The duration of follow-up ranged from 44 months to 185 months. Kaplan–Meier analysis was performed using log-rank test for comparison of linear trends. From the table 2, we found that FOXA1 was a significant predictor of overall survival (OS) (Thorat et al., 2007; Liu et al., 2010; Hisamatsu et al., 2012; Ijichi et al., 2012), breast cancer specific survival (BCSS) (Badve et al., 2007; Habashy et al., 2008; Mehta et al., 2012) and relapse-free survival (RFS) (Hisamatsu et al., 2012; Ijichi et al., 2012; Mehta et al., 2012). However, there was a conflicting result that high FOXA1 levels predicted better disease-free survival (DFS) in breast cancer. Some studies supported that FOXA1 was a significant predictor of DFS (Albergaria et al., 2009; Liu et al., 2010; Kawase et al., 2013). However, Thorat et al., and Habashy et al., reported that it did not reach statistical significance for DFS endpoint (Thorat et al., 2007; Habashy et al., 2008). We found that the two studies both from UK, perhaps the different regions result in the difference. The other reasons may be sample size, living environment contribute to bias, so further research is needed. Review of literature for FOXA1 demonstrating predictive significance in survival can be seen in Table 2.

Similarly, except DFS (Habashy et al., 2008), we found that FOXA1 was a significant predictor of BCSS (Badve et al., 2007; Mehta et al., 2012) and RFS (Hisamatsu et al., 2012) in ER-positive breast cancer. Due to limited data of DFS are available at present, the result should be a worthy topic. In addition, in the subset of ER $\alpha$ -negative breast cancer patients, those who were FOXA1-negative had a 3.61-fold increased risk of breast cancer recurrence when compared with the FOXA1-positive (Albergaria et al., 2009). In turn, the result supports that high expression of FOXA1 is associated with a good prognosis.



## Questions and Prospects

Although high expression of FOXA1 indicated a good prognosis in breast cancer, there are still some questions need to solve in the further. First, what is the role and relationship of the other FOXA family members (eg, FOXA2, FOXA3) in breast cancer prognosis? These factors bind similar consensus sites, and the relative impact on ER $\alpha$  function, as well as on downstream tumor phenotypes, has been only scantily considered. It is still to know that whether the combination of FOXA members can result a better prognosis in breast cancer. Second, what is relationship between FOXA1 and the other transcription factors such as GATA binding protein 3 (GATA3)? GATA3 is not required for FOXA1 expression in the normal mammary gland. However, they do not negate GATA3 binding to the FOXA1 promoter in primary mammary cells (Kouros-Mehr et al., 2006). What is the potential mechanism and difference between FOXA1 and GATA3 in breast cancer prognosis? Third, what is the real role of FOXA1 in HER2 signaling pathway? High FOXA1 expression was noted in ERBB2-positive cell lines suggesting its role in development and maintenance of ERBB2-positive breast cancer (Yamaguchi et al., 2008). However, it is important to note that the FOXA1 does not correlate with clinical outcome of patients with HER2-positive disease (Sircoulomb et al., 2010). Fourth, expression of FOXA1 has also been noted in ER-negative tumor, however, a prognostic and/or predictive role and mechanism for FOXA1 in ER-negative tumors is still unknown (Albergaria et al., 2009). Finally, Although FOXA1 has a dual role in breast cancer, but the potential mechanisms in breast cancer prognosis are still to explore further.

## Conclusions

Recent studies have identified FOXA1 is required for development of the mammary gland and disease. The prognostic value of FOXA1 for breast cancer has shown it to be correlated with a favorable clinical outcome, and thus aid in therapeutic decision-making. So FOXA1 is a reliable candidate prognostic biomarker in breast cancer. Further investigations concerning the regulatory mechanisms and function of FOXA1 in breast cancer will further help to elucidate the prognostic value.

## References

Ademuyiwa FO, Thorat MA, Jain RK, et al (2010). Expression of Forkhead-box protein A1, a marker of luminal A type breast cancer, parallels low Oncotype DX 21-gene recurrence scores. *Mod Pathol*, **23**, 270-5.

Albergaria A, Paredes J, Sousa B, et al (2009). Expression of FOXA1 and GATA-3 in breast cancer: the prognostic significance in hormone receptor-negative tumours. *Breast Cancer Res*, **11**, R40.

Badve S, Nakshatri H (2009). Oestrogen-receptor-positive breast cancer: towards bridging histopathological and molecular classifications. *J Clin Pathol*, **62**, 6-12.

Badve S, Turbin D, Thorat MA, et al (2007). FOXA1 expression in breast cancer--correlation with luminal subtype A and

survival. *Clin Cancer Res*, **13**, 4415-21.

Beck S, Sommer P, dos Santos Silva E, et al (1999). Hepatocyte nuclear factor 3 (winged helix domain) activates trefoil factor gene TFF1 through a binding motif adjacent to the TATAA box. *DNA Cell Biol*, **18**, 157-64.

Bernardo GM, Keri RA (2012). FOXA1: a transcription factor with parallel functions in development and cancer. *Biosci Rep*, **32**, 113-30.

Bernardo GM, Lozada KL, Miedler JD, et al (2010). FOXA1 is an essential determinant of ER $\alpha$  expression and mammary ductal morphogenesis. *Development*, **137**, 2045-54.

Carroll JS, Brown M (2006). Estrogen receptor target gene: an evolving concept. *Mol Endocrinol*, **20**, 1707-14.

Costa RH, Grayson DR, Darnell JE, et al (1989). Multiple hepatocyte-enriched nuclear factors function in the regulation of transthyretin and alpha 1-antitrypsin genes. *Mol Cell Biol*, **9**, 1415-25.

Desantis C, Ma J, Bryan L, et al (2013). Breast cancer statistics. *CA Cancer J Clin*, **9**, 69-90.

Goldhirsch A, Ingle JN, Gelber RD, et al (2009). Thresholds for therapies: highlights of the St Gallen International Expert Consensus on the primary therapy of early breast cancer 2009. *Ann Oncol*, **20**, 1319-29.

Habashy HO, Powe DG, Rakha EA, et al (2008). Forkhead-box A1 (FOXA1) expression in breast cancer and its prognostic significance. *Eur J Cancer*, **44**, 1541-51.

Hayes DF (2005). Prognostic and predictive factors revisited. *Breast*, **14**, 493-9.

Hisamatsu Y, Tokunaga E, Yamashita N, et al (2012). Impact of FOXA1 expression on the prognosis of patients with hormone receptor-positive breast cancer. *Ann Surg Oncol*, **19**, 1145-52.

Hurtado A, Holmes KA, Ross-Innes CS, et al (2011). FOXA1 is a key determinant of estrogen receptor function and endocrine response. *Nat Genet*, **43**, 27-33.

Ijichi N, Shigekawa T, Ikeda K, et al (2012). Association of double-positive FOXA1 and FOXP1 immunoreactivities with favorable prognosis of tamoxifen-treated breast cancer patients. *Horm Cancer*, **3**, 147-59.

Kawase M, Toyama T, Takahashi S, et al (2013). FOXA1 expression after neoadjuvant chemotherapy is a prognostic marker in estrogen receptor-positive breast cancer. *Breast Cancer*. [Epub ahead of print]

Kim C, Paik S 2010. Gene-expression-based prognostic assays for breast cancer. *Nat Rev Clin Oncol*, **7**, 340-7.

Knight WA, Osborne CK, Yochmowitz MG, et al (1980). Steroid hormone receptors in the management of human breast cancer. *Ann Clin Res*, **12**, 202-7.

Kouros-Mehr H, Storch EM, Sternlicht MD, et al (2006). GATA-3 maintains the differentiation of the luminal cell fate in the mammary gland. *Cell*, **127**, 1041-55.

Liu N, Niu Y, Wang SL, et al (2010). Diagnostic and prognostic significance of FOXA1 expression in molecular subtypes of breast invasive ductal carcinomas. *Zhonghua Yi Xue Za Zhi*, **90**, 1403-7.

Mehta RJ, Jain RK, Leung S, et al (2012). FOXA1 is an independent prognostic marker for ER-positive breast cancer. *Breast Cancer Res Treat*, **131**, 881-90.

Nakshatri H, Badve S (2007). FOXA1 as a therapeutic target for breast cancer. *Expert Opin Ther Targets*, **11**, 507-14.

Perou CM, Sorlie T, Eisen MB, et al (2000). Molecular portraits of human breast tumours. *Nature*, **406**, 747-52.

Sircoulomb F, Bekhouche I, Finetti P, et al (2010). Genome profiling of ERBB2-amplified breast cancers. *BMC Cancer*, **10**, 539.

Sorlie T, Perou CM, Tibshirani R, et al (2001). Gene expression

patterns of breast carcinomas distinguish tumor subclasses with clinical implications. *Proc Natl Acad Sci U S A*, **98**, 10869-10874.

Thorat MA, Marchio C, Morimiya A, et al (2007). Forkhead box A1 expression in breast cancer is associated with luminal subtype and good prognosis. *J Clin Pathol*, **61**, 327-32..

Wolf I, Bose S, Williamson EA, et al (2007). FOXA1: Growth inhibitor and a favorable prognostic factor in human breast cancer. *Int J Cancer*, **120**, 1013-22.

Yamaguchi N, Ito E, Azuma S, et al (2008). FoxA1 as a lineage-specific oncogene in luminal type breast cancer. *Biochem Biophys Res Commun*, **365**, 711-7.

Yerushalmi R, Woods R, Ravdin PM, et al (2010). Ki67 in breast cancer: prognostic and predictive potential. *Lancet Oncol*, **11**, 174-83.