

## Technical Note

# Microsurgical Excision of Symptomatic Sacral Perineurial Cyst with Sacral Recapping Laminectomy : A Case Report in Technical Aspects

Dae-Hyun Seo, M.D., Kyeong-Wook Yoon, M.D., Sang Koo Lee, M.D., Ph.D., Young-Jin Kim, M.D., Ph.D.

Department of Neurosurgery, Dankook University College of Medicine, Cheonan, Korea

Perineurial cysts (Tarlov cysts) are lesions of the nerve root that are often observed in the sacral area. There is debate about whether symptomatic perineurial cysts should be treated surgically. We presented three patients with symptomatic perineurial cyst who were treated surgically, and introduced sacral recapping laminectomy. Patients complained of low back pain and hypesthesia on lower extremities. We performed operations with sacral recapping technique for all three. The outcome measure was baseline visual analogue score and post operative follow up magnetic resonance images. All patients were completely relieved of symptoms after operation. Although not sufficient to address controversies, this small case series introduces successful use of a particular surgical technique to treat sacral perineurial cyst, with resolution of most symptoms and no sequelae.

**Key Words** : Tarlov cysts · Laminectomy.

## INTRODUCTION

The perineurial or Tarlov cysts are pathological entities found in the space between the perineurium and endoneurium of the posterior nerve root sheath of the root ganglion in lumbosacral lesion. They were first described by Tarlov during autopsy studies of the filum terminale<sup>1)</sup>. Since then, about 100 cases of symptomatic perineurial cysts have been reported in the literature<sup>2)</sup>. The development of magnetic resonance (MR) images has improved diagnostic ability to recognize perineurial cyst as a cause of sacral neurological dysfunction. Although the majority of perineurial cysts are asymptomatic, they are able to cause radiculopathy, urinary dysfunction, and perineal or sacrococcygeal pain<sup>3-7)</sup>. Although it is still a matter of debate whether patients with symptomatic perineurial cysts should be treated surgically, several authors recommend temporary or permanent lumbar cerebrospinal fluid drainage, laminectomy, microsurgical excision of symptomatic perineurial cysts or cyst fenestration and imbrication, and percutaneous fibrin glue instillation<sup>8-11,13,14)</sup>.

We describe three cases with a perineurial cyst treated suc-

cessfully with microsurgical excision and neck ligation of cyst originated from the left L5 nerve root, and introduce an operative method using sacral recapping laminectomy.

## CASE REPORT

### Case 1

This 61-year-old man presented with 2-year history of increasing lumbosacral pain and hypesthesia. On neurologic exam, he showed right L5 and S1 radiculopathy. His symptoms were aggravated by standing, walking, climbing, coughing and lifting, and relieved by sitting. The patient rated his pain 7 of 10 on the visual analogue score (VAS). He had bladder dysfunction and abnormal sensation for urination, and reported insertion of a Foley catheter 2 months ago. Preoperative MR imaging demonstrated 30×17×11 mm sized sacral cyst with another small cyst from L5 to S2 level (Fig. 1A). Myelogram and CT showed the contrast-filled bridge between the thecal sac and the cystic mass and sacral cyst causing compression of adjacent nerve roots (Fig. 1B, C). An L5 laminectomy and S1-3 en bloc laminectomy were performed. After careful dissection of the cyst wall, we ob-

• Received : February 4, 2013 • Revised : June 5, 2013 • Accepted : January 10, 2014

• Address for reprints : Young-Jin Kim, M.D., Ph.D.

Department of Neurosurgery, Dankook University College of Medicine, 201 Manghyang-ro, Cheonan 330-714, Korea  
Tel : +82-41-550-3979, Fax : +82-41-552-6870, E-mail : spine1225@naver.com

• This is an Open Access article distributed under the terms of the Creative Commons Attribution Non-Commercial License (<http://creativecommons.org/licenses/by-nc/3.0>) which permits unrestricted non-commercial use, distribution, and reproduction in any medium, provided the original work is properly cited.

served the superior surface of the cyst compressing S1 nerve root ventromedially and S2 nerve root dorsally (Fig. 1D). It was connected with a small cyst that was adhesive to right S2 and S3 nerve roots. The main cyst originated from inferomedial side of right L5 nerve root. The cyst was opened and its content appeared the same as the CSF content. We ligated the neck of the cyst and its wall was cut down away from the adjoining root sleeve. The sacral lamina was recapped at the back again with using heavy silk sutures (Fig. 1E). His lumbosacral pain and radiculopathy improved progressively after surgery. Postoperative two weeks, he removed the Foley catheter. Follow up MR imaging after 6 months demonstrated complete resolution of the cyst (Fig. 1F). At one year follow up, he had mild back pain (2 of 10 on the VAS).

### Case 2

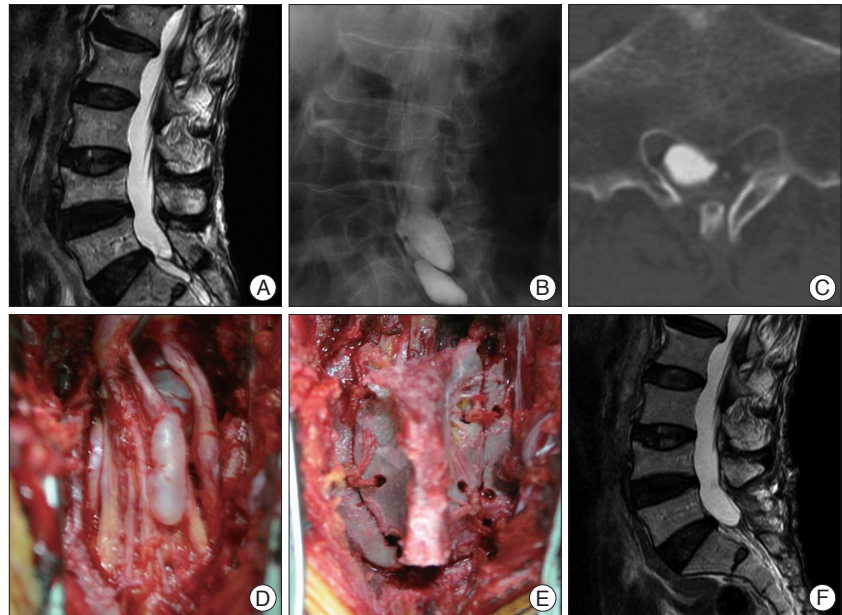
This 21-year-old man complained of worsening radiating pain and hypesthesia on left leg for 1 year. His motor weakness was grade 4 on left leg, especially when extending the left ankle. Because of worsening symptoms he eventually visited our department. He had mild claudication, positive on left straight leg raising test at 45 degree. We confirmed a mild left S1 radiculopathy on electromyography. He had no neurologic deficit associated with cauda equina syndrome. Preoperative MR imaging showed a 20×13×14 mm sized sacral cyst (Fig. 2A). We performed myelogram and CT and found the contrast-filled stalk between the thecal sac and the cyst. The cyst compressed a contiguous structure including nerve roots (Fig. 2B).

We performed surgery the same as patient 1 (Fig. 2D, E) and symptoms disappeared after one week. Follow up MR imaging after 2 months demonstrated complete resolution of the lesion. We checked with MR imaging after 1 year and ascertained that there was no further cystic formation and complication (Fig. 2C).

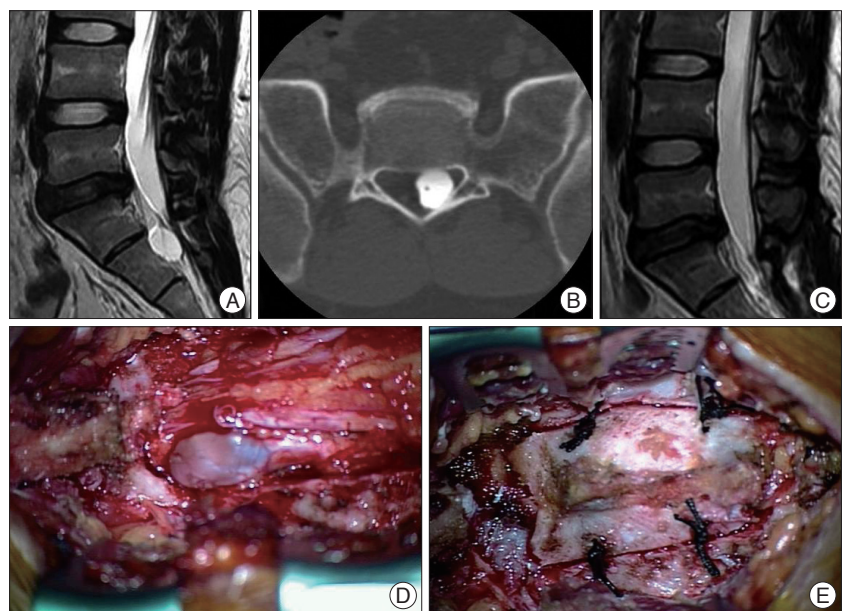
### Case 3

This 60-year-old female patient visited our department with 6-year history of

increasing lumbosacral pain and right leg radiculopathy. On neurologic examination, she complained right L5 and S1 radiculopathy. The patient rated her pain 9 of 10 on the VAS. She did not have bladder dysfunction. Preoperative MR imaging demon-

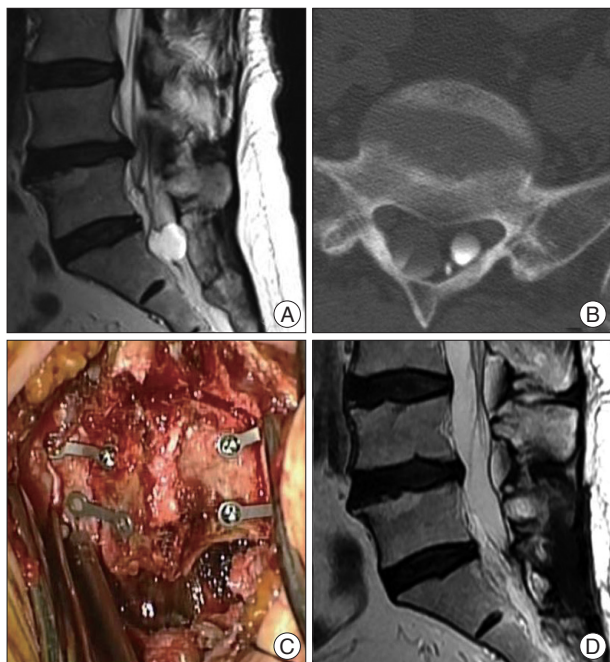


**Fig. 1.** Preoperative magnetic resonance (MR) T2-weighted image sagittal image (A) showing sacral cyst. Myelogram oblique view (B) and CT-myelogram (C) demonstrates that the cyst is divided into two segments and caused compression of adjacent nerve roots. Intraoperative photograph (D) shows that the large cyst below S1 nerve root is connected with small cyst through small stalk overlying S2 root. Photograph (E) after sacral recapping. Postoperative MR T2-weighted image sagittal image (F) obtained 6 months after surgery demonstrates complete excision of cyst.

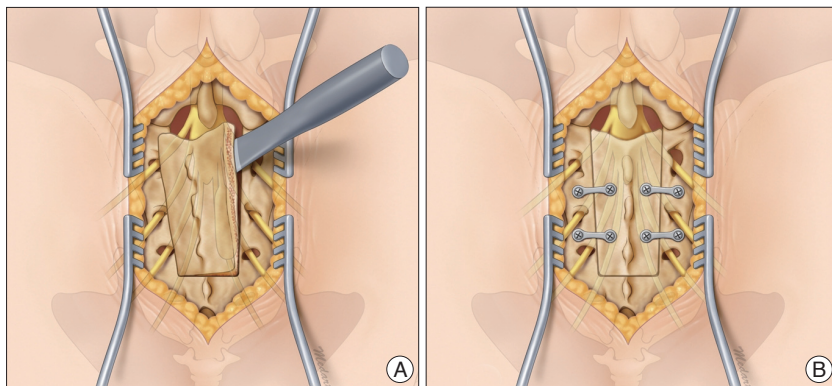


**Fig. 2.** Preoperative magnetic resonance (MR) T2-weighted image sagittal image showing sacral cyst (A). CT-myelogram (B) demonstrates that the cyst caused compression of adjacent nerve roots. Postoperative MR T2-weighted image sagittal image (C) obtained 1 year after surgery demonstrated complete excision of cyst. Intraoperative photograph (D) shows that the large cyst below S1 nerve root is connected with small cyst through small stalk overlying S2 root. Photograph (E) after sacral recapping.

strated 15×17×22 mm sized sacral cyst with S1 nerve root (Fig. 3A). Myelogram and CT showed the contrast-filled bridge between the thecal sac and the cystic mass, and sacral cyst causing compression of adjacent nerve roots (Fig. 3B). After careful dissection of the cyst wall, we observed the superior surface of the cyst. The main cyst originated from inferomedial side of right L5 nerve root. We performed surgery the same way but we used miniplate instead of silk for recapping (Fig. 3C). The symptoms improved progressively after surgery. MR imaging 4 months later demonstrated complete resolution of the cyst (Fig. 3D). At one year follow up, she had only mild back pain (3 of 10 on the VAS).



**Fig. 3.** Preoperative magnetic resonance (MR) T2-weighted image sagittal image (A) showing sacral cyst. CT-myelogram (B) demonstrates the cyst was filled with contrast media. Intraoperative photograph (C) shows after sacral recapping with miniplates. Postoperative MR T2-weighted image sagittal image (D) obtained 4 months after surgery demonstrated complete excision of cyst.



**Fig. 4.** The chiseling point of sacral lamina is approximately 3 mm medial to dorsal sacral foramina. Oblique chiseling is helpful when closing (A). The sacral laminae cap is closed using heavy silk 1/0 suture or miniplates (B).

### Technical note

Under general anesthesia, the patient was placed prone on the Wilson frame. A skin incision was made from L4 to S4. The related sacral laminae were wholly exposed. Sacral laminae cap was cut off using gentle chiseling. The chiseling point of sacral lamina is approximately 3 mm medial to dorsal sacral foramina. Oblique chiseling is helpful when closing. The line of chiseling was extended caudally to the involved sacral level. At this time, care should be taken to preserve the integrity of the underlying sacral nerve roots and perineurial cyst. Upon opening, the cyst was adhesive to the circumferential structures. It was softly dissected from adjoining root and surrounding tissues. Care must be taken to avoid injury of several nerve roots that lie along the dorsal and ventral aspects of the cyst wall. The cyst wall was cut down and its neck was ligated. The sutured area of the cyst was secured with an oxidized cellulose and glue combination. The sacral laminae cap was closed using heavy silk 1/0 suture or miniplates. A lumbar drain was established intraoperatively. The schematic picture is described in Fig. 4 to understand easily.

### DISCUSSION

Since Tarlov cyst was first described in 1938, it has been mainly reported for its clinical aspects, pathological mechanisms and operative methods<sup>1</sup>. Most Tarlov cysts are asymptomatic and do not require any treatment. However in a small minority, non-specific, variable clinical symptoms occasionally develop. Patients may complain of progressive pain in the lower back, sacrum, lower extremities, coccyx, rectum, and vagina, or penis<sup>2-8,10,11,13-15</sup>. It has been postulated that pressure on the adjacent sensitive tissue, such as the periosteum and the joint capsule, causes local back pain<sup>1,12</sup>. The patients with perineurial cyst can also experience other sensory disturbances such as hypesthesia or paresthesia over the buttocks, perineal area, and lower extremities<sup>3,5,8,14,15</sup>. Bladder incontinence, motor weakness, and impotence have also been documented<sup>3,5,12</sup>. Our patient complained of lumbosacral pain, hypesthesia and radiculopathy showing progressive bladder dysfunction and abnormal sensation upon urination. It was known that diverticula and small meningoceles are rarely symptomatic as their inner pressure equals the intra dural pressure because of the free communication with CSF<sup>10,14</sup>. On the other hand, a perineurial cyst can cause a significant mass effect even if relatively small. Their internal pressure being substantial, they can exert pressure on neural tissue as well as surrounding bone<sup>14</sup>.

The cause of sacral perineurial cysts is unknown, but several theories have been suggested. Tarlov<sup>16</sup> insisted that

sacral perineurial cysts occur because of breakage of venous drainage in the perineurium and epineurium secondary to hemosiderin deposition after trauma. Fortuna et al.<sup>6)</sup> considered sacral perineurial cysts to result from congenital arachnoidal proliferation along the exiting sacral nerve roots. Paulsen et al.<sup>14)</sup> proposed that the cysts enlarge due to a ball-valve effect, whereby CSF enters the cyst with systolic pulsation but disables to exit through the same entrance of the cyst during diastole. Congenital arachnoidal defect and valve mechanism of the cyst may play an important role in the pathogenesis of sacral perineurial cyst.

A variety of surgical techniques have been described to treat Tarlov cyst. In Tarlov's original article, he used either complete or partial excision of the cyst or incision and drainage without excision. Since this original article, several authors proposed microsurgical cyst excision, cyst fenestration and imbrications<sup>8,11,13,14)</sup>. More recently, a nonsurgical treatment with percutaneous CT-guided meningeal cyst aspirations is reported as a method of relieving symptoms<sup>10)</sup>. But, some opponents suggested that patients did not benefit from surgery because of recurrence of symptoms or surgical complications<sup>2,16)</sup>. Also, temporary lumbar drainage can reduce the symptom by shrinkage of sacral cyst, but the symptom would occur again after removal of drainage that is why the symptomatic sacral cyst should be surgically treated<sup>2)</sup>. Voyadzis et al.<sup>17)</sup> observed no relief of pain in his study and found that patients with Tarlov cysts greater than 1.5 cm and with associated radiculopathy or urogenic symptoms are able to profit from surgical treatment<sup>2)</sup>.

To our knowledge, sacral recapping laminectomy is first reported by Tanaka et al.<sup>15)</sup>. But it is difficult to reproduce this technique because they did not exactly describe the laminectomy method and the intraoperative photographs were dim black-and-white. In contrast to this, the present report demonstrates procedures in detail and step-by-step way. If there is no bony erosion, it may protect the sacral nerve roots and dural sac from external pressure, postoperatively. It may be also expected to protect neural tissue against severe adhesion with soft tissue. Furthermore, recapping prevents the adhesion problem, so revision surgery would be performed easily in case of recurrence.

## CONCLUSION

Perineurial cysts have become a common incidental findings during lumbosacral MR imaging. Only some of the symptomatic cysts require surgical treatment. We have described the suc-

cessful treatment of symptomatic perineurial cyst, and introduced sacral recapping laminectomy.

## References

1. Bartels RH, van Overbeeke JJ : Lumbar cerebrospinal fluid drainage for symptomatic sacral nerve root cysts : an adjuvant diagnostic procedure and/or alternative treatment? Technical case report. *Neurosurgery* **40** : 861-864; discussion 864-865, 1997
2. Caspar W, Papavero L, Nabhan A, Loew C, Ahlhelm F : Microsurgical excision of symptomatic sacral perineurial cysts: a study of 15 cases. *Surg Neurol* **59** : 101-105; discussion 105-106, 2003
3. Cattaneo L, Pavesi G, Mancina D : Sural nerve abnormalities in sacral perineurial (Tarlov) cysts. *J Neurol* **248** : 623-624, 2001
4. Dastur HM : The radiological appearances of spinal extradural arachnoid cysts. *J Neurol Neurosurg Psychiatry* **26** : 231-235, 1963
5. Davis DH, Wilkinson JT, Teaford AK, Smigiel MR : Sciatica produced by a sacral perineurial cyst. *Tex Med* **83** : 55-56, 1987
6. Fortuna A, La Torre E, Ciappetta P : Arachnoid diverticula: a unitary approach to spinal cysts communicating with the subarachnoid space. *Acta Neurochir (Wien)* **39** : 259-268, 1977
7. Hefti M, Landolt H : Presacral mass consisting of a meningocele and a Tarlov cyst: successful surgical treatment based on pathogenic hypothesis. *Acta Neurochir (Wien)* **148** : 479-483, 2006
8. Lim KT, Cho BM, Shin DI, Park SH, Oh SM. Symptomatic Tarlov's cyst (sacral meningeal cyst) : case report. *J Korean Neurosurg Soc* **29** : 569-573, 2000
9. Mummaneni PV, Pitts LH, McCormack BM, Corroo JM, Weinstein PR : Microsurgical treatment of symptomatic sacral Tarlov cysts. *Neurosurgery* **47** : 74-78; discussion 78-79, 2000
10. Nabors MW, Pait TG, Byrd EB, Karim NO, Davis DO, Kobrine AI, et al. : Updated assessment and current classification of spinal meningeal cysts. *J Neurosurg* **68** : 366-377, 1988
11. Nishiura I, Koyama T, Handa J : Intracanalicular perineurial cyst. *Surg Neurol* **23** : 265-269, 1985
12. North RB, Kidd DH, Wang H : Occult, bilateral anterior sacral and intracanalicular meningeal and perineurial cysts : case report and review of the literature. *Neurosurgery* **27** : 981-986, 1990
13. Patel MR, Louie W, Rachlin J : Percutaneous fibrin glue therapy of meningeal cysts of the sacral spine. *AJR Am J Roentgenol* **168** : 367-370, 1997
14. Paulsen RD, Call GA, Murtagh FR : Prevalence and percutaneous drainage of cysts of the sacral nerve root sheath (Tarlov cysts). *AJNR Am J Neuroradiol* **15** : 293-297; discussion 298-299, 1994
15. Tanaka M, Nakahara S, Ito Y, Nakanishi K, Sugimoto Y, Ikuma H, et al. : Surgical results of sacral perineurial (Tarlov) cysts. *Acta Med Okayama* **60** : 65-70, 2006
16. Tarlov IM : Perineurial cysts of the spinal nerve roots. *Arch Neurol Psychiatry* **40** : 1067-1074, 1938
17. Voyadzis JM, Bhargava B, Henderson FC : Tarlov cysts: a study of 10 cases with review of the literature. *J Neurosurg* **95** (1 suppl) : 25-32, 2001