

# Osteochondritis Dissecans in Medial Trochlea of the Humerus in a Pitcher - A Case Report

Jin-Ho Lee, Myung-Sun Kim

Department of Orthopaedic Surgery, Chonnam National University College of Medicine, Gwangju, Korea

Osteochondritis dissecans (OCD) is an idiopathic condition affecting the articular epiphysis. Initially described in the knee, this entity affects several other parts of the body such as the talar dome, tarsal navicular, and femoral capital epiphysis. Osteochondritis dissecans (OCD) of the elbow is typically located in the capitellum of the humerus in young teenagers. OCD of humeral trochlea is very rare, but can be occurred among young athletes. OCD developed medial trochlea was extremely rare, especially, without any other trauma. We present a patient, pitcher with OCD in the medial trochlea of the humerus who underwent arthroscopic debridement and microfracture. (Clin Shoulder Elb 2014;17(1):40-43)

**Key Words:** Osteochondritis dissecans; Pitcher; Medial trochlea; Arthroscopic debridement; Microfracture

## Introduction

Osteochondritis dissecans (OCD) of the humeral capitellum is a common sports-related disorder in young athletes, especially baseball players and gymnasts. OCD of the elbow primarily involves the capitellum. OCD of humeral trochlea is very rare, but can occur among young athletes. There are a few case reports OCD in the lateral trochlea,<sup>1)</sup> but in this case, we can see OCD lesion in medial trochlea.

To our knowledge, no such patient has previously been reported in our country. The ideal goal of treatment for OCD lesions is to resurface the lesion and to prevent the osteoarthritis. We present a patient with OCD in medial trochlea of the humerus who underwent arthroscopic debridement and microfracture.

## Case Report

A 14-year-old boy had been a left-handed baseball pitcher for 6 years and dominant was left. He was a pitcher or first base-

man for 6 years and was overhand thrower. He threw the ball about 200 times a day as a pitcher. The pattern of his pitching during a game included fast balls (60%), curve balls (30%) and sliders (10%). He had been trained fast balls at first and had learned curve balls 4 years ago and sliders 1 year ago.

He complained of pain in the left elbow without any evident trauma, three years ago. At that time, he was treated by extracorporeal shock wave therapy (ESWT) once in a week for 5 weeks at the other hospital. The pain was occurred in the medial aspect of the elbow at the terminal phase of throwing, but not in daily life activity.

He got conservative treatment (ESWT, Physical therapy et al.) but did not improve symptom.

Even the pain was getting worse in the evening than in the morning.

On physical examination, Range of motion of the left elbow was -10° in extension and 130° in flexion; on the right elbow it was 0° in extension and 150° in flexion. Tenderness was observed around the medial epicondyle of humerus. But, Joint motion was smooth, with no mechanical symptoms such as locking

**Received** October 24, 2013. **Revised** January 20, 2014. **Accepted** March 12, 2014.

**Correspondence to:** Myung-Sun Kim

Department of Orthopaedic Surgery, Chonnam National University College of Medicine, 42 Jebongro, Dong-gu, Gwangju, 42 Jebongro, Donggu, Gwangju, 501-757, Korea

**Tel:** +82-62-220-6336, **Fax:** +82-62-225-7794, **E-mail:** mskim@jnu.ac.kr

**Financial support:** None. **Conflict of interests:** None.

or catching.

Radiographs (Fig. 1) revealed a radiolucent lesion in the

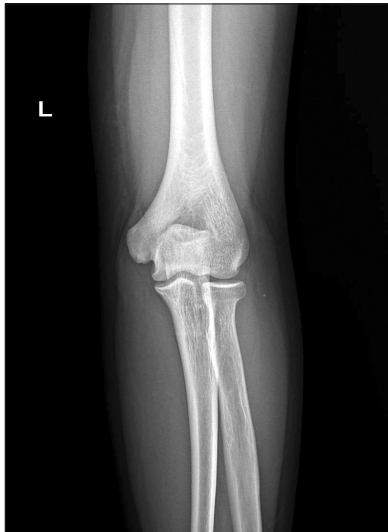

Fig. 1. Lucencies of trochlea OCD demonstrated on plain radiograph.

trochlear groove, which was confirmed by computed tomography scanning (Fig. 2). Magnetic resonance imaging (Fig. 3) revealed an 7 mm sized osteochondral defect involving the medial aspect of the trochlea. No loose bodies or significant joint effusion were evident.

Elbow arthroscopy revealed complete discontinuity of a 5 x 5 mm sized osteochondral fragment from the posterior medial area of the trochlea, which was classified as an International Cartilage Research Society (ICRS) OCD III lesion (Fig. 4).

Also, severe synovitis in elbow joint and plica of posterior lateral corner of the trochlea were observed. So arthroscopic synovectomy and plica resection were performed. After curetting both the crater and the facing side of the osteochondral fragment, microfractured for marrow cell stimulation (Fig. 5). Tourniquet was deflated and we confirmed bleeding from the microfractured site.

After immobilization with a long arm splint at 90° of elbow flexion for 2 weeks postoperatively, active ROM exercise was recommended. Histologic findings showed that the fragment was osteocartilagenous tissue.

At 3 months after surgery the patient had regained full range

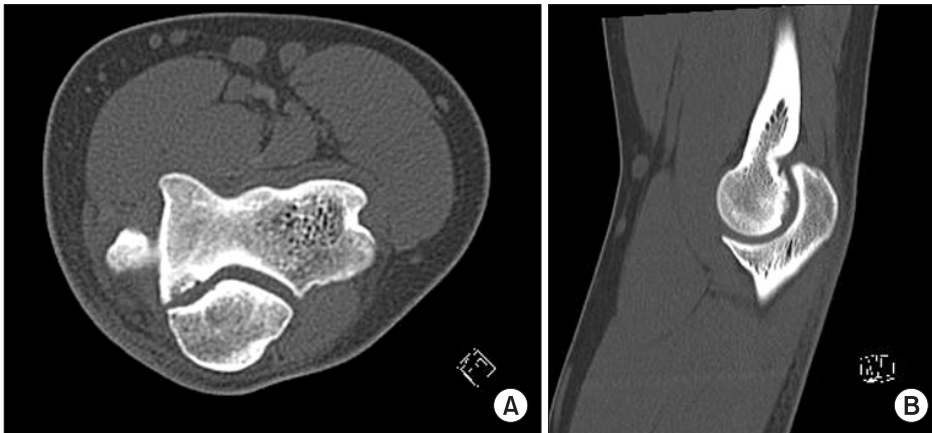


Fig. 2. Computed tomography scan of left elbow showing radiolucent lesion in trochlea. (A) Axial reconstruction of noncontrast CT scan of the elbow demonstrates an osseous defect. (B) OCD lesion of the medial trochlea is located between two and five o'clock position as seen on sagittal image.

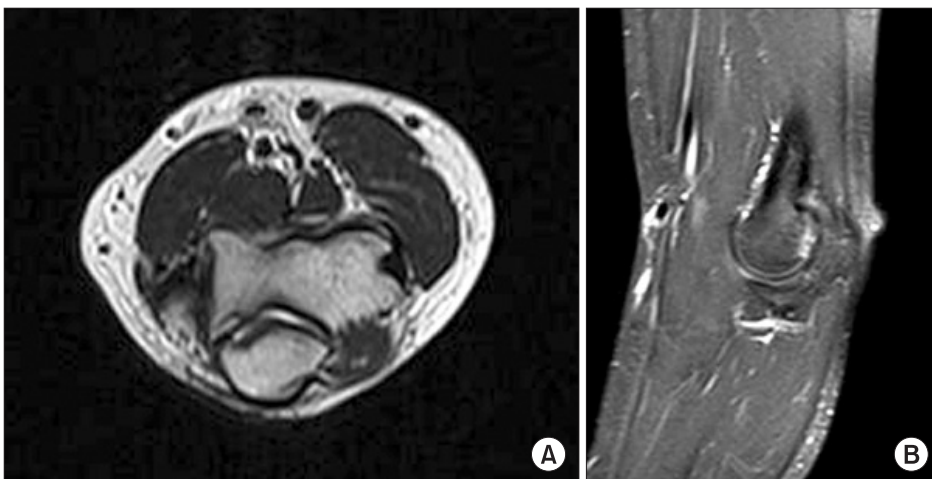

Fig. 3. Fourteen-year-old male baseball pitcher with 5mm sized osteochondral lesion of the posteromedial trochlea. (A) Axial. (B) Sagittal view.

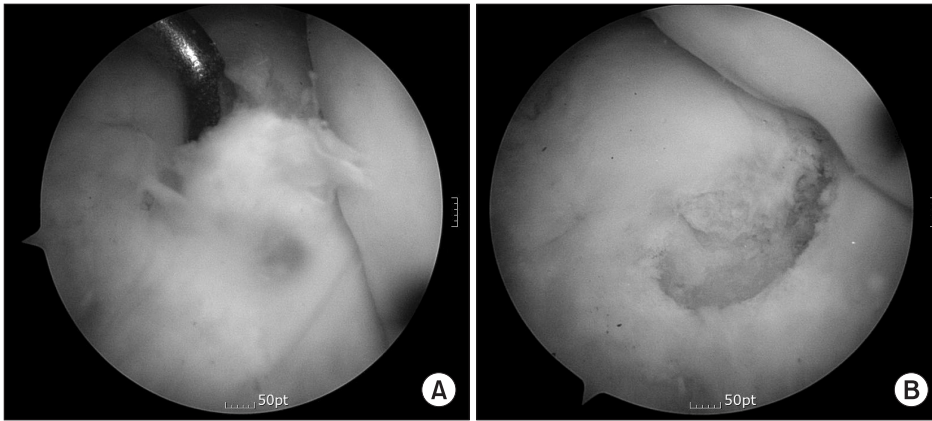


Fig. 4. (A) demonstrate hyaline cartilaginous dimpling over the lesion of the OCD, (B) is probed, debrided.

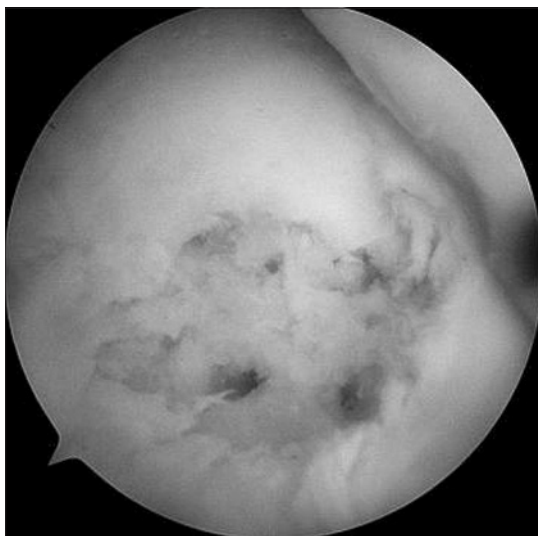


Fig. 5. The lesion subsequently microfractured to promote marrow cell stimulated healing.

of motion compared with the other side. He has been asymptomatic until now. So he returned to the baseball rehabilitation program. At 5 months after surgery, follow up MRI (Fig. 6) showed formation of granulation tissue and fibrocartilage at operation site of osteochondritis dissecans of trochlea. Now he can do power pitching.

## Discussion

The trochlear lesions are uncommon cause of pediatric athlete elbow pain.

The submission was reported at the 2008 annual meeting of the American Academy of Orthopaedic Surgeons, Matsuura et al. reported a cohort of 1,802 Japanese baseball players ranging in age from 8 to 12 years old trochlear lesions that were showed on the X-ray finding accounted for for 0.5% of osteochondral lesions in this cohort.

Trochlear OCD can affect the lateral trochlea (lateral type)<sup>1)</sup>

or the medial trochlea (medial type).<sup>2,3)</sup> Previous studies have suggested that the medial-type lesion could result from varus mechanical stress after traumatic varus deformity.<sup>2,3)</sup> But, our case had not a traumatic event. Only we assumed that the lesion related the posture of baseball pitcher with throwing curve and slider balls.

Marshall et al.<sup>2)</sup> reported 13 cases of OCD in humeral trochlea. 10 cases of them were large lateral lesions and 3 cases were small medial lesions. The lateral-type lesion occurs in a characteristic vascular watershed zone resulting from the unique blood supply of the trochlea, that is, the posteroinferior portion. Miyake et al.<sup>4)</sup> studied 3D biomechanical analysis of osteochondritis dissecans of humeral trochlea. They reported that a defect in the posteroinferior portion of the lateral trochlea, which is the usual location of lateral-type trochlear OCD, did not affect elbow biomechanics and function. They reported that conservative treatment is a reasonable treatment for a stable OCD lesion involving the lateral trochlea. But they did not recommend for the medial trochlea.

Lyman et al.<sup>5)</sup> studied the effect of pitch type on risk of elbow and shoulder pain in youth baseball pitchers. They reported that throwing a slider ball was associated with an 86% increased risk of elbow pain, although throwing curveball caused increased risk of shoulder pain. And this relationship was especially strong among 13- to 14-year-old pitchers.

Werner et al.<sup>6)</sup> reported that elbow flexion at stride-foot contact was greater in left-handed pitchers than in right-handed. So much stress was concentrated to elbow during the pitching motion.

Momma et al.<sup>7)</sup> studied about the distribution pattern of subchondral bone density through the articular surface between nonthrowing athletes and baseball pitchers. They revealed that the maximum density area of the subchondral bone is increased significantly in the humerus (especially, posteromedial trochlea and anterolateral capitellum) in the baseball pitchers.

In this case, the patient is a 14-year-old left-handed pitcher and who had a OCD lesion in medial trochlea. Repetitive stress

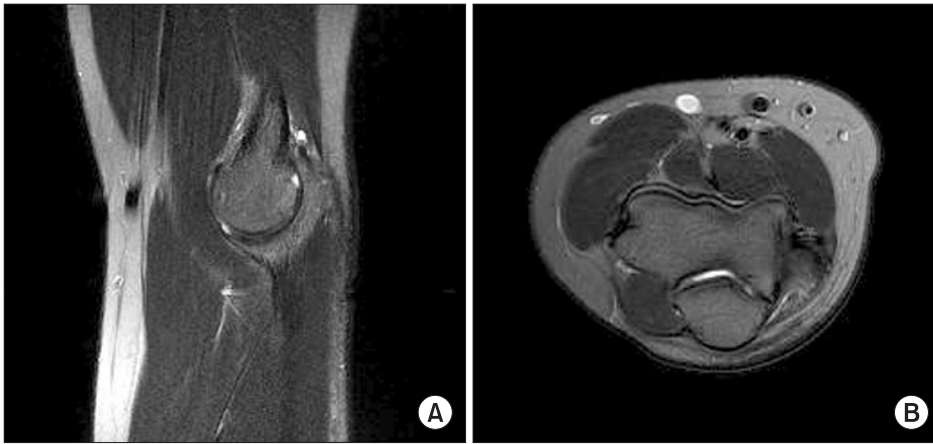


Fig. 6. MRI showed formation of granulation tissue and fibrocartilage at operation site of osteochondritis dissecans of trochlea. (A) Axial. (B) Sagittal view.

on medial trochlea during the pitching may be the cause of OCD lesion.

### Conclusion

Trochlear OCD is extremely rare, especially in medial aspect without any trauma that caused cubitus varus force. But the stress on the medial trochlear aspect was increased left-handed youth baseball pitcher throwing curve or slider balls. So the OCD lesion can be developed in the medial trochlea. We treated arthroscopic microfracture, gained good result at 5 months follow-up.

### References

1. Iwasaki N, Yamane S, Ishikawa J, Majima T, Minami A. Osteochondritis dissecans involving the trochlea of the humerus treated with transplantation of tissue-engineered cartilage: a case report. *J Shoulder Elbow Surg.* 2008;17(5):e22-5.
2. Marshall KW, Marshall DL, Busch MT, Williams JP. Osteochondral lesions of the humeral trochlea in the young athlete. *Skeletal Radiol.* 2009;38(5):479-91.
3. Namba J, Shimada K, Akita S. Osteochondritis dissecans of the humeral trochlea with cubitus varus deformity. A case report. *Acta Orthop Belg.* 2009;75(2):265-9.
4. Miyake J, Kataoka T, Murase T, Yoshikawa H. In-vivo biomechanical analysis of osteochondritis dissecans of the humeral trochlea: a case report. *J Pediatr Orthop B.* 2013;22(4):392-6.
5. Lyman S, Fleisig GS, Andrews JR, Osinski ED. Effect of pitch type, pitch count, and pitching mechanics on risk of elbow and shoulder pain in youth baseball pitchers. *Am J Sports Med.* 2002;30(4):463-8.
6. Werner SL, Guido JA, Delude NA, Stewart GW, Greenfield JH, Meister K. Throwing arm dominance in collegiate baseball pitching: a biomechanical study. *Am J Sports Med.* 2010;38(8):1606-10.
7. Momma D, Iwasaki N, Oizumi N, et al. Alterations in stress distribution patterns through the forearm joint surface of the elbow in baseball players assessed using computed tomography osteoabsorptiometry. *J Orthop Sci.* 2012;17(3):253-60.