

Case Report

Management of Idiopathic Interstitial Pneumonia Treated only with Traditional Korean Medicine: a Case Report

Ji-Young Kang¹, Jong-Min Han¹, Jun-Young Kim¹, In-Chul Jung²,
Wee-chang Kang³, Young-Seon Oh⁴, Jin-Woo Lee⁴, Yang-Chun Park¹

¹Department of Internal Medicine, College of Korean Medicine, Daejeon University

²Department of Neuropsychiatry, College of Korean Medicine, Daejeon University

³Department of Business Information Statistics, College of Business Administration, Daejeon University

⁴Hyehwa Hospital, Daejeon University

Objectives: To present the case of a 76-year-old man diagnosed with idiopathic interstitial pneumonias (IIPs) treated exclusively with traditional Korean medicine (TKM).

Methods: The patient was treated with the revised *Sasammaekmundong-tang* (rSMT), acupuncture, and pharmacopuncture from September 2013 to May 2014 in our outpatient clinic. We prescribed rSMT three times a day for 4 months. Acupuncture and pharmacopuncture were performed twice a week for 9 months. To evaluate therapeutic efficacy, we recorded the patient's chief complaints at each visit, and pulmonary function test was performed at intervals of three months. Chest radiography and chest computed tomography were performed before and after treatment, respectively.

Results: During the course of the treatment, dyspnea, cough, sputum, and overall pulmonary function improved.

Conclusions: We suggest that traditional Korean medicine (TKM) for IIPs patients might be effective in the control of the main symptoms of IIPs and in the recovery of respiratory function.

Key Words : idiopathic interstitial pneumonias (IIPs), idopathic pulmonary fibrosis (IPF), traditional Korean medicine (TKM), revised *Sasammaekmundong-tang*

Introduction

Idiopathic interstitial pneumonias (IIPs) are a heterogeneous group of diffuse parenchymal lung diseases, also known as interstitial lung diseases.¹⁾ IIPs can be classified as chronic fibrosing interstitial pneumonia (IP), smoking-related IP, and acute/subacute IP. Chronic fibrosing IP includes idiopathic pulmonary fibrosis (IPF) and idiopathic nonspecific interstitial pneumonia (NSIP).²⁾ So far, there is no specific treatment for IPF, which has shorter survival

than other IIPs.³⁾ The prognosis of idiopathic NSIP varies from individual to individual; some evolve to end-stage fibrosis and even death. Differentiation of NSIP from IPF is very important because the two subtypes have different treatment and prognosis. Histologically, IPF is characterized by the presence of honeycombing and subpleural distribution; NSIP is characterized by peribronchovascular distribution, wide areas of ground-glass attenuation, and subpleural sparing.⁴⁻⁶⁾

In traditional Korean medicine (TKM), IIPs may

• Received : 10 November 2014 • Revised : 10 December 2014 • Accepted : 10 December 2014
• Correspondence to : Yang-Chun Park
Department of Internal Medicine, Daejeon Korean Medicine Hospital of Daejeon University
301-724, 22-5 Daehung-ro 176-9, Jung-gu, Daejeon South Korea
Tel : +82-42-229-6919, Fax : +82-42-254-3403, E-mail : omdpyc@dju.kr

be defined by a combination of diseases. These include dyspnea (喘證), dry cough (乾嗽), lung consumption (肺癆), and lung atrophy (肺痿). The pattern identifications on IIPs are as follows: lung *qi* deficiency syndrome (肺氣虛證), syndrome of dual deficiency of *qi* and *yin* (氣陰兩虛證), syndrome of stagnant of *qi*-blood (氣血凝滯證), syndrome of dual deficiency of *yang* and *yin* (陰陽俱虛證).⁷⁾

Several researchers have investigated the benefits of herbal medicines for interstitial lung disease in Korea.⁸⁻¹⁴⁾ In addition, Son *et al.* reported on a patient with IIPs who was treated with *Taeumjowi-tang* and *Bopae-tang*.¹⁵⁾

However, there are not many clinical reports on IIPs with TKM so far.

Here, we present the case of a 76-year-old man diagnosed with IIPs who showed improved respiratory function after being treated exclusively with TKM.

Case Report

In September 2013, a 76-year-old man was admitted to our outpatient clinic because of dyspnea, cough, and sputum persisting for 3 months. He was previously diagnosed with IPF or NSIP by chest computed tomography (CT) at the local university hospital in July 2013. After the diagnosis, he was recommended further histological examination and steroid treatment. The patient refused treatment, but agreed to receiving TKM alone. He had been diagnosed with hypertension and diabetes mellitus (20 years prior), ischemic heart disease (4 years prior) and Parkinson's disease (2 years prior), and had taken oral medications related to the above-mentioned diseases (*irbesartan*, *nicorandil*, *isosorbide mononitrate*, *Aspirin*, *clopidogrel*, *rosuvastatin*, *sitagliptin/metformin* and *Stalevo*). In addition, he was an ex-smoker (had smoked for 40 years). On the first visit to our outpatient clinic, the patient's vital signs were as follows: blood pressure,

110/70 mmHg; pulse rate, 80 beats per minute; and respiratory rate, 20 breaths per minute. Chest auscultation revealed inspiratory crackles in both lower lung fields and no cardiac murmur was noted. Abdominal examination was unremarkable. The patient's laboratory test results were as follows: hemoglobin, 13.5 g/dL; white blood cell count, 5,200 cells/ μ L; platelet count, 178,000 cells/ μ L; and erythrocyte sedimentation rate, 13 mm/h; all other blood parameters were within normal range. Chest X-ray (PA) and chest CT showed multifocal fibrosis, honeycomb, and air-space consolidation with ground-glass opacity (GGO) bilaterally in subpleural regions and the lower pulmonary lobes (Fig.1A and 1B).

Pulmonary function tests showed mild restrictive patterns with the following results: forced vital capacity (FVC), 66% of the predicted value (2.24 L); forced expiratory volume in 1 s (FEV₁), 65% of the predicted value (1.70 L); and FEV₁/FVC ratio, 0.73.

The tongue of the patient was red with dry fur and the pulse was fine/rapid. In the pattern identification, the patient was finally diagnosed as lung-stomach *yin* deficiency. Based on this diagnosis, we prescribed the revised *Sasammaekmundong-tang* (rSMT) three times a day to strengthen lung *qi* and enhance the respiratory function.

The composition of rSMT was as follows: 12 g each of *Radix Codonopsis* and *Liriopsis Tuber*; 8 g each of *Polygonati Odorati Rhizoma*, *Radix Stemonae* and *Morus Alba*; 6 g each of *Trichosanthes Kirilowii* and *Dolichoris Semen*; 4 g each of *Radix Glycyrrhizae*, *Radix Ginseng* and *Farfarae Flos*; and 2 g each of *Radix Asteris Radix* and *Fructus Schizandrae*.

The patient also underwent acupuncture and pharmacopuncture treatment twice per week for 4 months, and then once a week for another 5 months. The main acupoints were selected as per TKM theory: LI4 (合谷), LU10 (魚際), LU7 (列缺), K3 (太溪) and SP6 (三陰交). We used disposable

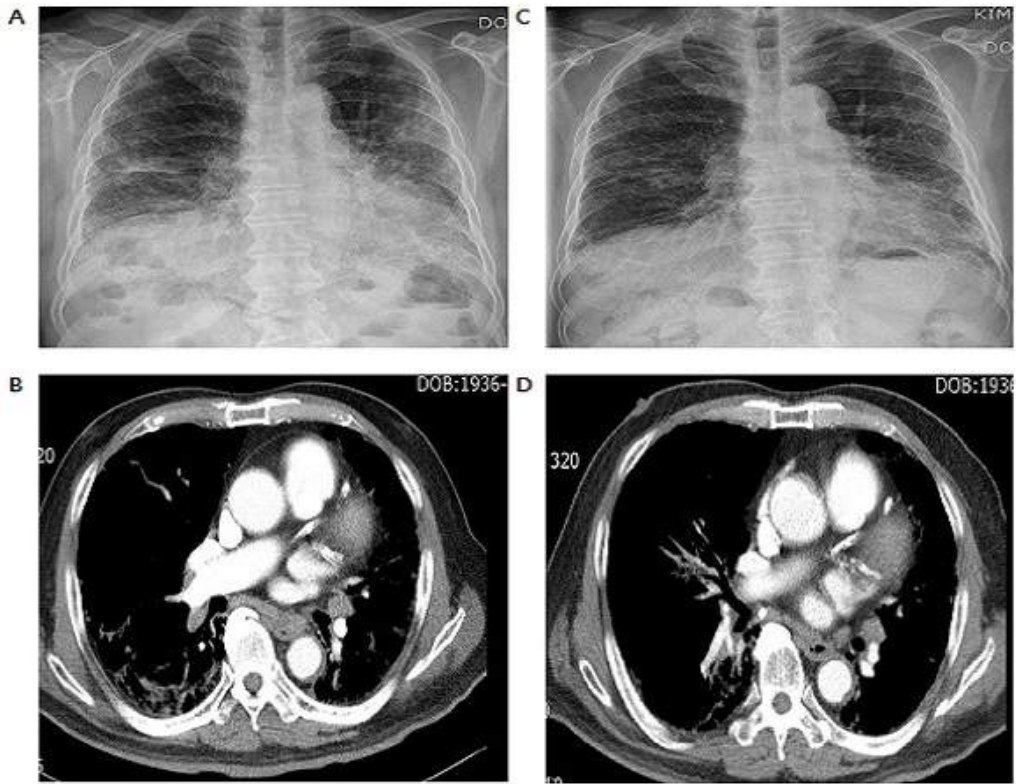


Fig. 1. Chest X-ray (PA) and chest CT in the case

Fig.1A, 1B: Initial Chest CT scan and chest X-ray (PA) showed multifocal fibrosis, honeycomb and air-space consolidation with ground glass opacity (GGO) at bilateral subpleural and lower lungs. (July, 2013)

Fig.1C, 1D: Chest CT scan and chest X-ray (PA) obtained at 8 months follow-up showed improvement of acute process of interstitial pneumonia. But comparing with July 2013 CT, there was no change in multifocal fibrosis and honeycomb at bilateral subpleural and lower lungs. (April, 2014)

stainless-steel needles (0.25 × 30 mm; Dong Bang Acupuncture Co., Korea). Each acupuncture session took 20 min. The type of pharmacopuncture was the hominis placenta pharmacopuncture (HPP; self-prepared in our clinic); 0.1 cc was injected per acupoint for a total of 0.5 cc. Acupoints for pharmacopuncture treatment were CV22 (天突), BL13 (肺俞) and 定喘 (extra point, 0.5 cm lateral to GV14).

Two weeks after initiation of treatment, symptoms such as dyspnea and sputum gradually resolved. Therefore, the herbal medicine prescription was maintained. Two months later, dyspnea had improved

notably. Symptoms such as cough and sputum disappeared four months after administration of rSMT. Hence, we discontinued the herbal medicine, and reduced the acupuncture and pharmacopuncture treatment to once a week.

On April 19, 2014, chest radiograph showed an improvement of the acute process of interstitial pneumonia. However, compared with the results of chest CT of the previous year, there was no change in multifocal fibrosis and honeycomb in bilateral subpleural regions and the lower pulmonary lobes (Fig. 1C and 1D).

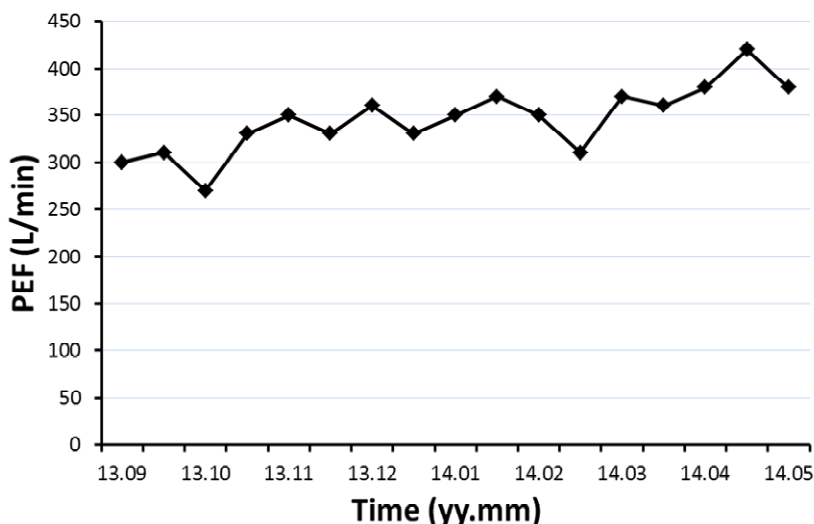


Fig. 2. Change of peak expiratory flow rate

After 9 months of treatment, FEV₁ and FEV₂ increased by 10% and 8%, respectively. The peak expiratory flow (PEF) was increased from 300 L/min to 380 L/min (Table 1 and Fig. 2).

Discussion

According to the 2008 Korean national survey of

IIPs, the most frequent subtype was IPF (77.1%), followed by NSIP (11.9%). The 3-year survival rate was 62% for IPF patients; the 5-year survival rate was 85% for NSIP patients.¹⁶⁾

IPF most commonly appears between the fifth and seventh decades of life, with two-thirds of all cases arising in patients over 60 years of age.²⁾ The mean age at presentation is 66 years. IPF occurs

Table 1. Changes of treatment, symptoms and spirometry values in the case

	Sep. 2013	Nov. 2013	Jan. 2014	Mar. 2014	May. 2014
Herb Medicine	rSMT*	rSMT	—	—	—
Acupuncture Tx. [†]	+	+	+	+	+
Pharmacopuncture Tx. [#]	+	+	+	+	+
mMRC dyspnea index**	2	1	1	1	1
Spirometry	FEV ₁ , L(%) [†]	1.70 (65)			1.96 (75)
	FVC, L(%) [†]	2.24 (66)			2.54 (74)
	FEV ₁ /FVC, %	76			77

* rSMT: Revised Sasammaekmundong-tang

[†] Acupuncture Tx.: LI4, LU10, LU7, K3, SP6

[#] Pharmacopuncture Tx.: Hominis placenta pharmacopuncture at BL13, Jeongcheon (extra point, 0.5 cun lateral to GV14), CV22.

** mMRC dyspnea index: Modified medical research council dyspnea index, simple grading system to assess a patient's level of dyspnea.

[†] FEV₁: Forced expiratory volume in 1 second.

[†] FVC: Forced vital capacity.

infrequently in those younger than 40 and rarely affects children, if at all.¹⁷⁾ A typical chest CT of IPF is characterized by patchy, predominantly peripheral, predominantly subpleural, bibasilar reticular opacification. In contrast, NSIP is characterized by homogeneously thickened interstitial spaces that contain accumulated fibrosis and inflammation.¹⁸⁾ NSIP occurs mainly in middle-aged adults. The average age at onset is 49 years, although individuals at both extremes of life can be affected. Unlike IPF, NSIP may occur in children. In Katzenstein and Fiorelli's study,⁵⁾ 45% of patients recovered completely, and 42% remained stable or improved; the median survival was greater than 13 years. The prognosis of NSIP is variable but generally good, with a positive response to steroids in most patients compared with IPF. Compared with NSIP, IPF is typically progressive and leads to significant disability. The median survival is 2 to 5 years from the time of diagnosis.^{19,20)} Our patient could be diagnosed as IPF based on the radiological and epidemiological features of IPF.

Medical therapy is ineffective in the treatment of IPF. New molecular therapeutic targets have been identified and several clinical trials are being conducted. Meanwhile, pulmonary transplantation remains a viable option for patients with IPF.

Unlike Western medicine, there is no specific term or definition that refers to the current understanding of IIPs in TKM. However, the clinical features of idiopathic interstitial lung disease share similarities with dyspnea (喘證), dry cough (乾嗽), lung consumption (肺癆), and lung atrophy (肺痿).⁷⁾

Our patient was diagnosed with lung-stomach *yin* deficiency based on the TKM theory. Therefore, we decided to administer rSMT. *Sasammaekmundong-tang* has long been used to treat respiratory disease in Korea. It is recommended for patients who have a differential diagnosis of lung deficiency and lung *qi* and *yin* dual vacuity.

We added some herbs such as *Radix Ginseng*,

Fructus Schizandrae, *Radix Stemonae*, *Radix Asteris* and *Farfarae Flosin* to the original formula.

In addition, acupuncture and pharmacopuncture were performed as complementary treatments. 9 months after treatment with TKM, the patient's symptoms (cough, dyspnea and sputum) and respiratory function improved (Table 1).

However, conclusions should be drawn within the limitations of this single-case report. The diagnosis of IPF was not confirmed because lung biopsy was not performed. It is possible that this was actually a case of NSIP, which is known for having a good prognosis. Nevertheless, the improvement of respiratory function after such short TKM treatment is remarkable.

In conclusion, this case gives us some evidence that TKM offers beneficial effects (from an approach aimed at relieving symptoms) for patients with IIPs and *Sasammaekmundong-tang* used mainly in this case is as an effective regimen for IIPs.

Further studies are required to demonstrate the efficacy of TKM on interstitial lung diseases.

Acknowledgements

This study was supported by research funds of Daejeon University.

References

1. Kim DS. Idiopathic interstitial pneumonia. In: Respiratory Diseases. Seoul:Koonja publishing. 2004:457-68.
2. Travis WD, Costabel U, Hansell DM, King TE Jr, Lynch DA, Nicholson AG, et al. ATS/ERS Committee on Idiopathic Interstitial Pneumonias. An official American Thoracic Society/European Respiratory Society statement: Update of the international multidisciplinary classification of the idiopathic interstitial pneumonias. Am J

- Respir Crit Care Med. 2013;188(6):733-48.
3. Kim DS. Diagnostic approaches to diffuse interstitial lung diseases. J Korean Med Assoc. 2009;52(1):5-13.
 4. Katzenstein, AL, Myers JL. Idiopathic pulmonary fibrosis: clinical relevance of pathologic classification. Am J Respir Crit Care Med. 1998;157(4):1301-15.
 5. Katzenstein AL, Fiorelli RF. Nonspecific interstitial pneumonia/fibrosis. Histologic features and clinical significance. Am J Surg Pathol. 1994;18:136-47
 6. Park IN, Jegal Y, Kim DS, Do KH, Yoo B, Shim TS, et al. Clinical course and lung function change of idiopathic nonspecific interstitial pneumonia. Eur Respir J. 2009;33:68-76.
 7. Korean Medicine College Respiratory faculty. Respiratory Medicine. Seoul:Nado publishing. 2011:570-86.
 8. Lee JS, Jung HJ, Jung SK, Rhee HG. The effects of *Lonicerae Flos* on bleomycin-induced lung fibrosis. J Korean Orient Int Med. 2004;25(1):71-80.
 9. Rhu HC, Rhee HG, Jung SK, Jung HJ. The effect of *Rehmanniae Radix* on bleomycin-induced Lung Fibrosis. J Korean Orient Int Med. 2004;25(2):298-306.
 10. Lee BS, Rhee HK, Jung SK, Jung HJ. The inhibitory effects of *Liriopsis tuber* on the bleomycin-induced lung fibrosis in C75BL/6J mice. J Korean Orient Int Med. 2004;25(4): 93-104.
 11. Lee KS, Rhee HK, Jung SK, Jung HJ. The effects of *Fritillariae Rhizoma* on bleomycin-induced lung Fibrosis. J Korean Orient Int Med. 2005; 26(1):169-81.
 12. Kim HJ, Lee HJ, Park EJ. The effects of *Peucedani Radix* on the bleomycin-induced lung fibrosis. J Korean Orient Ped. 2008;22(2):37-49.
 13. Lee HJ. The effects of *Okwada* on the lung fibrosis mouse model. J Korean Orient Ped. 2009;23(3):233-40.
 14. Lee HJ, Shin GS, Ahn JS. The preliminary study for therapeutic mechanism of *Gamibojungikgi-tang* and *Gamijwagwi-eum* for pulmonary fibrosis. J Korean Orient Ped. 2010;24(1):126-133.
 15. Son JY, Yi CG, Park MY, Choi HY, Kim JD. A Clinical case report of diffuse interstitial lung disease. J East-west med. 2008;33(4):47-54.
 16. Scientific Committee of the Korean Academy of Tuberculosis and Respiratory Diseases. 2008 national survey of idiopathic interstitial pneumonia in Korea. Tuberc Respir Dis. 2009;66(2):141-151.
 17. Coultas DB, Zumwalt RE, Black WC, Sobonya RE. The epidemiology of interstitial lung diseases. Am J Respir Crit Care Med. 1994;150:967-972.
 18. Bjoraker JA, Ryu JH, Edwin MK, Myers JL, Tazelaar HD, Schroeder DR, et al. Prognostic significance of histopathologic subsets in idiopathic pulmonary fibrosis. Am J Respir Crit Care Med. 1998;157:199-203.
 19. Collard HR, King TE Jr, Bartelson BB, Vourlekis JS, Schwarz MI, Brown KK. Changes in clinical and physiologic variables predict survival in idiopathic pulmonary fibrosis. Am J Respir Crit Care Med. 2003;168:538-542.
 20. Flaherty KR, Mumford JA, Murray S, Kazerooni EA, Gross BH, Colby TV, et al. Prognostic implications of physiologic and radiographic changes in idiopathic interstitial pneumonia. Am J Respir Crit Care Med. 2003;168:543-548.