

하대정맥 손상후 일차봉합술로 인해 발생한 버드-키아리 증후군 환자를 혈관성형술로 치료한 증례보고

아주대학교병원 외과, ¹아주대학교병원 영상의학과, ²아주대학교병원 외상외과

심주현, 원제환¹, 정경원², 이국종², 김영환²

- Abstract -

Balloon Angioplasty for Budd-Chiari Syndrome Resulting from Primary Repair of an Inferior Vena Cava Injury

Joohyun Sim, M.D., Je Hwan Won, M.D.¹, Kyoungwon Jung, M.D.²,
Cook John Lee, M.D.², Young Hwan Kim, M.D.²

Department of Surgery, Ajou University Hospital, Suwon, South Korea,

¹Department of Radiology, Ajou University Hospital, Suwon, South Korea,

²Division of Trauma Surgery, Department of Surgery, Ajou University Hospital, Suwon, South Korea

Budd-Chiari syndrome is an uncommon condition characterized by hepatic outflow obstruction. Direct suture of the injured Inferior vena cava in a patient with blunt hepatic trauma also may cause an equivalent condition. However, early diagnosis is possible with common symptoms and radiologic evaluation. Moreover, a transluminal approach with balloon angioplasty could prevent long-term complications of Budd-Chiari syndrome without repeated abdominal surgery. [J Trauma Inj 2014; 27: 196-200]

Key Words: Inferior vena cava, Angioplasty, Budd-Chiari syndrome, Human

I. Introduction

Traumatic inferior vena cava (IVC) injuries are a relatively rare event, occurring in only up to 5% of penetrating injuries and only up to 1% of blunt

abdominal trauma.(1,2) Stenosis of the suprahepatic IVC after damage control surgery is a rare cause of Budd-Chiari syndrome. Treatment of Budd-Chiari syndrome after blunt hepatic trauma has traditionally involved thrombolysis and hepatic venous

* Address for Correspondence : **Young Hwan Kim, M.D.**

Department of Surgery, Ajou University Hospital

164, World Cup-ro, Yeongtong-gu, Suwon 443-380, South Korea

Tel : 82-31-219-4457, Fax : 82-31-219-7765, E-mail : galgunbam2@hanmail.net

Submitted : June 16, 2014 **Revised** : July 16, 2014 **Accepted** : July 30, 2014

decompression. However, no case of IVC stenosis after emergency primary repair treated with angioplasty has been reported.

We report a case of Budd-Chiari syndrome occurring about 2 weeks following damage control surgery after life-threatening blunt abdominal trauma and successfully managed with balloon percutaneous transluminal angioplasty (PTA).

II. Case

A 29-year-old woman was a restrained driver in a slow-speed motor vehicle crash. At the scene of the crash, she had normal vital signs and a Glasgow Coma Scale of 15. She was initially transported to a nearby hospital, but was referred to Ajou University Trauma Center via medical helicopter due to a rapid deterioration of her medical status and absence of trauma surgeon at the initial hospital. Initial evaluation at the previous hospital included computed tomography scans of brain, abdomen and lower extremity. She had right hip dislocation, liver laceration and suprahepatic IVC injury (Fig. 1). Closed reduction of her hip joint was performed before transport. Upon arrival to our hospital, she had been intubated during transport due to dyspnea and had hypotension with blood pressure of 92/49 mmHg with a Glasgow Coma Scale score of 4. Her body temperature showed hypothermia with body temperature of 35.9°C. Exploratory laparotomy was decided promptly at arrival and she was transported directly to the operating room in 5 minutes.

A Mercedes-Benz incision was made, and a large amount of hematoma was noticed at opening of the peritoneum. Segment 8 of the liver was deeply lacerated and a large amount of hemorrhage was pumping up from the liver as well as torn diaphragm and suprahepatic IVC. Diaphragm was partially dissected and several primary sutures were applied to the torn IVC for hemostasis (Fig. 2). Hepatorrhaphy was performed on deeply lacerated liver and surgical aids for hemostasis were applied. After massive irrigation, spleen laceration was also noticed and splenectomy was performed. The first exploration was over after closed thoracotomy of the right thorax, and abdominal wall was temporarily closed after packing gauze

around the injured liver for tamponade.

Postoperative course was smooth without events, and a 2nd look operation was decided on postinjury day 4. There was no more noticeable bleeder found after gauze removal, but lateral section of the liver

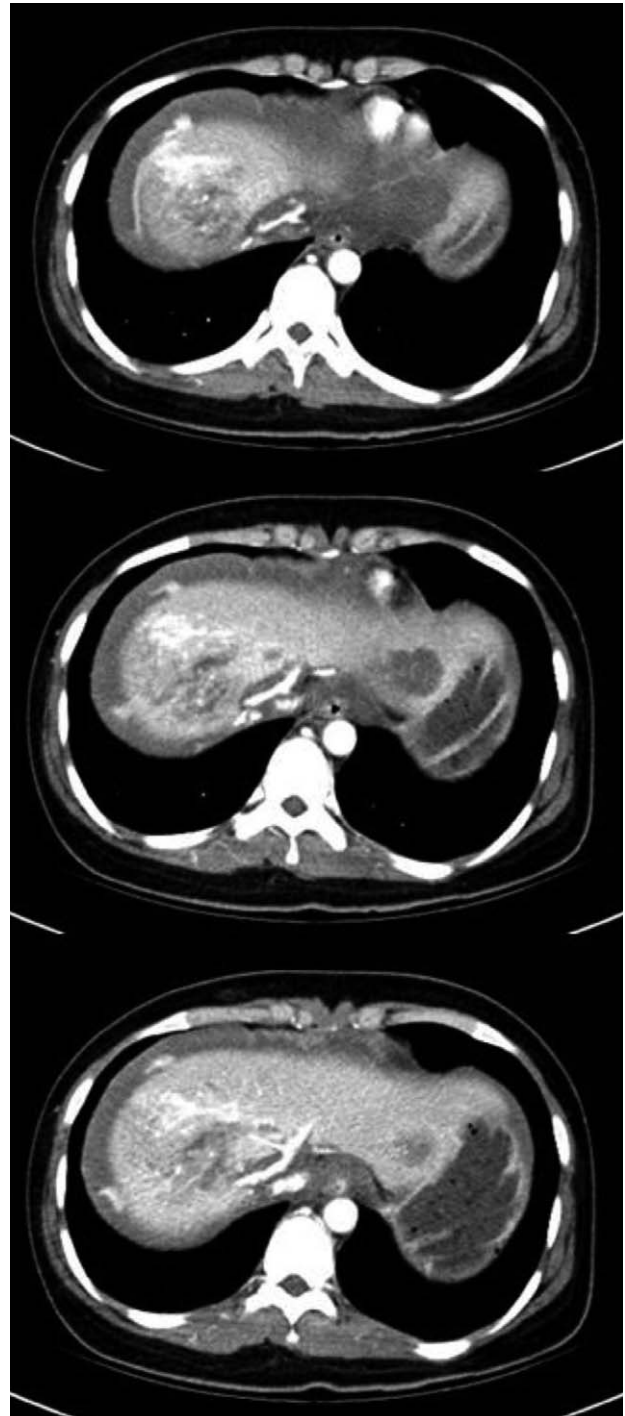

Fig. 1. Three consecutive cuts of Axial CT scan at the level of juxtahepatic IVC demonstrate blunt hepatic injury and thrombus inside the IVC.

was congested and gangrenous. As a result, lateral sectionectomy was decided to be performed with cholecystectomy.

The patient's postoperative daily progress was satisfactory, and she was extubated on postinjury day 8. On postinjury day 11, she underwent an abdominal computed tomography scan for follow up. There was no remarkable intraabdominal problem except a small amount of fluid collection formed in the segment 8 of the liver and mild infiltration. Her diet was built up to a soft diet and she tolerated well.

On postinjury day 18, abdominal CT scan was taken because the patient complained of mild abdominal distention and persistent mild fever up to 38.1°C. On the CT scan, a large amount of fluid was noticed in the pelvic cavity accompanied with mild periportal edema and narrowing of suprahepatic IVC (Fig. 3). There was no thrombus found in the IVC. Clinically, the patient had pitting edema of both legs

and left pleural effusion. Percutaneous drainage catheters were inserted to left thoracic cavity and pelvic cavity for drainage of fluid and routine examination with culture to rule out infectious cause.

Then on postinjury day 27, we first planned to place a bare-metal stent in the IVC to treat Budd-Chiari syndrome. However, the patient was young, and permanent placement of the stent could cause neointimal hyperplasia and fibrin clots which may clog hepatic vein orifice. So we decided to proceed with gradual balloon angioplasty instead, after having a discussion with the interventional radiologist. Initial venography showed 95% stenosis of the suprahepatic IVC, gradual balloon dilatation of IVC with 14 mm and 16 mm balloon was performed. Initial pressure gradient between the right atrium and IVC was 16 mmHg, but it fell down to 7 mmHg after 14 mm balloon dilatation and then to 4 mmHg after 16 mm balloon dilatation (Fig. 4). Bail-out

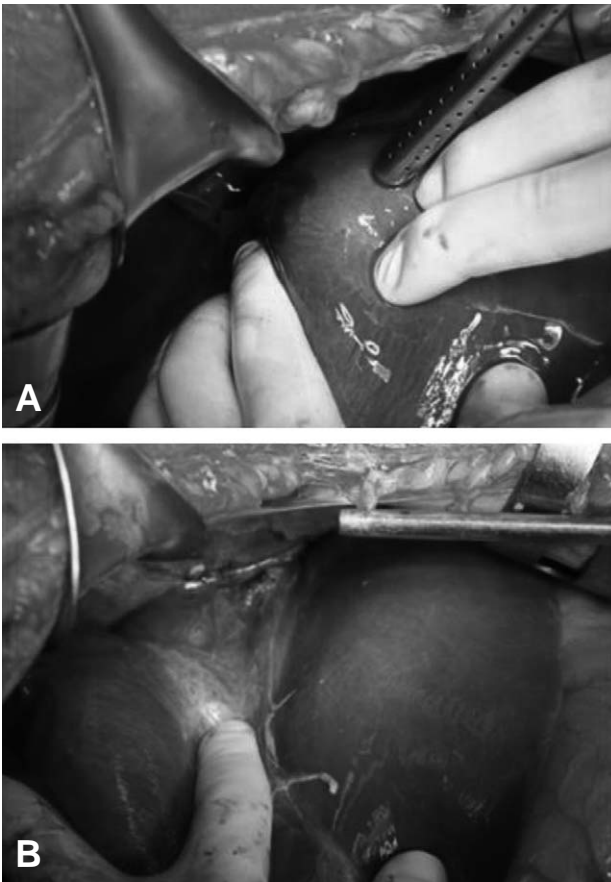


Fig. 2. (A) Suprahepatic IVC injury with massive bleeding was noticed. (B) Direct suture of IVC was performed.

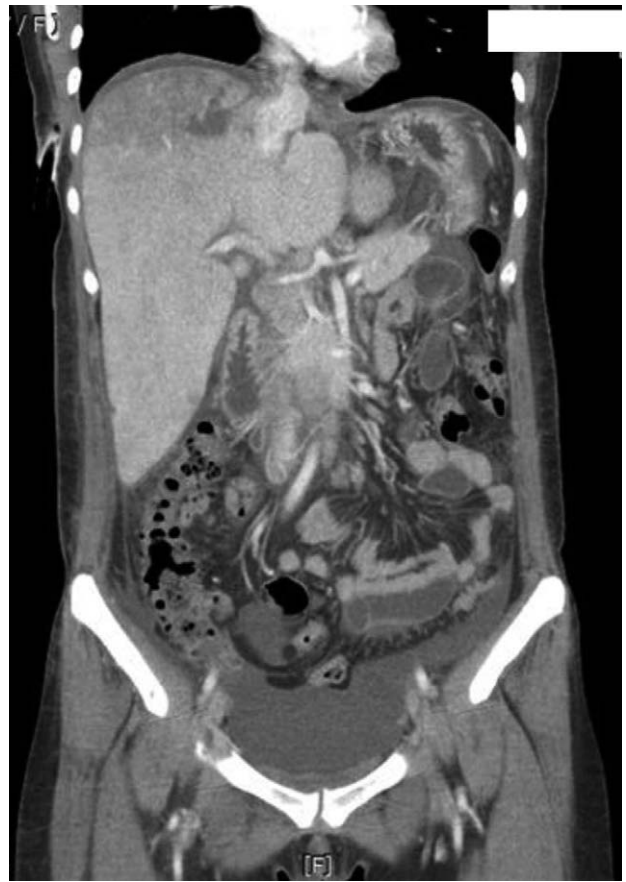

Fig. 3. A large amount of fluid was noticed in the pelvic cavity accompanied with mild periportal edema and narrowing of suprahepatic IVC was noticed at the level of the diaphragm.

stenting was not necessary because the gradient pressure dropped down to lower than 5 mmHg. So re-balloonng with larger diameter was planned for a month later. Astrix 100 mg and Plavix 75 mg were administered per oral daily.

In 4 days after the PTA, the patient showed much improvement with symptoms and all drainage catheters were removed. After taking follow-up CT scan and receiving *pneumococcus* and *Hemofilus influenza b* vaccination, she was discharged on postinjury day 44 with a re-admission plan.

The patient was re-admitted and went through a second PTA on postinjury day 56. Previously dilated IVC was recoiled and 80% stenosis was noticed. The pressure gradient between the right atrium and IVC was 8 mmHg, and it fell down to 3 mmHg after balloon dilatation with 20 mm balloon. A follow-up abdominal CT on postinjury day 59 proved that ascites no more existed and that the lumen of suprahepatic IVC was even larger compared to the previous CT (Fig. 5).

III. Discussion

Budd-Chiari syndrome is caused by hepatic venous outflow obstruction, and it must be recognized promptly because hepatomegaly and ascites

eventually progress to liver failure or portal hypertension with esophageal varices.(3-7)

The causes of this syndrome are diverse (3) but one or more thrombotic risk factors underlie onset of Budd-Chiari syndrome in most patients.(4) Most prevalent underlying condition is myeloproliferative disorder,(4) and trauma is known as an infrequent cause.(3,8) However, in our case, the Budd-Chiari syndrome occurred after damage control surgery for grade V hepatic trauma.

To save our liver injury patient, we performed intraparenchymal and perihepatic packing, deep hepatic suture, lateral sectionectomy, and direct suture repair of IVC. It is known that direct venous repair of juxtahepatic venous injuries have very high mortality rates (9-11) but the patient has survived. Even so, as a complication of direct suture repair of the IVC, Budd-Chiari syndrome due to

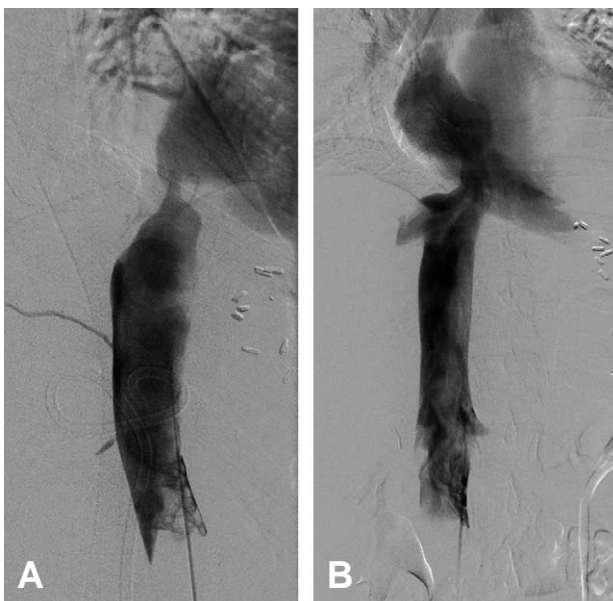

Fig. 4. (A) Initial venography showed 95% stenosis of the suprahepatic IVC with gradient pressure of 16 mmHg. (B) After PTA, the gradient pressure dropped to 4 mmHg.

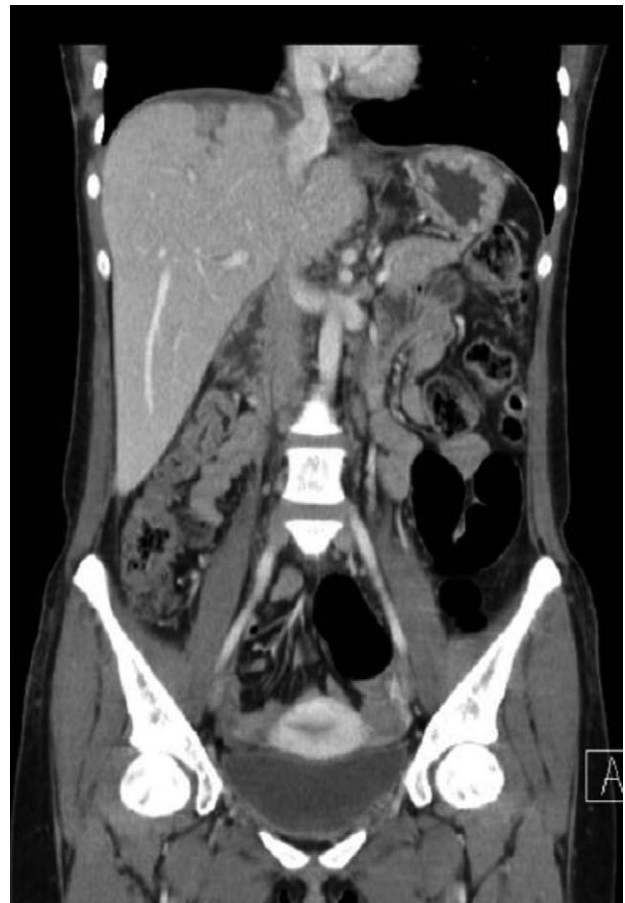

Fig. 5. A coronal view of a follow-up abdominal CT scan on postinjury day 59 demonstrates no more ascites, and the lumen of suprahepatic IVC grew larger compared to the previous CT.

stenosis of the IVC emerged 2 weeks after the emergency surgery. We aimed to perform venous stenting initially but balloon angioplasty was selected to remove the burden of a lifelong coumadinization and to prevent rupture of repaired vessel. To prevent restenosis, gradual dilatation is periodically scheduled for safer approach.

IV. Conclusion

In our case, the site of massive bleeding was right at the suprahepatic IVC where it runs out from the liver and into the diaphragm and the heart. After an emergency operation due to bleeding from IVC, symptoms reflecting the Budd-Chiari syndrome, such as ascites and abdominal pain, should be closely watched for proper management. As a treatment option, balloon angioplasty could be chosen for patient safety and efficiency.

REFERENCES

- 1) Cudworth M, Fulle A, Ramos JP, Arriagada I. GCS as a predictor of mortality in patients with traumatic inferior vena cava injuries: a retrospective review of 16 cases. *World J Emerg Surg* 2013; 8: 59.
- 2) Cole K, Shadis R, Sullivan TR, Jr. Retrohepatic hematoma causing caval compression after blunt abdominal trauma. *J Surg Educ* 2009; 66: 48-50.
- 3) Patel NH, Bradshaw B, Meissner MH, Townsend MF. Posttraumatic Budd-Chiari syndrome treated with thrombolytic therapy and angioplasty. *J Trauma* 1996; 40: 294-8.
- 4) Darwish Murad S, Plessier A, Hernandez-Guerra M, Fabris F, Eapen CE, Bahr MJ, et al. Etiology, management, and outcome of the Budd-Chiari syndrome. *Ann Intern Med* 2009; 151: 167-75.
- 5) Slakey DP, Klein AS, Venbrux AC, Cameron JL. Budd-Chiari syndrome: current management options. *Ann Surg* 2001; 233: 522-7.
- 6) Li T, Zhai S, Pang Z, Ma X, Cao H, Bai W, et al. Feasibility and midterm outcomes of percutaneous transhepatic balloon angioplasty for symptomatic Budd-Chiari syndrome secondary to hepatic venous obstruction. *J Vasc Surg* 2009; 50: 1079-84.
- 7) Wu T, Wang L, Xiao Q, Wang B, Li S, Li X, et al. Percutaneous balloon angioplasty of inferior vena cava in Budd-Chiari syndrome-R1. *Int J Cardiol* 2002; 83: 175-8.
- 8) Markert DJ, Shanmuganathan K, Mirvis SE, Nakajima Y, Hayakawa M. Budd-Chiari syndrome resulting from intrahepatic IVC compression secondary to blunt hepatic trauma. *Clin Radiol* 1997; 52: 384-7.
- 9) Buckman RF, Jr., Miraliakbari R, Badellino MM. Juxtahepatic venous injuries: a critical review of reported management strategies. *J Trauma* 2000; 48: 978-84.
- 10) Denton JR, Moore EE, Coldwell DM. Multimodality treatment for grade V hepatic injuries: perihepatic packing, arterial embolization, and venous stenting. *J Trauma* 1997; 42: 964-7; discussion 7-8.
- 11) Prichayudh S, Sirinawin C, Sriussadaporn S, Pak-Art R, Kritayakirana K, Samorn P, et al. Management of liver injuries: Predictors for the need of operation and damage control surgery. *Injury* 2014.