

## Case Report

# Rapid Regression of White Matter Changes in Hypoglycemic Encephalopathy

Sang-wook Son, Kye-ho Lee, Dong-soo Yoo

Department of Radiology, Dankook University Hospital, Cheonan, Korea

**Purpose :** In a previous report, it took several days for white matter lesions to regress in hypoglycemic encephalopathy. We present a case of rapid diffusion-weighted image (DWI) changes in hypoglycemic encephalopathy.

**Case Report:** A 58-year-old male patient was found semi-comatous with the only abnormality in his laboratory tests showing hypoglycemia (44 mg/dL). After rapid correction of glucose level, immediate brain DWI showed bilateral subcortical white matter lesions. After about 5 hours, follow-up DWI showed resolved subcortical white matter lesions, with newly-appeared bilateral fronto-temporo-parietal cortical lesions.

**Conclusion:** Both white matter and cortex involvement in hypoglycemic encephalopathy has been shown in several reports, but rapid regression of white matter changes in hypoglycemic encephalopathy has been rarely reported. It is important to know that MR imaging changes in hypoglycemic encephalopathy can be made as quick as just a few-hour-long.

**Index words :** Hypoglycemic encephalopathy · Diffusion-weighted image · White matter

## INTRODUCTION

Hypoglycemia is caused by imbalance between glucose supply and glucose utilization. It is apt to be caused in diabetic patients as a side effect of excessive insulin and sulfonylurea uses. When hypoglycemic injury affects brain tissue and induces neurologic abnormalities, it is called hypoglycemic encephalopathy.

There is a report of DWI image changes from subcor-

tical white matter lesions to cortical lesions in hypoglycemic encephalopathy, but it took several days for the changes (1). We present a case of hypoglycemic encephalopathy, showing rapid changes and uncommon findings on sequential MRI examinations.

## CASE REPORT

A 58-year-old male patient with a history of diabetes presented with semicoma status. He was alert as usual, just 1 hour before being found in unresponsive status. On arrival at emergency department, vital signs were stable. His initial blood glucose level was 44 mg/dL and no other abnormality was found in his blood test. 10% D/W and 50% dextrose were continuously infused and blood glucose level went up as high as 292 mg/dL but his mental status was unchanged. After the rapid correction of blood glucose level for an hour, initial brain MRI was done immediately and it showed bilateral subcortical white matter lesions, which was

• Received; September 23, 2014 • Revised; November 18, 2014

• Accepted; November 26, 2014

Corresponding author : Sang-wook Son, M.D.

Department of Radiology, Dankook University Hospital, 201 Manghyang-ro, Dongnam-gu, Cheonan-si, Chungcheongnam-do 330-715, Korea.

Tel. 82-41-550-6921, Fax. 82-41-556-0524

E-mail : sonsangw@hanmail.net

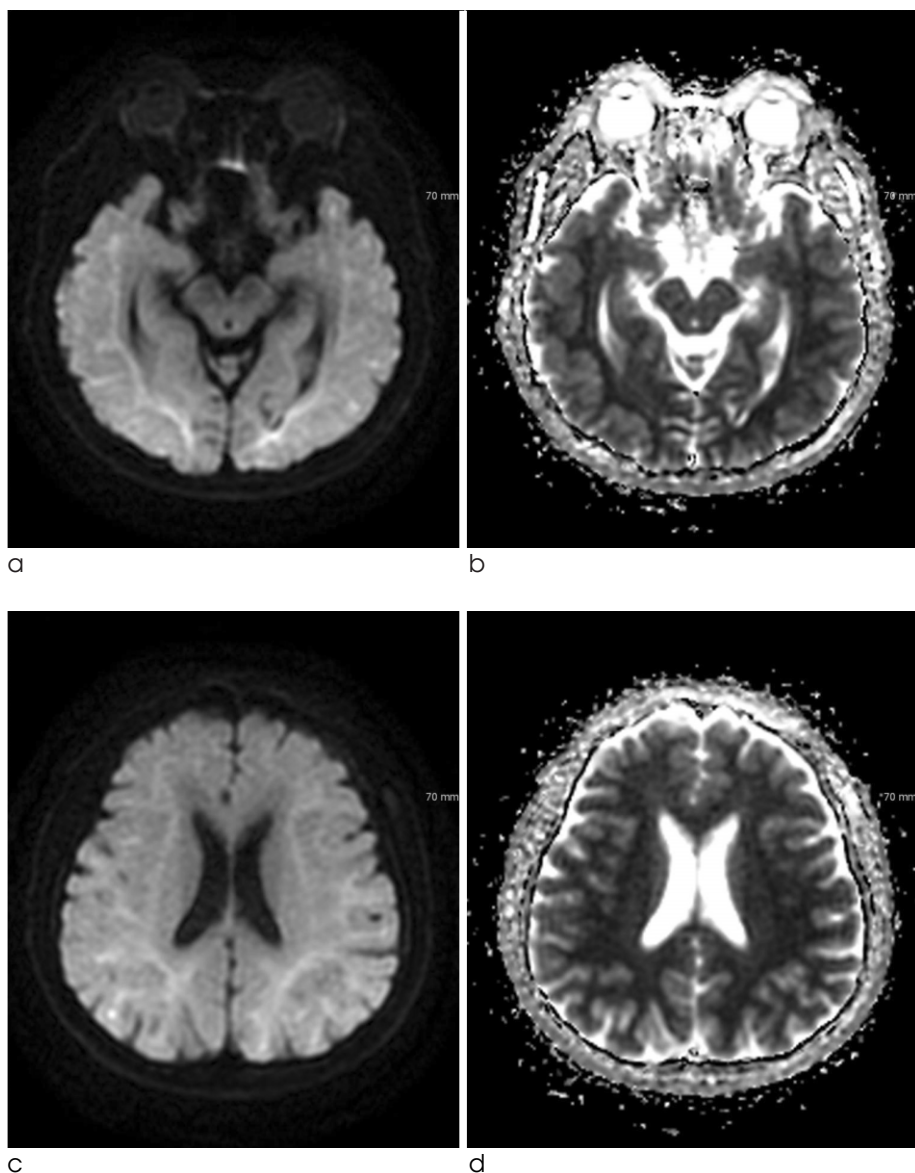
This is an Open Access article distributed under the terms of the Creative Commons Attribution Non-Commercial License (<http://creativecommons.org/licenses/by-nc/3.0/>) which permits unrestricted non-commercial use, distribution, and reproduction in any medium, provided the original work is properly cited.

hyperintense on diffuse DWI, hypointense on apparent diffusion coefficient (ADC) (Fig. 1). Deep and cortical gray matters were spared. He had no history of stroke and traumatic brain injury and no other abnormal findings on arterial blood gas analysis (ABGA), vital signs, and electrolyte. There was no other possible cause for his sudden mental change with abnormal findings on MRI. Approximately 5 hours 3 mins after the initial MRI scan, follow-up MRI scan was performed at the emergency department. Follow-up MRI showed resolved subcortical white matter lesions, with newly-appeared DWI high signal intensity lesions in bilateral fronto-temporo-parietal cortex (Fig. 2). He had admitted to the hospital for 3

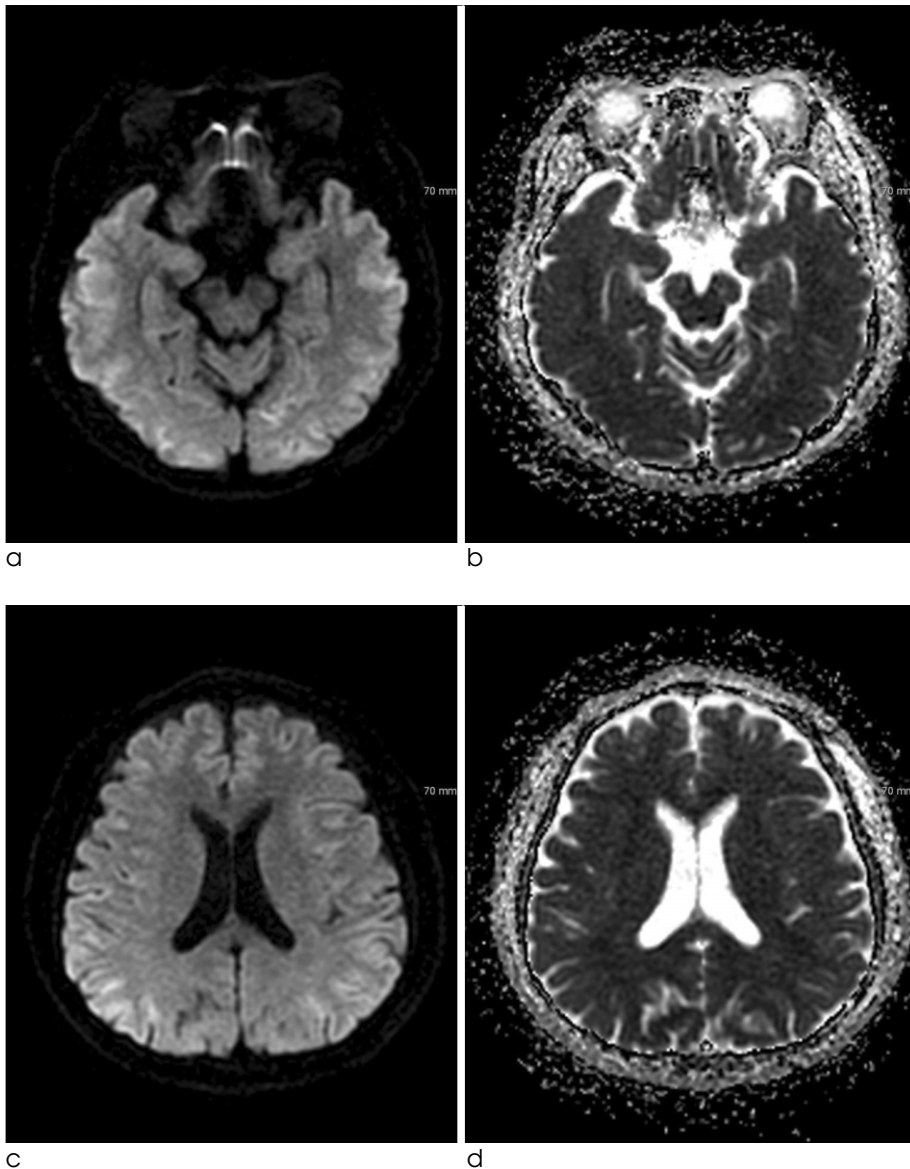
more days and transferred to another hospital on his family's will. During the hospitalization, the blood glucose level was maintained within normal limits and no other causative brain damage was noted but his mentality remained unchanged.

## DISCUSSION

Glucose is known as mainstay of brain energy source. Therefore profound glucose deficiency may lead to neuronal necrosis, which is very identical to neuronal ischemic damage by oxygen deficiency, and it has been demonstrated in pathologic studies (2).



**Fig. 1.** Initial DWI (TR/TE = 8000/86, b value 1000 seconds/mm<sup>2</sup>) with corresponding ADC map. Diffuse DWI high signal intensity, ADC low signal intensity lesions are noted in bilateral subcortical white matter. Deep and cortical gray matters are spared.



**Fig. 2.** Follow-up DWI (TR/TE = 8000/87.4, b value 1000 seconds/mm<sup>2</sup>) with ADC map, 5 hrs 3 mins after the initial MRI scan. Previous subcortical white matter lesions were resolved and DWI high signal intensity lesions are newly-seen in bilateral fronto-temporo-parietal cortex.

Glucose deprivation may lead to brain energy failure, membrane ionic pump failure and tissue alkalosis, causing a shift of water into the intracellular space and a drastic reduction of extracellular space volume and leading to selective neuronal necrosis, especially in the cerebral cortex, basal ganglia, and hippocampus (3).

Various patterns of hypoglycemic encephalopathy are shown on DWI (4). But, the mechanism of ADC reduction in hypoglycemia is still unclear. Cortical laminar necrosis may be the most likely mechanism for the hyperintensity revealed by DWI during subacute period (5). In an animal study, Hasegawa et al documented global cortical decline in ADC rapidly spreading to the entire brain, showing neuronal

necrosis in the hippocampus and the neocortex in animals with prolonged hypoglycemia. But the reductions in ADC were transient and were reversed by glucose infusion (6). Reversibility of the ADC abnormalities can be explained by the mechanism of excitotoxic edema. Increased extracellular glutamate causes calcium and sodium entering into cells, inducing apoptosis, however, glutamate also induces edema of glial cells and myelin sheaths, called excitotoxic edema, which might protect axons from irreversible damage (7). Moreover, the receptors related to excitotoxic mechanisms are widely distributed in both gray and white matter, which may explain the widely distribution of early DWI abnormalities (8).

Diffuse and extensive injury observed on DWI predicts a poor neurologic outcome in hypoglycemic encephalopathy (4).

In patients with hypoglycemic encephalopathy, brain parenchymal lesions were typically shown to be distributed bilaterally in the basal ganglia, hippocampus, cerebral cortex, and/or substantia nigra but not in the thalamus (9). However, this case shows a DWI of hypoglycemic encephalopathy patient presented with subcortical white matter lesions followed by bilateral fronto-temporo-parietal cortical lesions. Recently, there were several reports showing hypoglycemic encephalopathy patients with an untypical finding of diffuse white matter changes (4, 10). Another case report showed that hypoglycemic encephalopathy patient presented with subcortical white matter lesions and 14 days later demonstrating new hyperintense lesions involving bilateral cerebral cortex while previous subcortical white matter lesions disappeared (1). But to the best of our knowledge, this is the first case report in which white matter lesions rapidly resolve and cortical lesions follow just in about 5 hours.

The explanations for these rapid changes from white matter lesions to gray matter lesions remain unknown. It has been proposed that brain tissue have different vulnerability to hypoglycemia, therefore, gray matter showed delayed presentation of DWI abnormalities (1). We proposed that variable factors, such as severity of hypoglycemic damage or individual difference in vulnerability to hypoglycemia, might determine the time interval between the changes of white matter and gray matter lesions. But these hypotheses remain yet to be further explained.

Our report has a limitation that we are not sure of what sort of injury had basically induced brain damage to our patient. But considering he had been imprisoned for several days and no other possible causative agents were found in prison, plus, he only demonstrated low blood glucose level in physical exam and laboratory tests, hypoglycemia had most likely induced both bilateral cortex and white matter

injuries.

In conclusion, we described the neurochemical pathophysiology of hypoglycemic encephalopathy, the mechanism of DWI changes in hypoglycemia and some hypotheses for the rapid changes from white matter lesions to gray matter lesions. It is important to know that MR imaging changes in hypoglycemic encephalopathy can be made as quick as just a few-hour-long, quicker than we have known through the previous report. Performing early follow-up DWI scan might be helpful in quickly determining the extent of brain damage and quickly accessing the clinical severity in some patients with hypoglycemic encephalopathy.

## References

1. Lee CY, Liou KC, Chen LA. Serial magnetic resonance imaging changes in hypoglycemic encephalopathy. *Acta Neurol Taiwan* 2013;22:22-25
2. Auer RN. Progress review: hypoglycemic brain damage. *Stroke* 1986;17:699-708
3. Pelligrino D, Almquist LO, Siesjo BK. Effects of insulin-induced hypoglycemia on intracellular pH and impedance in the cerebral cortex of the rat. *Brain Res* 1981;221:129-147
4. Ma JH, Kim YJ, Yoo WJ, et al. MR imaging of hypoglycemic encephalopathy: lesion distribution and prognosis prediction by diffusion-weighted imaging. *Neuroradiology* 2009;51:641-649
5. Yoneda Y, Yamamoto S. Cerebral cortical laminar necrosis on diffusion-weighted MRI in hypoglycaemic encephalopathy. *Diabet Med* 2005;22:1098-1100
6. Hasegawa Y, Formato JE, Latour LL, et al. Severe transient hypoglycemia causes reversible change in the apparent diffusion coefficient of water. *Stroke* 1996;27:1648-1655
7. Aoki T, Sato T, Hasegawa K, Ishizaki R, Saiki M. Reversible hyperintensity lesion on diffusion-weighted MRI in hypoglycemic coma. *Neurology* 2004;63:392-393
8. Hassel B, Boldingh KA, Narvesen C, Iversen EG, Skrede KK. Glutamate transport, glutamine synthetase and phosphate-activated glutaminase in rat CNS white matter. A quantitative study. *J Neurochem* 2003;87:230-237
9. Fujioka M, Okuchi K, Hiramatsu KI, Sakaki T, Sakaguchi S, Ishii Y. Specific changes in human brain after hypoglycemic injury. *Stroke* 1997;28:584-587
10. Mori F, Nishie M, Houzen H, Yamaguchi J, Wakabayashi K. Hypoglycemic encephalopathy with extensive lesions in the cerebral white matter. *Neuropathology* 2006;26:147-152

## 저혈당성 뇌병증에서 뇌백질 변화의 빠른 퇴행

단국대학교병원 영상의학과

손상욱 · 이계호 · 유동수

**목적:** 이전의 증례 보고에서는 저혈당성 뇌병증 환자의 뇌백질의 변화가 퇴행하기까지 수 일이 소요되었다. 본 저자들은 저혈당성 뇌병증에서 확산강조영상의 빠른 변화를 경험하였다. 이에 문헌 고찰과 함께 보고자 한다.

**증례 보고:** 58세 남자 환자가 반혼수 상태로 발견되었으나 혈액 검사 상 저혈당 (44 mg/dL)이 나타난 것 외 이 소견이 없었다. 혈당 수치를 빠르게 교정한 후 곧바로 촬영한 뇌 확산강조영상에서 양쪽 피질하 백질의 병변이 관찰되었다. 5시간 후 재시행한 확산강조영상에서 피질하 백질이 회복된 대신 양쪽 전방측두두정엽 피질의 병변이 새로이 발견되었다.

**결론:** 저혈당성 뇌병증 환자에서 뇌백질과 피질이 모두 이상소견을 보이는 증례 보고는 이전에도 다수 있었지만 이럼 뇌백질 변화가 빠른 퇴행을 보이는 증례는 거의 보고된 바 없다. 저자들은 저혈당성 뇌병증에서 자기공명 영상의 변화가 빠르게는 수 시간 내로도 나타날 수 있다는 걸 알리고자 한다.

통신저자 : 손상욱, (330-715) 충남 천안시 동남구 망향로 201, 단국대학교병원 영상의학과  
Tel. (041) 550-6921 Fax. (041) 556-0524 E-mail: sonsangw@hanmail.net