

RESEARCH ARTICLE

Comparison of Primary Breast Cancer Size by Mammography and Sonography

Jian-Tao Wang, Li-Ming Chang, Xin Song, Li-Xin Zhao, Jun-Tao Li, Wei-Guo Zhang, Ying-Bin Ji, Li-Na Cai, Wei Di, Xin-Yu Yang*

Abstract

Purpose: To compare tumor size by mammography and sonography and align with pathological results in primary breast cancer cases. **Materials and Methods:** We retrospectively reviewed 95 primary breast cancer patients who underwent mammography and sonography from January 2011 to June 2012. The largest tumor diameter was chosen as sizing reference for each imaging modality. The measurements of mammography and sonography were considered concordant if they were within the measurement of pathological results ± 0.5 cm. Pearson's correlation coefficient was calculated for imaging results. **Results:** The range of the maximum diameter was 0.6cm-10.5cm and mean value was 3.81 ± 2.04 cm by pathological results, 0.7cm-12.4 cm and 3.99 ± 2.19 cm by mammography, and 0.9cm-11.0cm and 3.63 ± 2.01 cm by sonography, respectively. Sonography (R: 0.754), underestimated tumor size, but had a better correlation with pathological tumor size compared to mammography (R: 0.676), which overestimated tumor size. **Conclusions:** Sonography is superior to mammography in assessment of primary breast cancer.

Keywords: Breast cancer-tumor size · mammography · sonography-pathology

Asian Pac J Cancer Prev, 15 (22), 9759-9761

Introduction

Tumor size is not only a prognostic indicator but also a preliminary factor in determining surgical or neo-adjuvant treatment plan. The success of breast conservation surgery relies on the accurate measurement of tumor size (Del Barco et al., 2013; Roder et al., 2013; Kantor & Winchester, 2014), as underestimating of tumor size may lead to incomplete margins and even re-excision. And it is also an important factor in determining the requirement for neoadjuvant or adjuvant chemotherapy. This study tries to investigate the ability of mammography and sonography imaging modalities in assessment of tumor size, using pathological size as the gold standards.

Materials and Methods

Overall, we collected mammography and sonography data of 95 malignant cases that underwent surgical resection in our institution from January 2011 to June 2012. Patients who underwent neoadjuvant chemotherapy were excluded from the study. All tumors could be visible or measurable in two imaging modalities. The largest tumor diameter was chosen as the sizing reference. Using pathological results as the gold standards, and measurements of mammography and sonography were considered concordant if they were within measurement of pathological result ± 0.5 cm.

Mammography was performed with a digital fullfield instruments (Hologic Selenia) using standard craniocaudal and medial-lateral oblique projections. Sonography examination was performed in all patients on dedicated units (GE Logiq 7, GE Logiq 9 and Siemens IU-22) using a 7-10MHz probe. The largest dimension was recorded from the views.

Pearson's correlation coefficients were calculated to assess the strength of the linear relationship between pathologic and mammography or sonography and results. Statistical analysis was carried out by SPSS16.0. All results were considered significant at $p < 0.05$.

Results

All 95 patients had a mean age of 52.3 years (range 24-78 years). The ranges of the maximum diameter was 0.6cm-10.5cm and mean value was (3.81 ± 2.04) cm by pathological results.

Mammography overestimated tumor size. Mammography results of tumor size ranged from 0.7cm to 12.4cm and mean value was (3.99 ± 2.19) cm. Pearson's correlation coefficients of mammography compared to pathological size were 0.676 (Figure 1). In 95 patients, 44 (46.3%) patients overestimated, 31 (32.6%) patients underestimated and 20 (21.2%) patients had mammographic tumor size within pathological tumor size ± 0.5 cm (Table 1).

X-Ray Department, Tangshan Gongren Hospital, Tangshan, Hebei, China *For correspondence: gryyyangxinyu@163.com

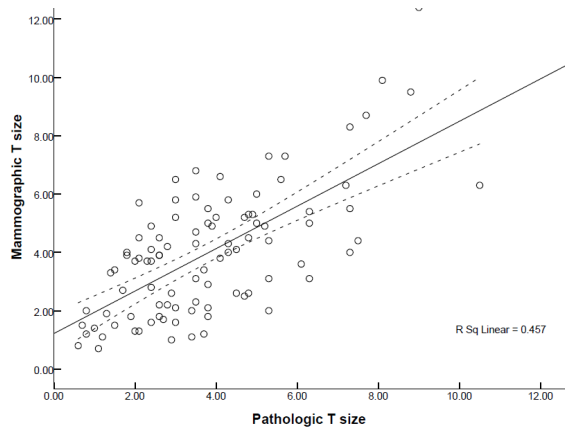


Figure 1. Scatter Plots, Best Fit and 95% Prediction Interval Lines of Pathologic Tumor Size and Mammography Tumor Size. They had a positive correlation and the correlation coefficient was 0.676 ($p < 0.001$)

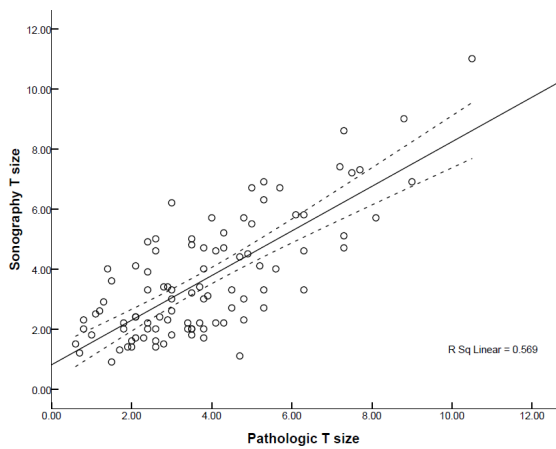


Figure 2. Scatter plots, best fit and 95% prediction interval lines of pathologic tumor size and sonography tumor size. They had a positive correlation and the correlation coefficient was 0.754 ($p < 0.001$)

Table 1. Concordance (± 0.5 cm) between Two Imaging Modalities And Pathological Results

Concordance	Mammography	Sonography
Underestimated	31 (32.6%)	37 (38.9%)
Overestimated	44 (46.3%)	27 (28.4%)
Concordant	20 (21.2%)	31 (32.6%)

While Sonography underestimated tumor size. Sonography results of tumor size ranged from 0.9cm to 11.0cm and mean value was (3.63 ± 2.01) cm. Pearson’s correlation coefficients of sonography compared to pathologic size were 0.754 (Figure 2). In 95 patients, 37 (38.9%) patients underestimated, 27 (28.4%) patients overestimated and 31 (32.6%) patients had mammographic tumor size within pathological tumor size ± 0.5 cm (Table 1).

Discussion

Accurate measurement of primary invasive breast cancer is crucial for staging and treatment plan. Especially with the widespread use of breast-conservation surgery, it becomes more and more important. Assessment of tumor size depends on imaging modalities such as

mammography and sonography. So this study compared the ability of mammography and sonography imaging modalities in assessment of tumor size, using pathological size as the gold standards, to try to find more useful modality for accurate assessment of tumor size.

There is conflict about whether mammography overestimating or underestimating tumor size compared with pathology (Fornage et al., 1987; Gruber et al., 2013; Hieken et al., 2001; Madjar et al., 1993). The edge of tumors could not be clearly displayed as the margin is hidden by superimposed or adjacent tissue, that directly leads to deviation of measurement. In addition, there are many reasons in the process of formation of image. Such as some distances exist between the tumor and detector, the compression of breast leads to deformation of the tumors and the maximum tumor size could not be captured completely. In our study, 46.3% patients overestimated and 32.6% patients underestimated the tumor size by mammography.

Sonography is especially useful when the breast had a heterogeneously and extremely dense breast in which a mammographic lesion is obscured by the overlying tissue. But the percentage of underestimates tumor size by sonography is high, not only in this study, but also in several previous studies (Bosch et al., 2003; Pritt et al., 2004; Dummin et al., 2007; Luparia et al., 2013). They have revealed that this phenomenon most appeared when tumors are vertical, due to the posterior acoustic shadow, the longest axis become difficult to measure. And also sonography could not clearly display the spiculate of tumors leading to a short measurement compared to pathology. What’s more, lesions performed as microcalcification in mammography, could not be visible absolutely.

Previous studies (Yang et al., 1997; Allen et al., 2001; Golshan et al., 2004) showed sonography measurement was a more accurate predictor than mammography measurement. Our study agrees with their findings. The correlation coefficient between sonography and mammography compared to pathology was 0.754 and 0.676 respectively. Literatures reported correlation coefficient were between 0.26~0.92 (Yang et al., 1997; Davis et al., 1996; Heusinger et al., 2005; Karellas & Vedantham, 2008; Pons et al., 2009; Wasif et al., 2009). Except for various reasons of mammography and sonography, pathologic measurement also had some extent of deviation from the true size, such as the shrinkage in the fixation processing of tumors and assessment of margins of the lesions may lead to the errors.

In conclusion, sonography proved to be more useful modality than mammography for predicting pathological tumor size in our study. But it inclined to underestimated tumor size, and this may had some significance in deciding treatment plan.

References

Allen SA, Cunliffe WJ, Gray J, et al (2001) Pre-operative estimation of primary breast cancer size: a comparison of clinical assessment, mammography and ultrasound. *Breast*, **10**, 299-305

- Bosch AM, Kessels AG, Beets GL, et al (2003) Preoperative estimation of the pathological breast tumour size by physical examination, mammography and ultrasound: a prospective study on 105 invasive tumours. *Eur J Radiol*, **48**, 285-92
- Davis PL, Staiger MJ, Harris KB, et al (1996) Breast cancer measurements with magnetic resonance imaging, ultrasonography, and mammography. *Breast Cancer Res Treat*, **37**, 1-9
- Del Barco S, Ciruelos E, Tusquets I, Ruiz M, Barnadas A (2013) SEOM clinical guidelines for the systemic treatment of early breast cancer 2013. *Clin Transl Oncol*, **15**, 1011-7
- Dummin LJ, Cox M, Plant L (2007) Prediction of breast tumor size by mammography and sonography--A breast screen experience. *Breast*, **16**, 38-46
- Fornage BD, Toubas O, Morel M (1987) Clinical, mammographic, and sonographic determination of preoperative breast cancer size. *Cancer*, **60**, 765-71
- Golshan M, Fung BB, Wiley E, et al (2004) Prediction of breast cancer size by ultrasound, mammography and core biopsy. *Breast*, **13**, 265-71
- Gruber IV, Rueckert M, Kagan KO, et al (2013) Measurement of tumour size with mammography, sonography and magnetic resonance imaging as compared to histological tumour size in primary breast cancer. *BMC Cancer*, **13**, 328
- Heusinger K, Lohberg C, Lux MP, et al (2005) Assessment of breast cancer tumor size depends on method, histopathology and tumor size itself*. *Breast Cancer Res Treat*, **94**, 17-23
- Hieken TJ, Harrison J, Herreros J, Velasco JM (2001) Correlating sonography, mammography, and pathology in the assessment of breast cancer size. *Am J Surg*, **182**, 351-4
- Kantor O, Winchester DJ (2014) Breast conserving therapy for DCIS--does size matter? *J Surg Oncol*, **110**, 75-81
- Karellas A, Vedantham S (2008) Breast cancer imaging: a perspective for the next decade. *Med Phys*, **35**, 4878-97
- Luparia A, Mariscotti G, Durando M, et al (2013) Accuracy of tumour size assessment in the preoperative staging of breast cancer: comparison of digital mammography, tomosynthesis, ultrasound and MRI. *Radiol Med*, **118**, 1119-36
- Madjar H, Ladner HA, Sauerbrei W, et al (1993) Preoperative staging of breast cancer by palpation, mammography and high-resolution ultrasound. *Ultrasound Obstet Gynecol*, **3**, 185-90
- Pons F, Duch J, Fuster D (2009) Breast cancer therapy: the role of PET-CT in decision making. *Q J Nucl Med Mol Imaging*, **53**, 210-23
- Pritt B, Ashikaga T, Oppenheimer RG, Weaver DL (2004) Influence of breast cancer histology on the relationship between ultrasound and pathology tumor size measurements. *Mod Pathol*, **17**, 905-10
- Roder D, Zorbas H, Kollias J, et al (2013) Factors predictive of treatment by Australian breast surgeons of invasive female breast cancer by mastectomy rather than breast conserving surgery. *Asian Pac J Cancer Prev*, **14**, 539-45
- Wasif N, Garreau J, Terando A, et al (2009) MRI versus ultrasonography and mammography for preoperative assessment of breast cancer. *Am Surg*, **75**, 970-5
- Yang WT, Lam WW, Cheung H, et al (1997) Sonographic, magnetic resonance imaging, and mammographic assessments of preoperative size of breast cancer. *J Ultrasound Med*, **16**, 791-7