

# Arthroscopic Treatment of the Intratendinous Ganglion of the Long Head of Biceps Brachii - A Case Report

Jin-Man Wang, Woojin Yi<sup>✉</sup>, Jin-Hyoung Son, Jung-Ju Im

Department of Orthopaedic Surgery, Seoul Red Cross Hospital, <sup>1</sup>Department of Orthopaedic Surgery, Gangbuk Yonsei Sarang Hospital, Seoul, Korea

A ganglion is a benign cystic mass, commonly found around a joint or tendon sheath. It frequently occurs at the wrist, foot, ankle, and knee. Intratendinous ganglion has been rarely reported, and intratendinous ganglion of the long head of biceps brachii is extremely rare. According to our literature review, this is the third case of intratendinous ganglion of the long head of biceps brachii, and the first case of arthroscopic treatment. Therefore we report a case of an arthroscopic treatment for an intratendinous ganglion of the long head of biceps brachii.

(*Clin Shoulder Elbow* 2014;17(4):194-196)

**Key Words:** Shoulder; Ganglion cysts; Biceps tendon; Arthroscopy

The ganglion cyst is the most common tumor-like lesion in the hand and the wrist.<sup>1-7)</sup> The ganglion cyst in the upper arm is uncommon and the intratendinous ganglion is also rare.<sup>1,2,4-9)</sup> Intratendinous ganglion cyst of the long head of biceps brachii (LHBB) tendon is an extremely rare entity.<sup>1,2)</sup> To the best of our knowledge, this is the third case of the intratendinous ganglion cyst of the LHBB tendon and the first case of arthroscopic treatment for it in English literature.

## Case Report

A 68-year-old woman reported left shoulder pain and weakness appeared spontaneously 1 year ago, and she found a palpable tender mass in the anterior aspect on her left shoulder 3 months ago. She had no history of trauma or infection on the shoulder and the upper arm. The mass was about 2×3 cm in size, soft, movable, and with tenderness. Physical examination indicated normal on passive range of motion and decreases in active range of motion of flexion to 140 degrees and that of abduction to 110 degrees. Neer's impingement test, Hawkins' impingement test, empty can test, full can test, speed test and Yergason test were positive. Instability tests for the gleno-humeral

joint were negative.

Simple x-ray films showed no abnormal findings. The magnetic resonance image revealed a 1.7×3.0×1.8 cm sized oval shaped cystic mass on the bicipital groove just distal to greater tubercle (Fig. 1A). The mass looked to be encapsulated by the biceps tendon sheath, and the LHBB was thin like a sheet, probably due to mass effect of the cystic mass (Fig. 1B). The intraarticular portion of the LHBB had higher signal intensity in T2 weighted image, which was assumed as a partial tear. A partial tear of the subscapularis tendon and a small full thickness tear of the supraspinatus tendon were seen.

Under the diagnosis of an intratendinous ganglion cyst, we performed an arthroscopic operation. We placed the patient in lateral position and began arthroscopic examination through the standard anterior and posterior portal. In arthroscopic findings, the partial rupture of the LHBB was seen just distal to its origin of superior labrum in the gleno-humeral joint. The subscapularis tendon was partially detached but not retracted from its footprint. In the subacromial space, small full thickness tear of supraspinatus tendon was found. First, we repaired subscapularis tendon to its footprint with an anchor and two simple sutures, and then we passed a suture through the intraarticular portion of the

**Received** June 17, 2014. **Revised** August 11, 2014. **Accepted** September 6, 2014.

**✉Correspondence to:** Woojin Yi

Department of Orthopaedic Surgery, Gangbuk Yonsei Sarang Hospital, 1005 Dongil-ro, Nowon-gu, Seoul 139-807, Korea

**Tel:** +82-2-2092-5503, **Fax:** +82-2-2092-5597, **E-mail:** prairie326@outlook.com

**Financial support:** None. **Conflict of interests:** None.



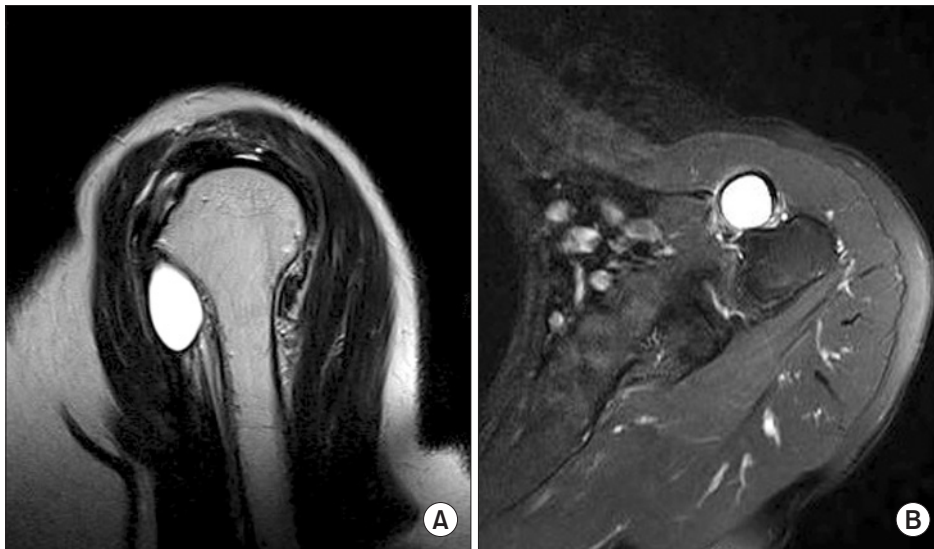

Fig. 1. (A) The sagittal view of T2 weighted image of magnetic resonance imaging (MRI) shows oval cystic mass with high signal intensity, just distal to the greater tubercle. (B) The axial view of T2 weighted image of MRI shows thinning of the long head of biceps brachii tendon around the cystic mass.

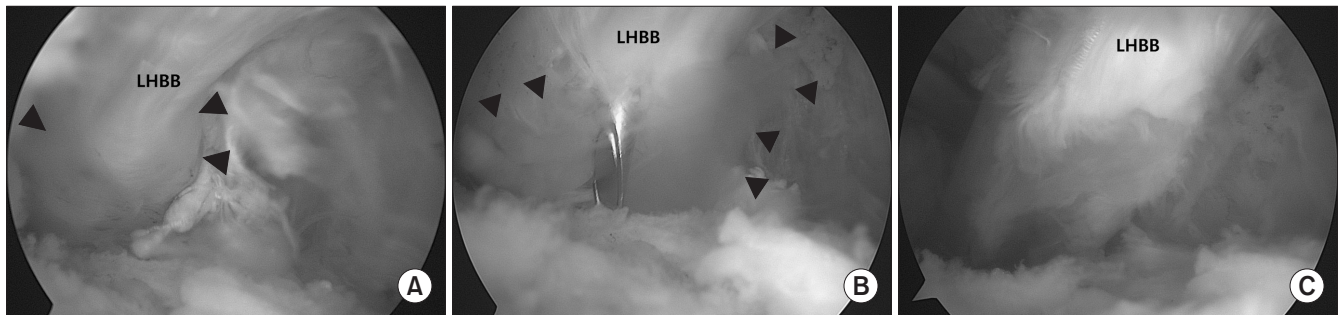


Fig. 2. (A) The arthroscopic view from the lateral portal shows oval enlargement of long head of biceps brachii (LHBB) (arrow head) at the bicipital groove. LHBB, long head of biceps brachii tendon. (B) Through the puncture hole with the needle, yellowish gelatinous material (arrow head) is draining. (C) After removal of the cyst capsule, about a half of the width of the LHBB are removed.

LHBB. Although the partial tear of the LHBB was not exceed 30% of total thickness, we performed tenotomy at the labral insertion of the LHBB for the *en bloc* resection of the ganglion cyst. In the subacromial space, we made the lateral working portal and the lateral viewing portal and exposed the LHBB tendon in the bicipital groove. By pulling the LHBB proximally with the suture, we traced along side it and found oval enlargement of the tendon. To be sure of the site of the cyst and the diagnosis, we punctured the oval enlargement with a needle and identified yellowish gelatinous material draining (Fig. 2A, B). We removed the capsule of cystic mass and cut the LHBB just distal to the cystic mass (Fig. 2C). After that, we repaired the full thickness tear of the supraspinatus tendon with double row suture bridge technique.

Pathologic examination revealed the fibromembranous tissue with mucous degeneration and no synovial lining, which is the characteristic of ganglion cyst. Upon follow-up after a year from the operation, she recovered nearly full range of motion on her left shoulder and elbow, and didn't feel motor weakness on

elbow flexion and forearm roation in her daily living. Ultrasonographic exam showed no recurrence of the ganglion cyst on the bicipital groove.

## Discussion

A ganglion cyst is a benign tumor-like mass that commonly occurs around the joint or the tendon sheath of the hand and wrist.<sup>1-7)</sup> According to the study of Kransdorf,<sup>8)</sup> 84 cases occurred in the hand and wrist out of 159 ganglions, and only 3 ganglions occurred in the proximal limb (axilla and shoulder). Intratendinous ganglion is relatively rare and that arising around the shoulder joint is even more uncommon.<sup>1,2,4-7,9)</sup> Only 2 cases of the intratendinous ganglion of the LHBB have been reported in English literature.<sup>1,2)</sup> Our case is the third case of intratendinous ganglion of the LHBB.

Kishimoto et al.<sup>1)</sup> described the ganglion cyst in their case as a multilobulated 1.5×5.0 cm cystic mass around the greater tubercle of the humerus. There was no further description about



the presence of stock or other pathologies around the shoulder joint. They treated it by open partial excision and repair of the LHBB. Rutten et al.<sup>2)</sup> showed a unilocular 2.5×7.5 cm cystic mass with stock, lying from the bicipital groove to biceps muscle belly. They also didn't refer to other pathologies. They treated it by open excision. The ganglion cyst in our case was unilocular, smaller than other 2 cases and confined within the bicipital groove without an identified stock. It was accompanied with the partial tear of LHBB and the rotator cuff tear. We treated it arthroscopically.

The characteristic of the ganglion cyst in a histologic examination consist of fibrous tissue wall without a synovial lining.<sup>1,2,4)</sup> It is important that no synovial lining exists in this structure, because the ganglion cyst is not the true cyst and thus this finding confirms the diagnosis of an intratendinous ganglion.<sup>4,7)</sup>

The etiology of the ganglion cyst is not fully understood and several theories of pathogenesis of the ganglion have been proposed. As for the intratendinous ganglion, many investigators agreed with the theory that the pathogenesis of the intratendinous ganglion is related to the recurrent injury to the tendon, because tenosynovitis or associated tendon tears are often found around the ganglion cyst.<sup>1-3,6,9)</sup> In our case, we also found partial tear and wearing on the intraarticular portion of the LHBB tendon.

Non-symptomatic intratendinous ganglion cyst is doubtful to treat. In many instances, watchful waiting may be enough. Rayan<sup>5)</sup> stated that treatment of symptomatic intratendinous ganglion should include preserving the tendon and excising the ganglion and its capsule followed by meticulous repair of the tendon. Other investigators insisted on that some kind of augmentation must be considered if most of the tendon is removed.<sup>1,10)</sup> But, Kono et al.<sup>4)</sup> treated the intratendinous ganglion of the extensor digitorum brevis tendon of the foot with *en bloc* resection, because the functional disadvantages of the tendon resection were thought to be negligible in their case. We think that the important factor of choosing the treatment method is whether complete recovery of function and maintenance of integrity of the LHBB tendon are indispensable or not, considering the characteristic of the biceps muscle with two head. In this point of view, open resection of the cyst and meticulous repair of the tendon with or without augmentation is more suitable for a young and active person, but tenotomy with *en bloc* resection can be one of the treatments of choices for an old, inactive person. One more advantage of *en bloc* resection over removal of cyst and repair of the tendon is that *en bloc* resection can completely remove the source of symptom and eliminate the possibility of recurrence.

Compared with open *en bloc* resection, we think arthroscopic *en bloc* resection is more favorable when accompanied with

other shoulder joint problems to treat arthroscopically, because possible complications related to an additional approach for the open surgery can be avoided. Arthroscopic *en bloc* resection can be performed through the established arthroscopic portals, therefore arthroscopic *en bloc* resection has no need of an additional approach and it is free from the problems related to the additional operative wound like scar formation, infection, or cephalic venous injury in the deltopectoral approach. But if the ganglion cyst is located distal portion of the LHBB or the size of the ganglion cyst is too large, arthroscopic *en bloc* resection may be impracticable.

We performed arthroscopic tenotomy with *en bloc* resection of the intratendinous ganglion cyst of the LHBB tendon with rotator cuff repair because our patient was old and her functional requirement of the arm is not high. This is the first case of arthroscopic treatment of intratendinous ganglion cyst of the LHBB tendon to the best of our literature review.

## References

1. Kishimoto K, Akisue T, Fujimoto T, et al. Intra-tendinous ganglion in the long head of the biceps humeri. *Skeletal Radiol.* 2008;37(3):263-5.
2. Rutten MJ, de Jong MD, van Loon T, Jager GJ. Intratendinous ganglion of the long head of the biceps tendon: US and MRI features (2010: 9b). *Intratendinous ganglion.* *Eur Radiol.* 2010; 20(12):2997-3001.
3. Beggs I, Saifuddin A, Limb D. Non-communicating intramuscular ganglia. *Eur Radiol.* 1998;8(9):1657-61.
4. Kono M, Miyamoto W, Imade S, Uchio Y. Intratendinous ganglion in the extensor digitorum brevis tendon. *J Orthop Sci.* 2009;14(5):666-8.
5. Rayan GM. Intratendinous ganglion. A case report. *Orthop Rev.* 1989;18(4):449-51.
6. Seidman GD, Margles SW. Intratendinous ganglia of the hand. *J Hand Surg Am.* 1993;18(4):707-10.
7. Gude W, Morelli V. Ganglion cysts of the wrist: pathophysiology, clinical picture, and management. *Curr Rev Musculoskelet Med.* 2008;1(3-4):205-11.
8. Kransdorf MJ. Benign soft-tissue tumors in a large referral population: distribution of specific diagnoses by age, sex, and location. *AJR Am J Roentgenol.* 1995;164(2):395-402.
9. Waldecker U. Unusual location of a posttraumatic ganglion and rupture of the peroneus brevis tendon: a case report. *J Foot Ankle Surg.* 2005;44(2):163-5.
10. Ikeda K, Tomita K, Matsumoto H. Intratendinous ganglion in the extensor tendon of a finger: a case report. *J Orthop Surg (Hong Kong).* 2001;9(2):63-5.