

Clinical Article

Galeal Tack-Up Sutures to Prevent Subgaleal Cerebrospinal Fluid Collection

Won Ho Choi, M.D., Chang Taek Moon, M.D., Ph.D., Young-Cho Koh, M.D., Young Il Chun, M.D., Joon Cho, M.D., Sang Woo Song, M.D.

Department of Neurosurgery, Konkuk University Medical Center, Seoul, Korea

Objective : Postoperative subgaleal cerebrospinal fluid (CSF) collection is considered as one of the common minor surgical complication which can lead to prolonged hospitalization. We introduce "galeal tack-up suture" to prevent postoperative subgaleal CSF collection.

Methods : Galeal tack-up suture consists of various surgical techniques which aim to fix galea to cranium in order to prevent CSF pooling in subgaleal space. A total of 87 patients who underwent craniotomy were divided into two groups while closing the wound : group A with galeal tack-up suture and group B with routine wound closure without galeal tack-up suture. The patients were observed for postoperative subgaleal CSF collection.

Results : Among 87 craniotomy cases, galeal tack-up suture was performed in 32 cases and routine wound closure was done in 55 cases. Postoperative subgaleal CSF collection occurred in 13 cases (15%) in which 12 cases occurred in group B patients and 1 case occurred in group A patients ($p=0.026$).

Conclusion : Galeal tack-up suture is an easy and effective technique in wound closure to prevent postoperative CSF collection.

Key Words : Cerebrospinal fluid leak · Craniotomy · Scalp · Sutures.

INTRODUCTION

Major postoperative complications in intracranial lesions have greatly reduced with the introduction of modern neurosurgical devices and microsurgical techniques. However, cerebrospinal fluid (CSF) leakage after craniotomy occurs not infrequently and has continued to be the significant cause of minor postoperative complications such as wound dehiscence, local infection and meningitis. Most of the complications are well cured but in some cases, failure in infection control not only leads to prolonged hospitalization but also affects the patient's quality of life. To prevent these complications, various techniques such as the use of fibrin glue, preparation of galeal or pericranial flaps and prophylactic lumbar drain have been described^{3,11,16,17}. In this study, we introduce a surgical technique, so called "galeal tack-up suture" for the prevention of CSF collection in subgaleal space.

MATERIALS AND METHODS

This study included 87 patients who underwent craniotomy

for various lesions such as brain tumor, vascular and traumatic lesions from December 2012 to May 2013. The patients were randomly allocated to either one of the two groups, the wound closure with "galeal tack-up suture" (group A) or routine wound closure (group B). There were 32 patients in group A and 55 patients in group B. We prospectively compared the frequency of postoperative subgaleal CSF collection in two groups until the wound has been stitched out. All minor subgaleal CSF collections which could be easily cured by compression with elastic bandage were also included.

Surgical technique of galeal tack-up suture

In all patients, dural closure was done by interlocking or continuous suture method. Routine dural tack-up sutures are placed at the craniotomy margin to hold the dura against the bone edge in attempt to prevent postoperative epidural hematoma. Dural CSF leak was checked with intraoperative Valsalva maneuver in all cases to ensure the water-tight dural closure. After the bone flap has been fixed with cranial plate, central dural tenting suture passing through the small holes burred previously was made, to fix the dural flap to the bone flap. Upon closing the

• Received : July 1, 2013 • Revised : October 8, 2013 • Accepted : October 10, 2013

• Address for reprints : Chang Taek Moon, M.D., Ph.D.

Department of Neurosurgery, Konkuk University Medical Center, 120-1 Neungdong-ro, Gwangjin-gu, Seoul 143-729, Korea
Tel : +82-2-2030-7623, Fax : +82-2-2030-7359, E-mail : ctmoon@kuh.ac.kr

• This is an Open Access article distributed under the terms of the Creative Commons Attribution Non-Commercial License (<http://creativecommons.org/licenses/by-nc/3.0>) which permits unrestricted non-commercial use, distribution, and reproduction in any medium, provided the original work is properly cited.

scalp, one of the three methods of “galeal tack-up suture” was used (Fig. 1).

First method of “galeal tack-up suture” utilizes the pairs of small hole burred for central dural tenting suture. 4-0 vicryl attached to curved needle is passed through the hole from external side of bone flap to internal side, and then passed to external side again through the adjacent hole. For second method, pairs of V-shaped holes are burred on the surface of bone flap but not piercing through it. Third method utilizes the cranial plate used to fix the bone flap. Single piece of straight titanium plate can be installed independently to be used as an anchor. This anchor is especially useful in cases of suboccipital craniotomy or foramen magnum decompression where making of holes directly (straight or V-shaped) is difficult.

Three to five suture materials are prepared depending on the size of the bone flap. While closing the scalp in layer by layer fashion, galea aponeurotica is sutured with the bone flap using the previously prepared sutures (Fig. 2).

Statistical analysis

The chi-square test was used to test for an association between galeal tack-up suture and postoperative subgaleal CSF collection. The association between age and sex, and the incidence of subgaleal CSF collection was tested using the logistic regression test.

RESULTS

A total of 87 cases of craniotomy for intradural lesions were done in 75 patients. Six patients underwent repeated surgery for brain tumor, one of them for three times. Two patients underwent revision surgery for persistent CSF leakage, 1 patient underwent revision surgery for subdural empyema, and 2 patients underwent cranioplasty for craniectomy state in which dural tearing occurred while dissecting due to dura-galeal adhesion. There were 35 males and 40 females with mean age of 49 years old (range : 1-82). Intradural lesions included 32 cases of vascular lesion, 36 cases of brain tumor, 13 cases of trauma, 3 cases of congenital lesion, and 3 cases of infection (Table 1). Galeal tack-up suture was performed in 32 cases and routine wound closure without galeal tack-up was done in 55 cases. The three different galeal tack-up suture techniques were applied according to the size, location, and shape of the bone flap where it is appropriate.

Subgaleal CSF collection occurred in 13 (15%) of 87 cases. The frequency of subgaleal CSF collection was higher in infratentorial lesions (50%). Twelve cases occurred in group B patients where only routine wound closure was done and there was 1 case of postoperative CSF collection in group A patients with galeal tack-up suture. In supratentorial lesions, galeal tack-up suture tended to be effective ($p=0.051$) but was not proven statistically significant. However, galeal tack-up suture applied in total sum of cases showed significant value statistically ($p=0.026$) (Ta-

ble 2). Among 13 patients with subgaleal CSF collection, 8 patients were treated with percutaneous aspiration followed by compression with elastic bandage and 1 patient with lumbar drain. In 4 patients, routine treatment has failed to stop subgaleal CSF collection so revision surgery had to be done. There was no statistical significance between age ($p=0.401$), sex ($p=0.154$) and the incidence of subgaleal CSF collection.

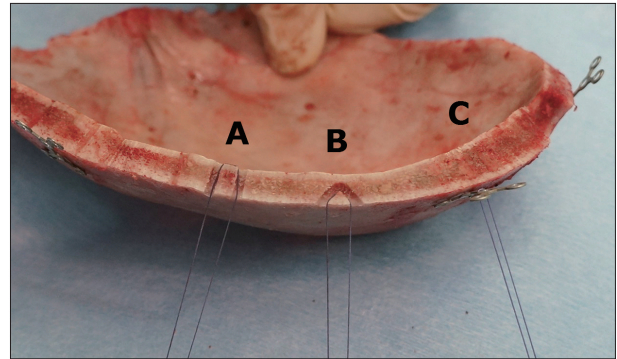


Fig. 1. Three different types of galeal tack-up sutures utilizing A : pair of straight holes burred for dural tenting, B : V-shaped holes, C : cranial plate for bone flap fixation.

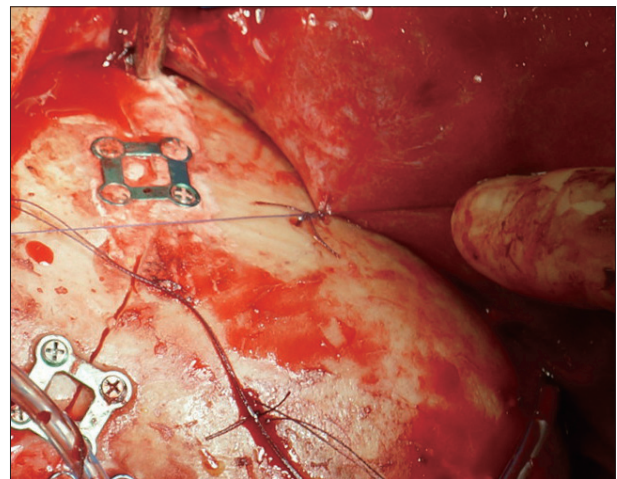


Fig. 2. Galeal fixation to the cranium with galeal tack-up sutures.

Table 1. Distribution by diagnosis of use of galeal tack-up suture

| Diagnosis | No. of patients | No. of cases with galeal tack-up suture |
|--------------------------|-----------------|---|
| Congenital | 3 | 1 |
| Infection | | |
| Brain abscess | 1 | 0 |
| Subdural empyema | 2 | 0 |
| Trauma | 13 | 6 |
| Tumor | 36 | 13 |
| Vascular | | |
| Intracerebral hemorrhage | 5 | 2 |
| Moyamoya disease | 3 | 1 |
| Subarachnoid hemorrhage | 17 | 7 |
| Unruptured aneurysm | 7 | 2 |

Table 2. Subgaleal CSF collection according to different locations of target lesions

| Location | Tack-up suture (+) | | Tack-up suture (-) | | p-value |
|----------------|--------------------|--------------------|--------------------|--------------------|---------|
| | CSF collection (+) | CSF collection (-) | CSF collection (+) | CSF collection (-) | |
| Supratentorium | 1 | 29 | 10 | 43 | 0.051 |
| Infratentorium | 0 | 2 | 2 | 0 | 0.333 |
| Total | 1 | 31 | 12 | 4 | 0.026 |

CSF : cerebrospinal fluid

DISCUSSION

Postoperative CSF leakage frequently results in CSF pooling in subgaleal space. CSF collected in subgaleal space can be diagnosed by several methods such as brain computed tomography, magnetic resonance imaging but it can also be detected by simply touching the operation site which feels like water-filled balloon⁸⁾. It is usually considered one of the minor postoperative complications but if left untreated, it can cause severe brain infection such as meningitis¹⁴⁾. It also results in prolonged hospital stay, increased treatment costs, and revision surgery in some cases^{12,14)}. Several methods have been reported for the treatment of CSF collection. Usually, it can be treated by bed rest with head elevation, percutaneous aspiration followed by compression with elastic bandage, and installation of lumbar drain but sometimes requires repeated surgery for CSF fistula^{6,9,14)}. Percutaneous aspiration and lumbar drain can also result in intracranial infection. It has been accepted that careful watertight dural closure is imperative procedure for prevention of postoperative CSF leakage after the operation for intradural lesion^{1,2,13)}. Application of fibrin glue on the dural suture line has also been known to be effective measure for prevention of postoperative CSF leakage^{10,15,17)}. But even with all the preventive measures, some cases of CSF leakage occurs in the operation for intradural lesions. Grotenhuis⁵⁾ reported that in the series of 412 patients of nontraumatic neurosurgical cases, postoperative CSF leakage occurred in 44 (10.7%) patients including self-limiting subcutaneous minor CSF collection. Kwon et al.⁷⁾ reported that in the series of 47 cases which underwent orbital roof craniotomy and superolateral orbital craniotomy, 13 (27.6%) cases of periorbital CSF collection had occurred.

CSF leaks through the dural suture lines and defects which were failed to close properly during the operation. Leaked CSF is pooled in epidural and subgaleal spaces and disrupts the adhesion between galea and cranial vault by creating dead space filled with CSF. Routine dural tenting suture are performed to prevent epidural hemorrhage. It can also prevent leaked CSF to pool in the epidural space. By performing galeal tack-up suture, single large subgaleal space is removed and divided into small multiple subgaleal spaces and galea becomes tightly adhered to the cranial vault which prevents CSF to pool. Goel⁴⁾ previously described ‘Tenting’ stitches for the scalp can effectively reduce subgaleal collection of CSF in 1991. They utilized pericranium-galeal tenting but we did not use it since the technique is more

difficult than galeal-cranium tenting and also the suture strength is weak. Kato et al. reported a CSF leak rate of 0.5% by using galea-cranium suture method in their technical note in 1999. They utilized v-shape holes and plate but the clinical data was not suggested. Among the surgical techniques suggested in the two technical reports, we chose

the appropriate methods to apply in clinical setting and the results were statistically analyzed. Our study indicated that galeal tack-up suture is an effective and easy-to-perform technique for prevention of postoperative subgaleal CSF collection which does not require additional costs.

All three techniques are essentially the same that aims to attach galea to the cranium and remove the space for CSF to pool. These different techniques can be chosen and applied in most of the craniotomies with different size, shape, and location of bone flaps where it is appropriate.

CONCLUSION

Even with only minor efforts, galeal tack-up suture can effectively prevent subgaleal CSF collection in surgical wound closure. In various situations of craniotomy, three different surgical techniques can be utilized appropriately.

• Acknowledgements

This work was supported by Konkuk University in 2013.

References

- Ahn JY, Kim SH : A new technique for dural suturing with fascia graft for cerebrospinal fluid leakage in transsphenoidal surgery. *Neurosurgery* 65 (6 Suppl) : 65-71; discussion 71-72, 2009
- Barth M, Tuettgenberg J, Thomé C, Weiss C, Vajkoczy P, Schmiedek P : Watertight dural closure : is it necessary? A prospective randomized trial in patients with supratentorial craniotomies. *Neurosurgery* 63 (4 Suppl 2) : 352-358; discussion 358, 2008
- Boudreaux B, Zins JE : Treatment of cerebrospinal fluid leaks in high-risk patients. *J Craniofac Surg* 20 : 743-747, 2009
- Goel A : ‘Tenting’ stitches for the scalp. *Br J Neurosurg* 6 : 357-358, 1992
- Grotenhuis JA : Costs of postoperative cerebrospinal fluid leakage : 1-year, retrospective analysis of 412 consecutive nontrauma cases. *Surg Neurol* 64 : 490-493, discussion 493-494, 2005
- Kato T, Sawamura Y, Abe H : Galea-cranium suture method for prevention of the subcutaneous fluid collection--technical note. *Neurol Med Chir (Tokyo)* 39 : 384-386, 1999
- Kwon YH, Park JH, Lee JS, Park MS, Ha HG : Periorbital cerebrospinal fluid collection after orbital roof craniotomy and superolateral orbital craniotomy. *J Korean Neurosurg Soc* 33 : 62-66, 2003
- Mantur M, Łukaszewicz-Zajac M, Mroczko B, Kułakowska A, Ganslandt O, Kemona H, et al. : Cerebrospinal fluid leakage--reliable diagnostic methods. *Clin Chim Acta* 412 : 837-840, 2011
- Murai Y, Mizunari T, Kobayashi S, Teramoto A : Surgical Technique for the Prevention of Cerebrospinal Fluid Leakage After Bifrontal Craniotomy. *World Neurosurg* 2013 Jan 11 [Epub ahead of print]
- Nakajima S, Fukuda T, Hasue M, Sengoku Y, Haraoka J, Uchida T : New

- technique for application of fibrin sealant : rubbing method devised to prevent cerebrospinal fluid leakage from dura mater sites repaired with expanded polytetrafluoroethylene surgical membranes. **Neurosurgery** 49 : 117-123, 2001
11. Raquet F, Mann WJ : [Lumbar cerebrospinal fluid drainage for prevention of cerebrospinal fluid fistulas]. **HNO** 41 : 335-338, 1993
 12. Rotenberg BW, Marchie A, Cusimano MD : Skin sealants : an effective option for closing cerebrospinal fluid leakage. **Can J Surg** 47 : 466-468, 2004
 13. Sakamoto N, Akutsu H, Takano S, Yamamoto T, Matsumura A : Useful 'sliding-lock-knot' technique for suturing dural patch to prevent cerebrospinal fluid leakage after extended transsphenoidal surgery. **Surg Neurol Int** 4 : 19, 2013
 14. Stieglitz LH, Wrede KH, Gharabaghi A, Gerganov VM, Samii A, Samii M, et al. : Factors affecting postoperative cerebrospinal fluid leaks after retrosigmoidal craniotomy for vestibular schwannomas. **J Neurosurg** 111 : 874-883, 2009
 15. Symon L, Pell MF : Cerebrospinal fluid rhinorrhea following acoustic neurinoma surgery. Technical note. **J Neurosurg** 74 : 152-153, 1991
 16. Yamakami I, Serizawa T, Yamaura A, Nakamura T : [Cerebrospinal fluid leak after cranial base surgery]. **No Shinkei Geka** 24 : 29-33, 1996
 17. Yoshimoto T, Sawamura Y, Houkin K, Abe H : Effectiveness of fibrin glue for preventing postoperative extradural fluid leakage. **Neurol Med Chir (Tokyo)** 37 : 886-889; discussion 889-890, 1997