

Case Report

A Long-Term Survival Case of a Primary Malignant Intracerebral Nerve Sheath Tumor

Byung Sun Lee, M.D., Young Gyu Kim, M.D., Ph.D., Dong Ho Kim, M.D., Ph.D., Mou Seop Lee, M.D., Ph.D.

Department of Neurosurgery, Chungbuk National University School of Medicine & Medical Research Institute, Cheongju, Korea

We report a long-term survival case of a primary malignant intracerebral nerve sheath tumor (MINST) occurring in the right frontal lobe of a 13-year old boy. After the gross total resection (GTR), we have performed radiation therapy but it recurred 50 months after the surgery, so the second GTR was performed. Later, second tumor recurrence was found 4 months after the second surgery. Subsequently the third GTR, radiotherapy, and chemotherapy were carried out. At present, the patient has been remaining alive for 77 months without evidence of tumor recurrence. According to the previous reports, the primary MINST is very rare : there are only 8 cases reported. It is also a fast-growing, invasive tumor with poor outcome. This is the first case that had no recurrence for 50 months after the surgery among the reported cases that had been followed up for more than 5 years. It is supposed that a period of recurrence free survival after GTR and low mitotic activity are associated with the patient's prognosis. A GTR followed by adjuvant radiation therapy and chemotherapy will be recommended to patients of MINST.

Key Words : Malignant intracerebral nerve sheath tumor · Gross total resection · Radiotherapy · Chemotherapy.

INTRODUCTION

Malignant peripheral nerve sheath tumors (MPNST), which are comprised of 5 to 10% of all soft-tissue sarcoma, often occur in the near proximal extremity at a nerve trunk such as sciatic nerve, brachial plexus, or sacral plexus. They have a distinct association with the neurofibromatosis type 1 and occur in 3-15% of NF1 patients and a high incidence of tumor is related to the mutation of the *NF1* gene⁹⁾. On the other hand, a primary malignant intracerebral nerve sheath tumor (MINST) is quite rare, with only 8 cases^{1,2,4,10,12,13,15,16)} documented in English-language literature. We report on a case of MINST and the relevant literature is reviewed.

CASE REPORT

Clinical course

A 13-year-old boy was hospitalized due to the headache on the right side of his head, which began 2 weeks ago and the vomiting, which began a week ago. The patient was alert and

showed no neurologic abnormalities. There was no evidence of neurofibromatosis such as neurofibroma, café au lait spot, Lisch nodule, optic glioma, distinctive bony lesion (dysplasia of the sphenoid bone or long bone cortex) and freckle in the groin or axilla with no family history of neurofibromatosis. Brain magnetic resonance imaging (MRI) revealed about 6.7 cm diameter, a well defined highly enhancing mass in the right frontal lobe (Fig. 1). The preoperative differential diagnoses were glioblastoma multiforme, anaplastic astrocytoma, and malignant meningioma. A surgical resection was carried out through right frontal craniotomy.

Diagnosis

Macroscopically, it was a well-circumscribed yellowish nodular round mass having gelatinous surface without dural attachment (Fig. 2). It was intra-parenchymal tumor and had a distinct cleavage plane in the superficial brain parenchyma, but not in the deeper portion. Microscopically, the tumor was highly cellular and mainly consisted of spindle cells in interlacing and interwoven fascicles. Perivascular whirling and condensa-

• Received : May 28, 2013 • Revised : August 28, 2013 • Accepted : September 15, 2013

• Address for reprints : Mou Seop Lee, M.D., Ph.D.

Department of Neurosurgery, College of Medicine and Medical Research Institute, Chungbuk National University, 12 Gaeshin-dong, Heungduk-gu, Cheongju, Chungbuk 361-763, Korea

Tel : +82-43-269-6378, Fax : +82-43-273-1614, E-mail : mslee@chungbuk.ac.kr

• This is an Open Access article distributed under the terms of the Creative Commons Attribution Non-Commercial License (<http://creativecommons.org/licenses/by-nc/3.0>) which permits unrestricted non-commercial use, distribution, and reproduction in any medium, provided the original work is properly cited.

tion of tumor cells were observed. The tumor was well-demarcated from the adjacent brain tissues. Each tumor cell had a fusiform nucleus and aligned in a convoluted form with a moderate degree of mitotic activity and a high nuclear-to-cytoplasmic ratio. Myxoid parts were scattered in the tumor (Fig. 3).

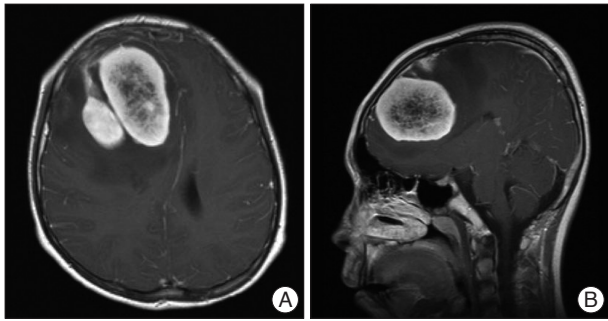


Fig. 1. Pre-operation brain MRI. Axial (A) and sagittal (B) T1-weighted enhanced images demonstrating a multilobulated mass with peripheral enhancement, central necrosis and peritumoral edema in the right frontal lobe.

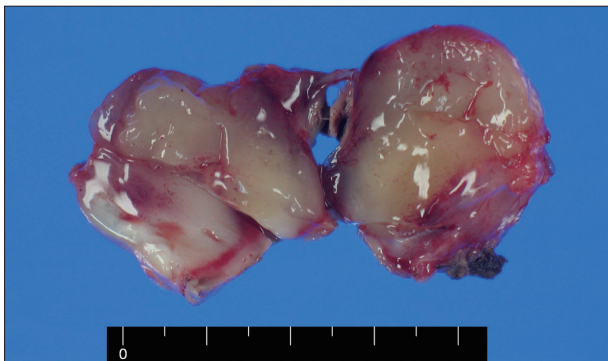

Fig. 2. Gross appearance of the tumor showing a well-circumscribed yellowish and nodular round mass with gelatinous surface.

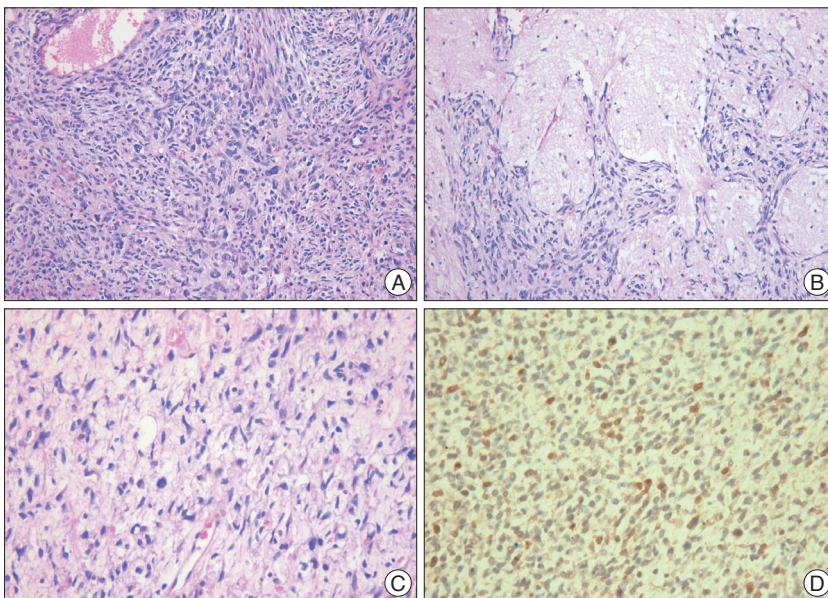


Fig. 3. A : The tumor was highly cellular, consisting mainly of spindle cells in interlacing and interwoven fascicles (HE stain, original magnification $\times 100$). B : Myxoid part in the tumor are scattered (HE stain, original magnification $\times 200$). C : Moderate nuclear mitotic figures (HE stain, original magnification $\times 400$). D : The tumor cells are positive for S-100 protein (immunostaining of S-100 protein, original magnification $\times 200$).

form nucleus and aligned in a convoluted form with a moderate degree of mitotic activity and a high nuclear-to-cytoplasmic ratio. Myxoid parts were scattered in the tumor (Fig. 3).

Immunohistochemistry showed that the tumor cell was positive for S100 (Fig. 3), but negative for glial fibrillary acidic protein (GFAP), CD34, synaptophysin and desmin. These histological and immunohistochemical findings supported the diagnosis of a primary MINST.

Postoperative treatment

Thirty times of fractionated whole-brain radiation were performed with 5760 cGy over the period of 6 weeks after surgery. Brain MRI follow-up examination was performed every six months, but there was no evidence of tumor recurrence. Brain MRI at 50 months after his first surgery revealed a 1.0 \times 1.0 cm of well-defined enhancing mass in the right frontal convexity and leptomeningeal enhancement in the right frontal area (Fig. 4). Whole spinal MRI showed no evidence of metastasis. No malignant cell was observed in his cerebrospinal fluid study. Second gross total resection (GTR) was performed. The histopathological examination showed a primary MINST, which was consistent with the histopathological results from the first surgery. The brain MRI at four months after second surgery revealed a tumor of 1.0 \times 0.5 cm in size in the right anterior frontal convexity and pachymeningeal enhancement in the right frontal area (Fig. 5A). As the patient's guardian wanted to treat the patient in another hospital, so the patient was transferred to another hospital. Third GTR was carried out. The histopathological examination also showed a primary MINST. As the tumor was repeatedly relapsed despite the GTR which was performed

twice before, radiation therapy and chemotherapy were performed according to the Korean Society for Pediatric Neuro-Oncology (KSPNO)-S081 Protocol, which can be used for a high-grade brain tumor¹³. Thirty times of fractionated radiation were carried out with 6000 cGy after his third surgery and 4 times of combination chemotherapy with vincristine (1.5 mg/m² IV push, Day 0, 7), etoposide (75 mg/m² in normal saline dose $\times 2.5$ times IV over 2 hours, Day 0-4), carboplatin (300 mg/m² in normal saline 125 mL/m² IV over 1 hour, Day 0, 1), and ifosfamide (1500 mg/m² in dextrose water 200 mL/m² with Mesna (300 mg/m² IV over 1 hour, Day 0-4) were applied. The irregular enhancing lesion (3.0 \times 4.0 cm) was found in a brain MRI at six months after the third surgery (Fig. 5B). As the size of this lesion was found to be smaller than the previous one in the brain MRI at

thirteen months after the third surgery, this lesion is considered to be the result of radiation injury rather than tumor recurrence (Fig. 5C). He is still alive at 77 months after his first surgery and complaining of mild headache and dizziness, but there are no other neurological abnormalities.

DISCUSSION

The primary MINST is termed as a result of their histological and immunohistochemical similarities to MPNST but is distinguished by their intracerebral location¹. MINST is a preferable term to indicate malignant intracerebral schwannoma or neurofibrosarcoma, since these tumors have the appearance of any nerve sheath cells, including Schwann cells, perineural fibroblasts, or fibroblasts^{8,10}. Patients with MINST have little probability of concomitant findings of NF1¹⁶.

Neither our case nor the other previously-published case reports could make an accurate diagnosis before pathologic findings. In imaging studies such as brain computed tomography and MRI, it is difficult to discriminate between MINST and high grade glioma, because those tumors were intra-axial, homogeneously enhancing and had surrounding edema¹¹.

It is difficult to make an accurate diagnosis of MINST by looking ordinary hematoxylin and eosin-stained sections alone. The differential diagnosis of these tumors includes malignant melanomas with Schwann-type differentiation, mixed gliomas with mesenchymal differentiation, intracerebral rhabdomyosarcomas, desmoplastic infantile ganglioma, intracerebral meningioma, and solitary fibrous tumor^{2,16}. Isolated immunospecific marker for nerve sheath tumors was nonexistent. However, immunohistochemical analysis has special value both in verifying nerve sheath derivation and malignancy¹⁶. It is essential for distinguishing MPNST from the other malignant spindle cell tumors¹². Positive S-100 protein may help in differentiating the nerve

sheath tumors from the other soft tissue tumors⁶. The absence of GFAP expression in tumor cells ruled out desmoplastic astrocytoma, gliofibroma, and gliosarcoma, whereas the absence of synaptophysin and neurofilament protein excluded desmoplastic ganglioglioma¹².

In the reported cases, the prognosis of MINST is poor². According to the data in Table 1, survival time was longer when the tumor recurrence was slower. As the tumor recurrence became faster, the prognosis got worse. The recurrence free survival after the initial resection appears an important predictor of the overall survival¹². In cases of Bruner et al.⁴, Barnard et

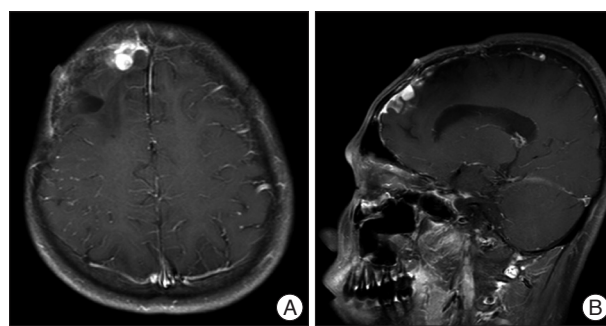


Fig. 4. Brain MRI, 50 months after first operation. Axial (A) and sagittal (B) T1-weighted post-contrast image shows 1.0×1.0 cm sized well-defined enhancing nodule at right frontal convexity and leptomeningeal enhancement in right frontal area.

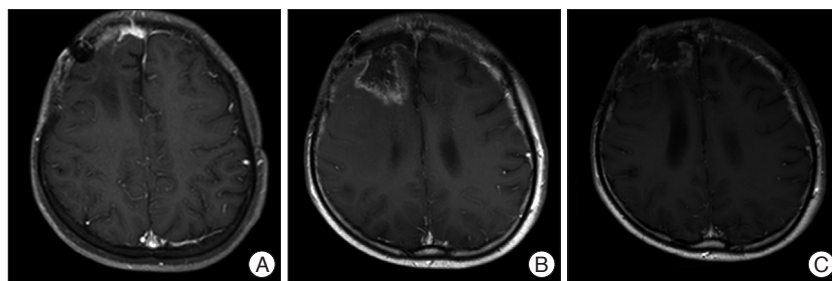


Fig. 5. Brain MRI, fourth months after second operation (A), six months after third operation (B), and 13 months after third operation (C). A : T1-weighted post-contrast image reveals localized enhancing mass at right anterior frontal convexity and pachymeningeal enhancement at right frontal area. B : A lesion in the size of 3.0×4.0 cm is found at right frontal lobe, which had unclear boundaries, shows peripheral irregular enhancement, and is accompanied by central necrosis. C : As the size of irregular enhancing lesion is found to be smaller than previous one, it is assumed that this lesion is a result of radiation injury rather than tumor recurrence.

Table 1. Literatures review of malignant intracerebral nerve sheath tumor

Reference	Age, sex	Tumor site	Surgery	Mitotic activity	Ch	RT	Recurrence	Outcome
Bruner et al. ⁴	18, M	Frontal	GTR	Rare	N	N	24, 48, 66 months	>66 months
Stefanko et al. ¹⁴	15, M	Parietooccipital	GTR	High	Y	Y	5, 8 months	9 months, dead
Singh et al. ¹³	61, F	Cerebellum	GTR	High	N	Y	8 months	18 months, dead
Sharma et al. ¹²	8, F	Temporal	GTR	Variable	N	Y	None	17 months, unknown
Tanaka et al. ¹⁵	4, F	Parietooccipital	GTR	High	N	N	None	19 months, unknown
Beauchesne et al. ²	35, M	Cerebral peduncle	Biopsy	Scarce	Y	Y	17 months	29 months, dead
Kozic et al. ¹⁰	39, M	Pons	Biopsy	Not reported	N	N	Not reported	Not reported
Barnard et al. ¹	75, F	Frontal	GTR	Moderate	N	Y	None	>26 months
Present study	13, M	Frontal	GTR	Moderate	Y	Y	50, 54 months	>77 months

Ch : chemotherapy, RT : radiotherapy, GTR : gross total resection

al.¹⁾, and this case which reported long-term survival, the mitotic activity was rare or moderate rather than high. It seems that if the mitotic activity is low, the recurrence rate is also low and thus the survival time will increase, although we could not take into account of various factors due to insufficient data caused by few number of reports have been produced to date.

The extent of resection seems to be important in the prognosis of MPNST. A longer survival time was reported when total resection rather than subtotal resection was carried out^{3,7,16)}. Also, in MINST, GTR has always been proposed in the literature^{1,2,6,15)}.

It was considered that radiotherapy contributed to playing a limited role in the management of tumor in the early literature^{14,15)}. However, in the recent literature, radiotherapy showed possible effects on the local control and recurrence^{2,5)}, but little on the overall survival in patients with MINST^{1,16)}.

In case of Beauchesne et al.²⁾, systemic chemotherapy with doxorubicin (3 courses every month) was prescribed, with mild benefit for the patient. However, because of the rarity of this tumor type, there are still few reports published and little available information about the chemotherapy⁸⁾. In this case, the KSPNO-SO81 protocol was applied, which is one of protocols to treat a pediatric high grade brain tumor such as medulloblastoma and primitive neuroectodermal tumor. Although appropriate regimen of radiation therapy and chemotherapy are not determined yet^{2,5,15)}, it is considered to be useful for the long-term survival of the patient to carry out a surgery, adjuvant radiation, and chemotherapy, as shown in this case.

CONCLUSION

We report a long-term survival case of a primary MINST. Different from the previous cases, this is the first case that had no evidence of tumor recurrence for 50 months after first surgery, and showed long-term survival for more than 77 months without showing no evidence of tumor recurrence. Although a definitive therapeutic regimen for MINST has not yet been established due to the limited number of reported cases, a GTR followed by adjuvant radiotherapy and chemotherapy will be recommended to patients of MINST.

• Acknowledgements

This work was supported by the research grant of the Chungbuk National University in 2011.

References

1. Barnard ZR, Agarwalla PK, Jeyaretna DS, Farrell CJ, Gerstner ER, Tian D : Sporadic primary malignant intracerebral nerve sheath tumor : case report and literature review. *J Neurooncol* 104 : 605-610, 2011
2. Beauchesne P, Mosnier JF, Schmitt T, Brunon J : Malignant nerve sheath tumor of the right cerebral peduncle : case report. *Neurosurgery* 54 : 500-504, 2004
3. Bhattacharyya AK, Perrin R, Guha A : Peripheral nerve tumors : management strategies and molecular insights. *J Neurooncol* 69 : 335-349, 2004
4. Bruner JM, Humphreys JH, Armstrong DL : Immunocytochemistry of recurring intracerebral nerve sheath tumor. *J Neuropathol Exp Neurol* 43 : 1, 1984
5. Carli M, Ferrari A, Mattke A, Zanetti I, Casanova M, Bisogno G, et al. : Pediatric Malignant Peripheral Nerve Sheath Tumor : The Italian and German Soft Tissue Sarcoma Cooperative Group. *J Clin Oncol* 20 : 8422-8430, 2005
6. Chen L, Mao Y, Chen H, Zhou LF : Diagnosis and management of intracranial malignant peripheral nerve sheath tumors. *Neurosurgery* 62 : 825-832, 2008
7. Ducatman BS, Scheithauer BW, Piepgras DG, Reiman HM, Ilstrup DM : Malignant peripheral nerve sheath tumors. A clinicopathologic study of 120 cases. *Cancer* 57 : 2006-2021, 1986
8. Enzinger FM, Weiss SW : Malignant tumor of the peripheral nerves, in Enzinger FM, Weiss SW (eds) : *Soft Tissue Tumors*, ed 3. St Louis, MO, CV Mosby, 1995, pp889-928
9. Kim ET, Namgung H, Shin HD, Lee SI, Kwon JE, Chang MC, et al. : Oncologic manifestations of neurofibromatosis type 1 in Korea. *J Korean Surg Soc* 82 : 205-210, 2012
10. Kozic D, Nagulic M, Samardzic M, Ostojic J, Rasulic L, Cvetkovic-Dozic D : Intrapontine malignant nerve sheath tumor : MRI and MRS features. *Acta Neurol Belg* 108 : 67-71, 2008
11. Rees J : Advances in magnetic resonance imaging of brain tumors. *Curr Opin Neurol* 16 : 643-650, 2003
12. Sharma S, Abbott RI, Zagzag D : Malignant intracerebral nerve sheath tumor : A case report and review of the literature. *Cancer* 82 : 545-552, 1998.
13. Shin HY : Korean society for pediatric neuro-oncology (KSPNO). *Korean J pediatr Hematol Oncol* 12 : 188-200, 2005
14. Singh RVP, Suys S, Campbell DA, Broome JC : Malignant schwannoma of the cerebellum: case report. *Surg Neurol* 39 : 128-132, 1993
15. Stefanko SZ, Vuzevski VD, Maas AI, van Vroonhoven CC : Intracerebral malignant schwannoma. *Acta Neuropathol* 71 : 321-325, 1986
16. Tanaka M, Shibui S, Nomura K, Nakanishi Y, Hasegawa T, Hirose T : Malignant intracerebral nerve sheath tumor with intratumoral calcification. Case report. *J Neurosurg* 92 : 338-341, 2000