

Case Report

Intracranial Calcification Caused by a Brain Abscess : A Rare Cause of Intracranial Calcification

Hyeun Sook Kim, M.D., Ph.D.,^{1*} Dong Min Kim, M.D., Ph.D.,¹ Chang Il Ju, M.D., Ph.D.,² Seok Won Kim, M.D., Ph.D.²

Departments of Internal Medicine,¹ Neurosurgery,² College of Medicine, Chosun University, Gwangju, Korea

Intracranial calcifications are relatively common computed tomographic findings in the field of neurosurgery, and cysticercosis, tuberculosis, HIV, and cryptococcus are acquired intracranial infections typically associated with calcifications. However, intracranial calcification caused by a bacterial brain abscess is rare. Here, we present a rare case of intracranial calcification caused by a bacterial brain abscess, from which staphylococcus hominis was isolated. To the best of our knowledge, no previous report has been published on intracranial calcification caused by bacterial brain abscess after decompressive craniectomy for traumatic brain injury. In this article, the pathophysiological mechanism of this uncommon entity is discussed and relevant literature reviewed.

Key Words : Brain abscess · Calcification.

INTRODUCTION

Intracranial calcifications observed by computed tomography (CT) are the most common incidental finding in the everyday practice of neurosurgery, because non-contrast enhanced CT of the brain is the preferred imaging modality worldwide for the initial evaluation of patients with head injury. Cysticercosis, tuberculosis, and cryptococcus are acquired intracranial infections typically associated with intracranial calcification^{3,6)}, whereas calcification resulting from a brain abscess is extremely rare. We represent a rare case of an unusually calcified brain abscess, from which staphylococcus hominis was isolated, and include a review of the literature.

CASE REPORT

A previously healthy 40-year-old man presented with mental deterioration after a head injury. On neurological examination, he was stuporous with a Glasgow Coma Scale of 8. Routine hematological and serum chemistry testing, including erythrocyte sedimentation rate and C-reactive protein, revealed no abnormality. However, CT scan of the brain revealed severe brain

swelling and hemorrhagic contusion in the right frontotemporo-parietal (FTP) region. He underwent emergent decompressive craniectomy on the right FTP region (Fig. 1). Postoperatively, he became conscious and was able to obey commands without any neurologic deficit. However, three weeks later, he complained of a febrile sensation and had a temperature of 38.4°C. A CT scan of the brain with intravenous contrast showed a ring-enhanced brain abscess (Fig. 2). Third generation cephalosporin and sufficient hydration were continuously administered. However, despite this management, the fever continued and he complained of mild left hemiparesis (Grade IV+/Grade IV+). A CT scan and magnetic resonance imaging (MRI) with intravenous contrast on hospital day 35 revealed an increase in both the size and extent of the brain abscess (Fig. 3). Navigation-guided culture and biopsy following drainage of the brain abscess using a 5 L catheter were performed. A dark yellowish pus was drained from the abscess. Gram stain and acid-fast bacilli cultures were negative and revealed no organisms. No evidence of granulomas or larval cysts were seen. However, from cultures of the purulent drainage on blood agar, coagulase negative staphylococcus hominis was isolated. His antibiotics were changed to nafcillin and ciprofloxacin based on the results of

• Received : January 3, 2013 • Revised : May 8, 2013 • Accepted : August 1, 2013

* Move to : Department Internal Medicine, Soonchunhyang University College of Medicine, Seoul, Korea

• Address for reprints : Seok Won Kim, M.D., Ph.D.

Department of Neurosurgery, School of Medicine, Chosun University, 365 Pilmun-daero, Dong-gu, Gwangju 501-717, Korea

Tel : +82-62-220-3126, Fax : +82-62-227-4575, E-mail : chosunns@chosun.ac.kr

• This is an Open Access article distributed under the terms of the Creative Commons Attribution Non-Commercial License (<http://creativecommons.org/licenses/by-nc/3.0>) which permits unrestricted non-commercial use, distribution, and reproduction in any medium, provided the original work is properly cited.

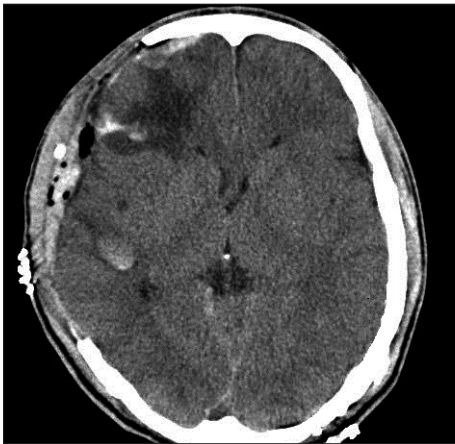

Fig. 1. Postoperative computed tomography scan shows successful removal of subdural hematoma after decompressive craniectomy.

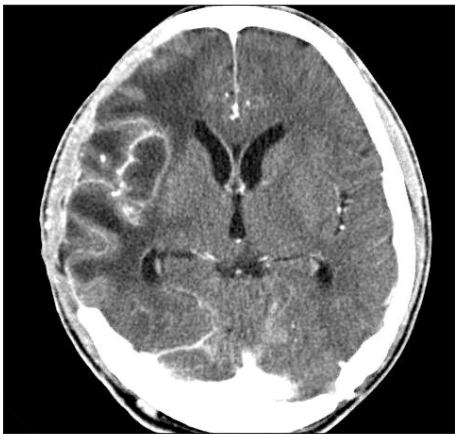

Fig. 2. Contrast enhanced CT scan taken 3 weeks later reveals appearance of an intracerebral abscess with a thin walled cavity.

culture test, and after 6 weeks on antibiotics, he achieved complete clinical recovery except for mild hemiparesis. However, follow-up CT performed 5 months after admission revealed that the brain abscess had developed into a large calcified mass (Fig. 4). Because of its deep-seated location and a lack of clinical symptoms, surgical removal was not performed. Instead, a series of CT scans were taken 3 monthly. No change in either the size or extent of the calcified region was observed over 2 year of follow-up. The patient remains symptom free with mild hemiparesis (Fig. 5).

DISCUSSION

Brain abscess is a focal, intracerebral infection that begins as a localized area of cerebritis and develops into a collection of pus surrounded by a well-vascularized capsule⁵. Brain abscesses develop in response to parenchymal infections by pyogenic bacteria and begin as a localized area of suppuration. Most commonly, infectious agents gain access to the central nervous system from a contiguous site of infection⁴. It is well known that a number of intracranial infections, such as, tuberculosis and cys-

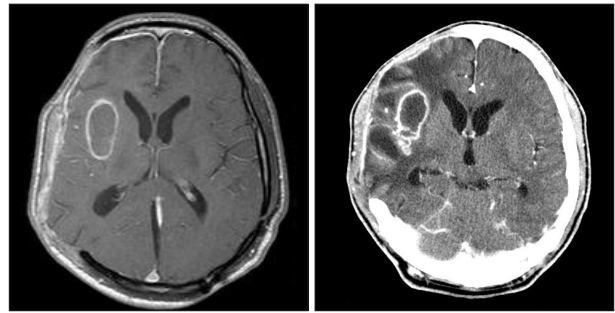


Fig. 3. Gadolinium enhanced magnetic resonance image and contrast enhanced CT taken 35 days later show an increase in both the size and extent of the brain abscess.

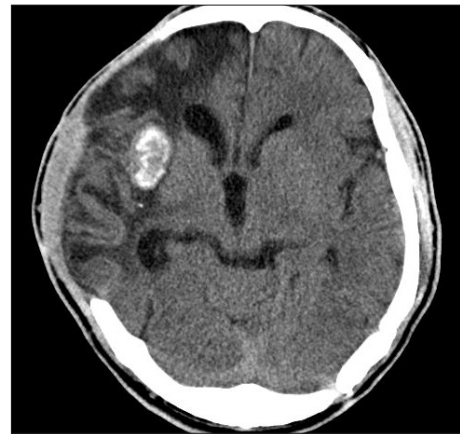

Fig. 4. After navigation-guided drainage of the abscess, CT scan performed 5 months after admission show calcified brain abscess.

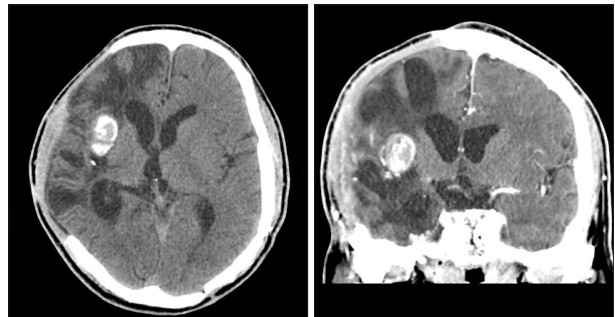


Fig. 5. Axial and coronal CT scans taken 2 years after admission show remained calcified brain abscess.

ticercosis, can cause intracranial calcifications^{1,12}). However, bacterial brain abscesses rarely calcify and CT findings of calcified brain abscesses have seldom been reported. The features of cerebral abscesses unveiled by MRI reflect the underlying pathophysiology of abscess formation. During the initial cerebritis stage, an ill-defined subcortical hyperintense zone on T2-weighted images is associated with poorly delineated enhancing areas within an iso- to mildly hypointense edematous region on enhanced T1-weighted images. During the early and late stages, a collagenous abscess capsule is visible on unenhanced scans as a comparatively thin-walled, well-delineated iso- to slightly hyperintense ring that becomes hypointense on T2-weighted im-

ages. Nonetheless, a ring-enhancing mass is a nonspecific imaging finding that may be seen in various noninflammatory benign and neoplastic processes¹⁰. The differential diagnosis includes primary brain tumors (e.g., necrotic glioblastoma), metastases, resolving hematoma, infarction, and even demyelinating disease, and the differential diagnoses of calcified ring lesions are tuberculoma, calcified hematoma, hydatid cyst, and brain abscess^{2,9,11}). Furthermore, calcified brain abscesses should be differentiated from noninfectious diseases, such as, calcified hemangioma calcificans, glioma with calcification, and calcified chronic subdural hematoma⁸). Rizvi et al.¹¹ reported large brain abscess with calcified rim predisposed by meningitis. They presumed that long course of development allowed for the formation of the calcified rim of abscess and this resulted in seizures. In our patient, a brain abscess caused by coagulase negative staphylococcus hominis resulted in no neurological sequelae and calcification at the healed abscess site. Coagulase negative staphylococci are a heterogeneous group of organisms comprising 32 species. Among them, staphylococcus hominis is a component of normal human flora, and is common in the axillary and pubic areas, where apocrine glands are numerous⁷. This case is rare in some respects. First, as far as we are aware, this is the first report of a brain abscess caused by staphylococcus hominis after decompressive surgery. Second, the causative pathogen of brain abscess was identified continuous antibiotics treatment. Third, full recovery was achieved after antibiotic therapy without removal of the calcified brain abscess. Although the exact cause of the calcification is not clear, this case shows a relationship between intracranial calcification and a brain abscess caused by staphylococcus hominis after decompressive craniectomy for traumatic subdural hematoma.

CONCLUSION

We report a rare case of intracranial calcification caused by bacterial brain abscess. Although rare, bacterial brain abscess should be borne in mind as a possible cause of intracranial calcification.

References

1. Alkan A, Parlak M, Baysal T, Sigirci A, Kutlu R, Altinok T : En-plaque tuberculomas of tentorium in a pregnant woman : follow-up with MRI (2003:2b). *Eur Radiol* 13 : 1190-1193, 2003
2. Cambria S, Salpietro F, Cambria M : Calcified brain abscesses. Case report. *J Neurosurg Sci* 28 : 103-105, 1984
3. Deepak S, Jayakumar B, Shanavas : Extensive intracranial calcification. *J Assoc Physicians India* 53 : 948, 2005
4. Falcone S, Post MJ : Encephalitis, cerebritis, and brain abscess : pathophysiology and imaging findings. *Neuroimaging Clin N Am* 10 : 333-353, 2000
5. Gortvai P, De Louvois J, Hurley R : The bacteriology and chemotherapy of acute pyogenic brain abscess. *Br J Neurosurg* 1 : 189-203, 1987
6. Kieffer SA, Gold LH : Intracranial physiologic calcifications. *Semin Roentgenol* 9 : 151-162, 1974
7. Kloos W E. Taxonomy and systematics of staphylococci indigenous to humans in Crossley B, Archer GL (eds) : **The staphylococci in human disease**. New York : Churchill Livingstone, 1997
8. Ludwig B, Nix W, Lanksch W : Computed tomography of the "armored brain". *Neuroradiology* 25 : 39-43, 1983
9. Nitta H, Tachibana O, Hayashi Y, Oki H : Unusually large calcified brain abscess : CT findings. *J Comput Assist Tomogr* 14 : 485-486, 1990
10. Osborn AG : Pyogenic parenchymal infections in Osborn AG (ed) : **Diagnostic Neuroradiology**. St. Louis : Mosby, 1994, pp668-692
11. Rizvi T, Garg A, Singh M, Sharma MC : Large intracranial mass with a calcified rim - is it a brain abscess? *Pediatr Neurosurg* 41 : 112-114, 2005
12. Wasay M, Kheleani BA, Moolani MK, Zaheer J, Pui M, Hasan S, et al. : Brain CT and MRI findings in 100 consecutive patients with intracranial tuberculoma. *J Neuroimaging* 13 : 240-247, 2003