

## Case Report

# Pulsed Radiofrequency Neuromodulation for the Treatment of Saphenous Neuralgia

Bo Ram Han, M.D.,<sup>1</sup> Hyuk Jai Choi, M.D.,<sup>1</sup> Min Ki Kim, M.D.,<sup>2</sup> Yong-Jun Cho, M.D.<sup>1</sup>

*Department of Neurosurgery,<sup>1</sup> Chuncheon Sacred Heart Hospital, Hallym University College of Medicine, Chuncheon, Korea*

*Department of Neurosurgery,<sup>2</sup> College of Medicine, Kyung-Hee University, Seoul, Korea*

A 65-year-old male presented with pain in his right medial calf. An imaging study revealed no acute lesions, and a diagnosis of saphenous neuralgia was made by a nerve conduction study. He received temporary pain relief with saphenous nerve blocks twice in a one-week interval. Pulsed radiofrequency neuromodulation reduced pain to 10% of the maximal pain intensity. At 6 months after the procedure, the pain intensity was not aggravated even without medication. Pulsed radiofrequency neuromodulation of the saphenous nerve may offer an effective and minimally invasive treatment for patients with saphenous neuralgia who are refractory to conservative management.

**Key Words :** Neuromodulation · Pulsed radiofrequency · Saphenous neuralgia.

## INTRODUCTION

Saphenous neuralgia (SN) is a rare clinical syndrome characterized by a tingling sensation, pain, or a burning sensation in the medial calf resulting from entrapment of the saphenous nerve<sup>8,12,15,16</sup>. The saphenous nerve is a purely sensory nerve, so no associated motor or reflex problems are present in patients with SN<sup>15</sup>.

In many patients with SN, satisfactory pain relief is expected from conservative treatments, such as medications or nerve blocks<sup>15,18</sup>. However, the effects of nerve blocking are generally temporary, and a small group of patients show medically intractable pain. More aggressive treatment tools have been considered for such patients, including neurolysis and neurectomy of the saphenous nerve<sup>12,13,17,19</sup>. However, surgical procedures are invasive and risk further complications.

In this case, we treated a patient with medically intractable SN by pulsed radiofrequency (PRF) and found that it was an effective and low-risk alternative treatment.

## CASE REPORT

A 65-year-old male presented with severe pain and a tingling

sensation in the right medial knee, calf, and ankle. He walked with a limp due to pain but not weakness. The patient had experienced severely disabling conditions for over 1 month. The pain and tingling sensation occurred every 5-10 minutes and lasted more than 5 minutes per episode. A neurological examination was normal, except for severe pain and tingling sensation in the right medial knee, calf, and ankle.

Lumbar magnetic resonance imaging (MRI) revealed no acute lesions except for distal degenerative changes at multiple levels. Knee MRI revealed no acute lesion except for mild degenerative osteoarthritis. A nerve conduction study revealed an absence of a right saphenous response in both the medial leg and the infrapatellar region, while normal findings were recorded from the left side. Electromyography was normal for all muscles tested. Before visiting our outpatient clinic, the patient had undergone a variety of treatments, including medication, an intra-articular injection for knee pain, and acupuncture around the right knee and medial calf. However, his symptoms did not improve but instead progressed. Saphenous nerve blocks using a local anesthetic and steroids were performed twice at 1-week intervals with fluoroscopy in our clinic. The target sites of nerve blocks were two point, the saphenous nerve around adductor's canal and the sartorial branch of the saphenous nerve around

• Received : September 10, 2012 • Revised : April 28, 2013 • Accepted : August 1, 2013

• Address for reprints : Hyuk Jai Choi, M.D.

Department of Neurosurgery, Chuncheon Sacred Heart Hospital, Hallym University College of Medicine, 77 Sakju-ro, Chuncheon 200-704, Korea  
Tel : +82-33-240-5171, Fax : +82-33-242-9970, E-mail : painsurgery@gmail.com

• This is an Open Access article distributed under the terms of the Creative Commons Attribution Non-Commercial License (<http://creativecommons.org/licenses/by-nc/3.0>) which permits unrestricted non-commercial use, distribution, and reproduction in any medium, provided the original work is properly cited.

superficial saphenous vein. These blocks provided temporary pain relief that lasted about 3 days. After the positive results of the diagnostic nerve blocks, the patient was scheduled for PRF neuromodulation of the saphenous nerve.

We performed fluoroscopically guided selective saphenous nerve PRF using a model NT1000 radiofrequency generator (NeuroTherm, Middleton, MA, USA). In the operating room, the patient was supine, with the right leg positioned with hip external rotation, hip abduction, and knee flexion. We drew a hypothetical line for the saphenous nerve (complete nerve, infrapatellar branch, and sartorial branch) and the trajectory for the cannula on his leg (Fig. 1). The target site was prepped with betadine and aseptically draped, and the right knee joint and epicondyle were identified under C-arm fluoroscopy. Disposable 20-gauge, 10-cm radiofrequency cannulas (Model S-1505; NeuroTherm) with a 5-mm active tip were inserted at the level of the adductor's canal and below the epicondyle. The introducer needles were withdrawn, and a Model RFDE-15 disposable radiofrequency electrode (NeuroTherm) was advanced (Fig. 2).

Selective stimulation of the sensory fibers (50 Hz) showed concordant pain between 0.3-0.5 V, which confirmed proper localization of the PRF electrode. Motor stimulation was negative. After stimulation, PRF neuromodulation was performed for 240 pulses. The maximal temperature was 42°C. After the procedure, the pain measured on a visual analog scale had decreased by 90% without medication. The pain relief was maintained for 6 months of follow-up without medication.

## DISCUSSION

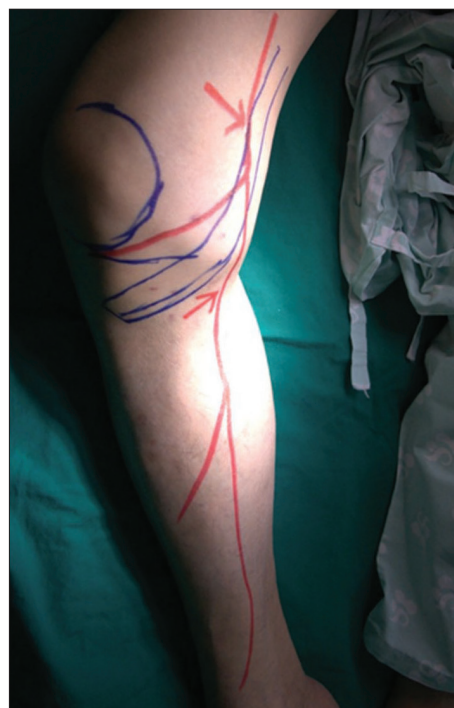### General aspect of saphenous neuralgia

Kopell and Thompson<sup>10</sup> first described SN in 1960. Patients with saphenous mononeuropathy experience pain and sensory disturbances within the distribution of the saphenous nerve without motor symptoms. Patients also complain of progressive paresthesias or hypoesthesia<sup>12</sup>. The etiology of SN can be categorized as idiopathic, traumatic, intrinsic, and iatrogenic causes<sup>1-3,11</sup>. Patients complain of medial knee and/or leg pains that are worsened by prolonged activity.

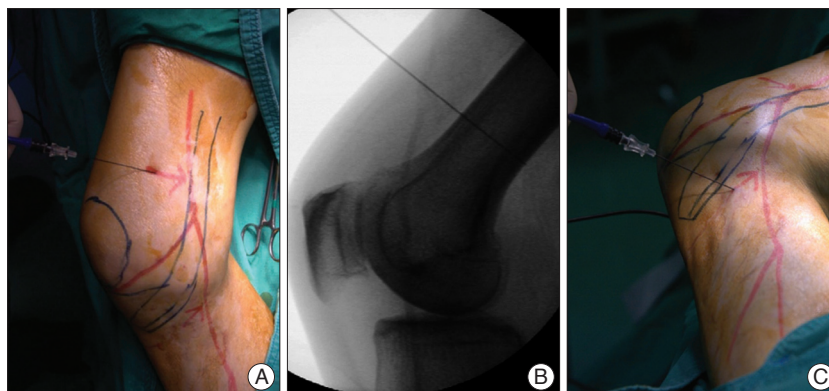
More than half of patients with SN are successfully managed with conservative treatment, including medication and nerve block<sup>12,20</sup>. When patients do not respond to conservative treatments, physicians consider surgical neurolysis or surgical neurectomy<sup>11,20</sup>. In the present case, saphenous nerve blocks provided temporary pain relief, but symptoms recurred within 3 days. Thus, we recommended PRF neuromodulation for SN.

### Anatomical considerations of the saphenous nerve

The saphenous nerve is the terminal sensory branch of the femoral nerve. It supplies sensation to the anteromedial aspect of the leg. The saphenous nerve originates from the femoral nerve in the inguinal region and travels with the femoral artery and vein down into the adductor canal. At the end of the canal, it emerges through the aponeurotic covering, travels along the medial side of the knee behind the sartorius muscle, and then pierces the fascia lata between the tendons of the sartorius and gracilis muscles. Around the medial knee, the infrapatellar nerve



**Fig. 1.** The entry points (red arrows) of the radiofrequency needle inserted to block the saphenous nerve (red free line) are illustrated on the right leg. The right side was positioned with a hip external rotation, a hip abduction, and a knee flexion.



**Fig. 2.** A : The radiofrequency needle and electrode were applied for the saphenous nerve (red free line) around adductor's canal. B : A lateral radiograph showing the entry point of the radiofrequency needle inserted to block the saphenous nerve above the epicondyle under the inguinal ligament. C : The radiofrequency needle and electrode were applied for the sartorial branch of the saphenous nerve (red free line) around superficial saphenous vein.

branches off the saphenous nerve to supply the prepatellar skin. The saphenous nerve continues down subcutaneously with the long saphenous vein along the medial tibial border. The nerve terminates distally into two branches that supply the ankle and medial foot<sup>6</sup>). The relative positioning of the saphenous nerve and the long saphenous vein during their course down the medial leg can vary from person to person<sup>6</sup>).

The entrapment site is most commonly at the adductor canal where the nerve changes course and travels through a fibrous band. This area can be palpated approximately 10 cm above the medial femoral condyle below the sartorius muscle<sup>19</sup>).

### Anatomical consideration for the target of the radiofrequency modulation

Nerve blocks by injections deliver their effects through diffusion to the surrounding tissue, which indicates that relatively inaccurate targeting can be tolerated. However, when modulating the nerve with PRF, the practitioner should be aware of the exact anatomy because lesion creation should be more restricted and exact.

While the medial branch, dorsal root ganglion, and suprascapular nerve have confident bony landmarks for local injection and PRF neuromodulation, the saphenous nerve landmarks are relatively uncertain. Thus, it is difficult to accurately target the saphenous nerve due to its anatomical variations<sup>9</sup>). For this reason many articles and clinical experiences were often described by using ultrasound for saphenous nerve block. In this case, the nerve was found and targeted around the adductor canal and below the medial epicondyle by using fluoroscopy (Fig. 1).

### Mechanism and effect of pulsed radiofrequency

Two types of radiofrequency lesioning are clinically used : conventional radiofrequency and PRF. PRF neuromodulation is nondestructive but can relieve pain by delivering an electrical field to the neural tissue<sup>14</sup>). While the effects of conventional radiofrequency thermal lesioning have a clear pathophysiological background in the destruction of nerve tissue and the subsequent blockade of pain transmission, the mechanism of PRF is still unknown. One theory to explain PRF suggests that a neuromodulatory effect occurs through changes in gene expression in pain processing neurons<sup>4,5,7</sup>). There are several advantages to using PRF for pain control. Firstly, PRF may provide long lasting pain relief with less side effects. Secondly, PRF can be repeated if the pain recurs since no tissue has been destroyed<sup>14</sup>). Thirdly, many published reports have revealed the efficacy of PRF for peripheral nerve lesions<sup>14</sup>). Thus, PRF is a promising treatment for patients with chronic pain refractory to conservative treatment.

### CONCLUSION

We present the first known application of PRF neuromodula-

tion for a case of SN. PRF neuromodulation of the saphenous nerve may offer an effective and low-risk treatment in patients with medically intractable SN or who are unwilling or unfit to undergo surgery. Further controlled prospective studies are necessary to evaluate the exact effects and long-term outcomes of this method.

### References

1. Adar R, Meyer E, Zweig A : Saphenous neuralgia : a complication of vascular reconstructions below the inguinal ligament. *Ann Surg* 190 : 609-613, 1979
2. Ahadi T, Raissi GR, Togha M, Nejati P : Saphenous neuropathy in a patient with low back pain. *J Brachial Plex Peripher Nerve Inj* 5 : 2, 2010
3. Bertram C, Porsch M, Hackenbroch MH, Terhaag D : Saphenous neuralgia after arthroscopically assisted anterior cruciate ligament reconstruction with a semitendinosus and gracilis tendon graft. *Arthroscopy* 16 : 763-766, 2000
4. Cahana A, Vutskits L, Muller D : Acute differential modulation of synaptic transmission and cell survival during exposure to pulsed and continuous radiofrequency energy. *J Pain* 4 : 197-202, 2003
5. Cosman ER Jr, Cosman ER Sr : Electric and thermal field effects in tissue around radiofrequency electrodes. *Pain Med* 6 : 405-424, 2005
6. Dunaway DJ, Steensen RN, Wiand W, Dopirak RM : The sartorial branch of the saphenous nerve : its anatomy at the joint line of the knee. *Arthroscopy* 21 : 547-551, 2005
7. Higuchi Y, Nashold BS Jr, Sluijter M, Cosman E, Pearlstein RD : Exposure of the dorsal root ganglion in rats to pulsed radiofrequency currents activates dorsal horn lamina I and II neurons. *Neurosurgery* 50 : 850-855; discussion 856, 2002
8. House JH, Ahmed K : Entrapment neuropathy of the infrapatellar branch of the saphenous nerve. *Am J Sports Med* 5 : 217-224, 1977
9. Kokubun K : [Anatomical and clinical study on the femoral nerve lesion]. *Nihon Seikeigeka Gakkai Zasshi* 57 : 65-77, 1983
10. Kopell HP, Thompson WA : Knee pain due to saphenous nerve entrapment. *N Engl J Med* 263 : 351-353, 1960
11. Lippitt AB : Neuropathy of the saphenous nerve as a cause of knee pain. *Bull Hosp Jt Dis* 52 : 31-33, 1993
12. Luerssen TG, Campbell RL, Defalque RJ, Worth RM : Spontaneous saphenous neuralgia. *Neurosurgery* 13 : 238-241, 1983
13. Mozes M, Ouaknine G, Nathan H : Saphenous nerve entrapment simulating vascular disorder. *Surgery* 77 : 299-303, 1975
14. Munglani R : The longer term effect of pulsed radiofrequency for neuropathic pain. *Pain* 80 : 437-439, 1999
15. Romanoff ME, Cory PC Jr, Kalenak A, Keyser GC, Marshall WK : Saphenous nerve entrapment at the adductor canal. *Am J Sports Med* 17 : 478-481, 1989
16. Saal JA, Dillingham MF, Gamburd RS, Fanton GS : The pseudoradicular syndrome. Lower extremity peripheral nerve entrapment masquerading as lumbar radiculopathy. *Spine (Phila Pa 1976)* 13 : 926-930, 1988
17. Senegor M : Iatrogenic saphenous neuralgia : successful therapy with neuroma resection. *Neurosurgery* 28 : 295-298, 1991
18. Tranier S, Durey A, Chevallier B, Liot F : Value of somatosensory evoked potentials in saphenous entrapment neuropathy. *J Neurol Neurosurg Psychiatry* 55 : 461-465, 1992
19. Worth RM, Kettelkamp DB, Defalque RJ, Duane KU : Saphenous nerve entrapment. A cause of medial knee pain. *Am J Sports Med* 12 : 80-81, 1984
20. Yang DS : [Diagnosis and treatment of saphenous nerve entrapment]. *Zhonghua Wai Ke Za Zhi* 26 : 464-465, 509-510, 1988