

## Clinical Article

# Protocols and Results of Resident Neurosurgeon's Transfemoral Catheter Angiography Training Supervised by Neuroendovascular Specialists

Dong-Seong Shin, M.D.,<sup>1</sup> Dong-Kyu Yeo, M.D.,<sup>1</sup> Sun-Chul Hwang, M.D.,<sup>1</sup> Sukh-Que Park, M.D.,<sup>2</sup> Bum-Tae Kim, M.D.<sup>1</sup>

*Department of Neurosurgery,<sup>1</sup> College of Medicine, Soonchunhyang University, Bucheon Hospital, Bucheon, Korea*

*Department of Neurosurgery,<sup>2</sup> College of Medicine, Soonchunhyang University, Seoul, Korea*

**Objective :** Transfemoral catheter angiography (TFCA) is a basic procedure in neurovascular surgery with increasing importance in surgical and non-invasive treatments. Unfortunately, resident neurosurgeons have relatively few opportunities to perform TFCA in most institutions. We report a method developed in our hospital for training resident neurosurgeons to perform TFCA and evaluate the efficacy of this training.

**Methods :** From May 2011 to September 2011, a total of 112 consecutive patients underwent TFCA by one resident neurosurgeon supervised by two neuroendovascular specialists. Patients who underwent elective diagnostic procedures were included in this study. Patients who underwent endovascular treatment were excluded. Demographic data, indications for TFCA, side of approach, number of selected arteries, and complications were analyzed.

**Results :** This study included 64 males and 48 females with a mean age of 51.6 (12-81) years. All procedures were performed in the angiography suite. Common indications for procedures were as follows : stroke-induced symptoms in 61 patients (54.5%), Moyamoya disease and arteriovenous malformation in 13 patients (11.6%), and unruptured intracranial aneurysm in eight patients (7.1%). Right and left femoral puncture was performed in 98.2% and 1.8% of patients, respectively. A total of 465 selective angiographies were performed without complications. Angiographic examination was performed on 4.15 vessels per patient.

**Conclusion :** TFCA can be performed safely by resident neurosurgeons based on anatomical study and a meticulous protocol under the careful supervision of neuroendovascular specialists.

**Key Words :** Cerebral angiography · Training · Residency.

## INTRODUCTION

Many conventional and traditional vascular operations are performed during neurosurgery. However, neuroendovascular treatment (NET) is emerging as a separate alternative treatment. NET began as a hybrid of traditional neurosurgical and neuroradiological approaches and is now widely used clinically for many therapeutic indications. Given the increasing importance of NET in neurovascular surgery, neurosurgeons are encouraged to become trained in NET. Transfemoral catheter angiography (TFCA) is a basic NET procedure, and it is also considered an important diagnostic modality for neurovascular diseases.

As the number of NET procedures performed by neurosur-

geons increases, resident neurosurgeons have many opportunities to participate in NET procedures. Unfortunately, it is difficult for neurosurgical residents to train in TFCA in most neurosurgery departments, and NET training guidelines for fellowships or residencies have not been established in Korea. TFCA training should be essential for neurosurgical residents because many neurosurgeons are required to perform TFCA. It is also commonly performed as a basic procedure of NET and is a diagnostic gold standard. Appropriate training and abundant experience are keys to performing safe TFCA procedures.

Resident neurosurgeons had the opportunity to train in TFCA at our hospital, and this paper presents the results of TFCA training using our standard protocol.

• Received : July 26, 2013 • Revised : May 22, 2013 • Accepted : August 5, 2013

• Address for reprints : Bum-Tae Kim, M.D.

Department of Neurosurgery, College of Medicine, Soonchunhyang University, Bucheon Hospital, 170 Jomaru-ro, Wonmi-gu, Bucheon 420-767, Korea

Tel : +82-32-621-5289, Fax : +82-32-621-5018, E-mail : bumtkim@schmc.ac.kr

• This is an Open Access article distributed under the terms of the Creative Commons Attribution Non-Commercial License (<http://creativecommons.org/licenses/by-nc/3.0>) which permits unrestricted non-commercial use, distribution, and reproduction in any medium, provided the original work is properly cited.

## MATERIALS AND METHODS

A senior resident neurosurgeon was trained in TFCA from May 1 to September 31, 2011, performing 112 consecutive TF-CAs under the supervision of two neuroendovascular specialists. All TFCA procedures were performed in the angiography suite. Patient demographic data, TFCA indications, side of approach, number of arteries selected, and complications were analyzed.

### TFCA protocol

The standard protocol was established based on our previously published cadaveric anatomy study of the inguinal area and aortic arch<sup>11,17</sup>. In the process of designing the training protocol, we designated patient safety as a top priority. Standardized TFCA protocols of our neurosurgical institute are as follows. 1) The operator should fully understand the neurovascular anatomy of the inguinal area and the configuration of the aortic arch and its major branches, which were previously published in our cadaveric studies. 2) The anterior wall of the femoral artery is

punctured at the level of the bottom of the femoral head with the Seldinger technique, and femoral arteriography is performed at an oblique angle of 25° at the site of femoral puncture. 3) 5 Fr catheters are used in adult patients, and 4 Fr catheters are used for patients under the age of 10 years. The catheter techniques are performed as gently as possible, as in microneurosurgery. 4) Selective catheterization of the carotids (internal, external), vertebral, or subclavian arteries is usually performed. 5) Road map images are taken at every step of the selective catheterizations, especially in the tortuous orifices and curvatures of the vertebral artery. 6) A 100-cm Davis diagnostic catheter (Cook Medical, Bloomington, IN, USA) is initially used. If this fails, a 100-cm Headhunter catheter (Cook Medical) and 100-cm Simon catheter (Cook Medical) are used in sequence depending on the complexity of the aortic arch and the configuration of its major branches. 7) Catheters are positioned as proximally as possible (that is, in the largest caliber of the selected artery) within the range of adequate diagnosis. 8) During vertebral angiography, if a catheter is unstable at the orifice due to the tortuosity, contrast dye is injected by hand. 9) If the operator fails to select the target vessel with a catheter, the supervisor becomes directly involved in the procedure or declares an end to the procedure. 10) Intracranial angiography is performed on the common carotid artery in the case of Moyamoya disease. 11) The operator should be fully aware of the constant dye concentration (100 mL of dye mixed with 40 mL of N/S), injection speed, and volume (5 mL/sec and 7-mL volume in the internal carotid; 4 mL/sec and 6-mL volume in the vertebral artery). 12) The femoral sheath is removed immediately after completion of angiography, and manual compression is applied for 20 minutes to achieve hemostasis. 13) The operator should complete the Cerebral Angiography Report Form after the procedure and then receive confirmation from the supervisor (Fig. 1).

**Fig. 1.** Cerebral angiography report form. The resident neurosurgeon must confirm the diagnostic angiography result after the procedure. This form contains the patient's basic information, diagnosis, operator information, amount of dye used, puncture site, complications, type of sheath, type of catheter, examination of vessel locations, location of three-dimensional rotation angiography, brief patient history, angiographic findings, final diagnosis after angiography, report date, and signatures.

## RESULTS

A total of 64 males and 48 females underwent TFCA by a senior resident neurosurgeon. The mean patient age was 51.6 (range 12-80) years. Twenty-seven patients were diagnosed with subarachnoid hemorrhage, and 28 had ischemia or a transient ischemic attack. Twenty-one patients were included in a follow-up study after coil embolization or clip operation for aneurysms. Eleven patients had unruptured intracranial aneurysms or vertebral artery dissection. Five patients each had a brain tumor, Moyamoya disease, and arteriovenous malformation. Four patients had intracerebral hemorrhage or intraventricular hemorrhage, two had cervical carotid artery stenosis, and four patients had other conditions (Table 1).

### Puncture site

All procedures involved the femoral access route. A total of 110 patients underwent puncture of the right femoral artery, and two underwent puncture of the left femoral artery.

## Catheters

The Davis catheter was initially chosen for all patients. However, it was replaced with a Headhunter or Simons catheter when the operator failed to select the target vessel with the Davis catheter. A total of 45 patients <49 years of age were treated with only a Davis catheter. TFCA was performed on 31 patients 50 to 59 years of age. A Davis catheter was used in 30 of these patients, and Davis, Headhunter, and Simons catheters were used in one patient. Twenty-eight patients >60 years of age were treated with only a Davis catheter. Two types of catheters were used in three patients, and three types were used in one patient (Fig. 2).

## Number of vessels selected in angiography

Selected vessels included the femoral artery, common carotid artery in the neck, intracranial carotid artery, external carotid artery, vertebral artery, subclavian artery, and aorta. Femoral artery angiography was performed in all patients to check for puncture site complications after the femoral sheath was inserted. Two-vessel angiography was performed in 13 patients and three-vessel angiography in 14 patients. Four vessels were selected in 46 patients, and five vessels in 23 patients. Six-vessel angiography was performed in 14 patients, and seven-vessel angiography was performed in two patients (Fig. 3). A total of 465 selective vessel angiography procedures were performed in 112 patients who underwent TFCA without complications. The mean number of angiography procedures was 4.14 vessels per patient.

## DISCUSSION

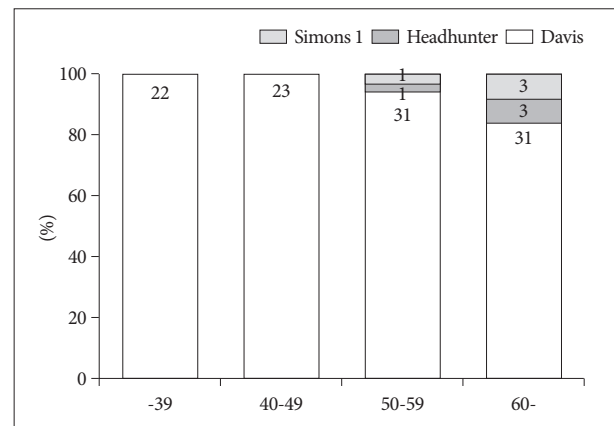
Despite the recent advances in noninvasive diagnostic neuroimaging, diagnostic cerebral angiography is still the cornerstone and gold standard for evaluations and treatment of cerebrovascular disease<sup>3</sup>. In addition to a high level of technical expertise, performance and interpretation of diagnostic cerebral angiography requires profound cognitive knowledge of related neurological pathophysiology and neurovascular anatomy and pathology as well as an understanding of the full range of neurodiagnostic possibilities. Expertise in diagnostic cerebral angiography is the foundation of safe and successful neuroendovascular interventions such as carotid artery angioplasty and stenting for atherosclerosis, interventional stroke therapy, intracranial angioplasty and stenting, and embolization of cerebral aneurysms, epistaxis, and vascular malformations<sup>4</sup>.

Formal neuroscience education, adequate procedural training, and sufficient experience are all essential to ensure desirable outcomes and to gain a high level of competence in diagnostic cerebral angiography and interventional procedures. The United States, Europe, and Japan have guidelines or educational programs for NET training<sup>4</sup>, whereas the Korean Neurosurgical Society and Society of Korean Endovascular Neurosurgeons do not.

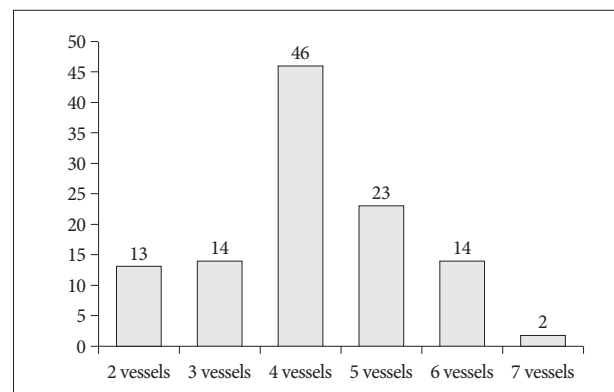
Endovascular procedures are prone to causing strokes, leav-

**Table 1.** Clinical diagnosis of transfemoral catheter angiography performed by a resident neurosurgeon

Clinical diagnosis	No. of patients (%)
Subarachnoid hemorrhage	27 (24.1)
Ischemia/transient ischemic attack	28 (25.0)
Follow-up angiography after neuroendovascular treatment	21 (18.7)
Unruptured intracranial aneurysm/vertebral artery dissection	11 (9.8)
Brain tumor	5 (4.5)
Moyamoya disease	5 (4.5)
Arteriovenous malformation	5 (4.5)
Intracerebral hemorrhage/intraventricular hemorrhage	4 (3.6)
Cervical carotid artery stenosis	2 (1.7)
Others	4 (3.6)
Total	112 (100)



**Fig. 2.** Number of catheters used according to patient age. The number of catheters used increased with age. The age range was 50 to 59 years. In 30 patients, a Davis catheter was used. In one patient, Davis, Headhunter, and Simons catheters were used. Among patients >60 years of age, a Davis catheter was used in 28 patients; Davis and Headhunter catheters were used in three patients; and Davis, Headhunter, and Simons catheters were used in one patient.



**Fig. 3.** Number of vessels used in angiography. Selected vessels included the femoral artery, common carotid artery in the neck, intracranial carotid artery, external carotid artery, vertebral artery, subclavian artery, and aorta. Femoral artery angiography was performed in all patients.

ing patients with problematic sequelae. Owing to the risk for procedure-induced stroke, many physicians do not recommend this procedure, and some patients become reluctant to undergo this procedure<sup>3,18</sup>. The risk for permanent neurological deficits caused by diagnostic cerebral angiography is considerable and ranges from 0.3 to 5.7%<sup>7,10,12,13,15</sup>. Experienced neurovascular specialists can have complication rates lower than 1%<sup>9</sup>. There is an additional risk for temporary neurological deficits ranging from 0.3% to 6.8%, which means that the risk is increased two to three fold on average compared with the risk for permanent neurological deficits<sup>7,10,12,13,15</sup>. Patients with atherosclerotic cerebrovascular disease manifested by neurological symptoms (transient ischemic attack or stroke) have a risk for stroke from diagnostic cerebral angiography that is two- to three-fold that of patients with asymptomatic lesions<sup>9</sup>. These findings explain the emphasis on a strictly systematic education for NET, and the importance of formal education programs for patient safety cannot be overemphasized.

A senior resident neurosurgeon participated in NET as an assistant and performed DSA under supervision in our institute. NET education of a senior resident neurosurgeon has some advantages in neurosurgical education. 1) It helps improve the understanding of neurovascular disease. 2) It helps to acquire a technical base for NET. 3) It helps to gain knowledge about neuroradiology and radiophysiology. 4) Senior resident neurosurgeons are capable of managing patients with neurovascular disease and can improve their abilities related to treatment decisions, planning, and preprocedural care by participating in diagnostic procedures.

Most countries recommend that NET programs should only be available to board-certified neurosurgeons or radiologists<sup>1,8,9,16</sup> because NET is a subspecialty of neurosurgery or radiology, and trainees need enough experience to handle neurosurgical disease before NET training. According to an analysis of 5000 angiogram cases, fellowship-trained specialists have fewer neurological complications (0.5%) than do even experienced angiographers (0.6%), and both have far fewer complications than trainees under supervision (2.8%)<sup>12-14</sup>. However, there is no doubt that every trainee has a starting point and that no one can be an expert from the beginning. Moreover, senior neurosurgical residents have enough experience in neurosurgical disease management to perform NET. Therefore, they benefit from an opportunity to learn the basic procedures of NET and improve their knowledge of neurosurgical disease.

The most important factor in resident training is access to adequate cases that encompass a range of cerebrovascular diseases. Many guidelines of NET training have recommended 100 or more diagnostic angiograms before starting training in endovascular procedures, such as embolization of aneurysms, arteriovenous malformations and tumors, angioplasty and stenting for the treatment of intracranial and extracranial occlusive cerebrovascular disease, and the performance of invasive functional testing<sup>2,6,8</sup>. However, resident training courses have not focused

on treatment skills in endovascular procedures. Assistance roles and performance of TFCA procedures are enough to learn endovascular treatments that are part of neurovascular treatment modalities. Moreover, the recommended number of 100 or more diagnostic angiograms is always arbitrary. In any surgical procedure, some residents or fellows are ready to perform procedures quickly, while others need many more repetitions before gaining competence<sup>6</sup>.

With improvements in noninvasive imaging modalities of the cerebral vasculature, the indications for diagnostic angiography will decrease, making it increasingly difficult to achieve the designated number of 100 diagnostic angiograms and to enter the field of NET. It is necessary to start NET training early during a residency. In our experience, senior residents have already fulfilled the number of recommended digital subtraction angiographies during their residency. Therefore, with enough experience and cases, they will be able to focus more on treatment procedures during their fellowship.

Because patient safety is the top priority in TFCA training, it was considered to be most important in our institute's training guidelines. Resident neurosurgeons should understand the anatomy of the inguinal area and aortic arch before TFCA procedure training. The TFCA training protocol was established on the following principle: "Do not do more than trainees can handle during TFCA". In particular, when it comes to selective dye injection, the protocol is designed to be performed in the proximal part of vessels, which is a good option for patients who have unstable cerebral vascular hemodynamics such as that caused by cervical internal carotid artery stenosis and Moyamoya disease. Patients with these diseases showed instability of cerebral vascular hemodynamics, and selective dye injection was performed on the common carotid artery. This action helped to avoid manipulation of the internal carotid artery and decrease hemodynamic stress, although the amount of dye increased more in common carotid artery angiography than in internal carotid artery angiography.

An endovascular specialist was involved the TFCA performed during the senior resident training when; 1) vessel selection was difficult for the resident neurosurgeon, 2) multiple catheters were used because of vessel tortuosity, 3) better TFCA skills were needed to avoid complications in elderly patients or those with unstable disease, 4) the resident neurosurgeon was confused by the anatomical variation of the vessels, or 5) the femoral artery puncture failed despite multiple attempts. The supervisor pointed out the errors of the resident neurosurgeon during training. The main errors were as follows: the trainee 1) advanced the diagnostic catheter and guidewire with too much force and too quickly, 2) did not check for an air bubble in the injection syringe, 3) advanced the diagnostic catheter and guidewire outside the image, and 4) did not confirm blood regurgitation before connecting the dye injector.

Although the senior resident did not experience complications in this series, complication care is as important as avoid-

ing complications. It is important that the trainee does not panic and does ask a supervisor for help. In this way, the trainee will learn to manage complications while resolving complications with a supervisor.

This study has some limitations. First, it was retrospective and did not compare groups. Second, it was a single-center experience, and the results cannot be generalized to all TFCA training. Prospective multicenter trials are needed. Nevertheless, the study shows that a resident neurosurgeon was capable of safely performing 112 consecutive TFCA procedures under the supervision of experienced endovascular specialists.

## CONCLUSION

Although this was a retrospective, single-center study, it demonstrated that TFCA can be performed by a senior resident neurosurgeon without major complications when supervised by experienced neuroendovascular specialists using our protocol.

## References

- American Society of Interventional and Therapeutic Neuroradiology : General considerations for endovascular surgical neuroradiologic procedures. *AJNR Am J Neuroradiol* 22 (8 Suppl) : S1-S3, 2001
- Barr JD, Connors JJ 3rd, Sacks D, Wojak JC, Becker GJ, Cardella JF, et al. : Quality improvement guidelines for the performance of cervical carotid angioplasty and stent placement. *AJNR Am J Neuroradiol* 24 : 2020-2034, 2003
- Cerebral arteriography. A report for health professionals by the Executive Committee of the Stroke Council, American Heart Association. *Circulation* 79 : 474, 1989
- Connors JJ 3rd, Sacks D, Furlan AJ, Selman WR, Russell EJ, Stieg PE, et al. : Training, competency, and credentialing standards for diagnostic cervicocerebral angiography, carotid stenting, and cerebrovascular intervention. *AJNR Am J Neuroradiol* 25 : 1732-1741, 2004
- Crawley F, Stygall J, Lunn S, Harrison M, Brown MM, Newman S : Comparison of microembolism detected by transcranial Doppler and neuropsychological sequelae of carotid surgery and percutaneous transluminal angioplasty. *Stroke* 31 : 1329-1334, 2000
- Harbaugh RE, Agarwal A : Training residents in endovascular neurosurgery. *Neurosurgery* 59 (5 Suppl 3) : S277-S281; discussion S3-S13, 2006
- Heiserman JE, Dean BL, Hodak JA, Flom RA, Bird CR, Drayer BP, et al. : Neurologic complications of cerebral angiography. *AJNR Am J Neuroradiol* 15 : 1401-1407; discussion 1408-1411, 1994
- Higashida RT, Hopkins LN, Berenstein A, Halbach VV, Kerber C : Program requirements for residency/fellowship education in neuroendovascular surgery/interventional neuroradiology : a special report on graduate medical education. *AJNR Am J Neuroradiol* 21 : 1153-1159, 2000
- Howington JU, Hopkins LN, Piepgras DG, Harbaugh RE : Training standards in endovascular neurosurgery. *Neurosurg Clin N Am* 16 : 445-449, xi, 2005
- Johnston DC, Chapman KM, Goldstein LB : Low rate of complications of cerebral angiography in routine clinical practice. *Neurology* 57 : 2012-2014, 2001
- Kim BT, Shin DS : Anatomical aspect of the transfemoral neuroendovascular approach. *Neurointervention* 5 : 79-84, 2010
- Mani RL, Eisenberg RL : Complications of catheter cerebral arteriography : analysis of 5,000 procedures. II. Relation of complication rates to clinical and arteriographic diagnoses. *AJR Am J Roentgenol* 131 : 867-869, 1978
- Mani RL, Eisenberg RL : Complications of catheter cerebral arteriography : analysis of 5,000 procedures. III. Assessment of arteries injected, contrast medium used, duration of procedure, and age of patient. *AJR Am J Roentgenol* 131 : 871-874, 1978
- Mani RL, Eisenberg RL, McDonald EJ Jr, Pollock JA, Mani JR : Complications of catheter cerebral arteriography : analysis of 5,000 procedures. I. Criteria and incidence. *AJR Am J Roentgenol* 131 : 861-865, 1978
- Moran CJ, Milburn JM, Cross DT 3rd, Derdeyn CP, Dobbie TK, Littenberg B : Randomized controlled trial of sheaths in diagnostic neuroangiography. *Radiology* 218 : 183-187, 2001
- Picard L, Negro M, Ter Brugge K, Mawad M, Lasjaunias P, Viñuela F, et al. : 1998 world Federation of interventional and therapeutic neuroradiology. Guidelines for fellowship training programmes in interventional neuroradiology. *Interv Neuroradiol* 4 : 195-197, 1998
- Shin IY, Chung YG, Shin WH, Im SB, Hwang SC, Kim BT : A morphometric study on cadaveric aortic arch and its major branches in 25 Korean adults : the perspective of endovascular surgery. *J Korean Neurosurg Soc* 44 : 78-83, 2008
- Wein TH, Hickenbottom SL, Alexandrov AV : Thrombolysis, stroke units and other strategies for reducing acute stroke costs. *Pharmacoeconomics* 14 : 603-611, 1998