

Case Report

Ruptured Saccular Aneurysm Arising from Fenestrated Proximal Anterior Cerebral Artery : Case Report and Literature Review

Woo-Keun Kwon, M.D., Kyung-Jae Park, M.D., Ph.D., Dong-Hyuk Park, M.D., Ph.D., Shin-Hyuk Kang, M.D., Ph.D.

Department of Neurosurgery, Korea University College of Medicine, Seoul, Korea

The aneurysm arising from fenestrated proximal anterior cerebral artery (ACA) is considered to be unique. The authors report a case of a 59-year-old woman who presented with a subarachnoid hemorrhage (SAH) secondary to a ruptured aneurysm originating from the fenestrated A1 segment of right ACA. The patient had another unruptured aneurysm which was located at the right middle cerebral artery bifurcation. She was successfully treated with surgical clipping for both aneurysms. From the previously existing literatures, we found 18 more cases (1983-2011) of aneurysms associated with fenestrated A1 segment. All cases represented saccular type of aneurysms, and 79% of the patients had SAH. There were three subtypes of the fenestrated A1 aneurysms depending on the anatomical location, relative to the fenestrated segment. The most common type was the aneurysms located on the proximal end of fenestrated artery (82%). Azygos ACA and hypoplastic A1 were frequently accompanied by the aneurysm (33% and 31%, respectively), and multiple aneurysms were shown in three cases (16%). Considering that fenestrated A1 segment is likely to develop an aneurysm, which has high risk of rupture, early management may benefit patients with aneurysms accompanied by fenestrated proximal ACA.

Key Words : Anterior cerebral artery · Cerebral aneurysm · Fenestration.

INTRODUCTION

Partial duplication of intracranial arteries, so called fenestration, is known to have an angiographical incidence of 0.3 to 0.9%, and is frequently associated with aneurysms²². Fenestrated arteries are often observed in the posterior circulation, but are known to be relatively unusual in the anterior circulation¹⁹. Aneurysms arising from the fenestrated A1 segment of anterior cerebral artery (ACA) are even more rare, and are considered to be unique because they may be associated with other vascular anomalies. However, the characteristics of fenestrated A1 aneurysms has not been well determined until now.

In the present report, we demonstrate a case of ruptured saccular aneurysm arising from the proximal end of a fenestrated A1 artery. By literature review, we classified fenestrated A1 aneurysm into three subtypes based on the anatomical location of the aneurysm and found the close relationship between the occurrence of fenestrated A1 aneurysm and the presence of several

vascular anomalies including azygos ACA and hypoplastic A1.

CASE REPORT

Case presentation

A 59-year-old woman was admitted with complaints of a sudden onset of dysarthria and left side weakness. Computed tomography revealed an intracerebral hemorrhage in the right basal ganglia and frontal lobe. Subarachnoid hemorrhage was also identified in the anterior falx and sulci of medial frontal lobes (Fig. 1A). Cerebral angiography demonstrated a saccular aneurysm which arised from the proximal end of the right fenestrated A1 segment. The A2 segment of ACA was only visible from the right internal carotid artery. There was another saccular aneurysm at the right middle cerebral artery (MCA) bifurcation which was considered as an unruptured one because of the long distance from co-existing intracerebral hematoma (Fig. 1B, C, D).

• Received : September 18, 2012 • Revised : February 3, 2013 • Accepted : May 13, 2013

• Address for reprints : Shin-Hyuk Kang, M.D., Ph.D.

Department of Neurosurgery, Korea University College of Medicine, 73 Incheon-ro, Sungbuk-gu, Seoul 136-705, Korea.

Tel : +82-2-920-5391, Fax : +82-2-929-0629, E-mail : hermes23@kumc.or.kr

• This is an Open Access article distributed under the terms of the Creative Commons Attribution Non-Commercial License (<http://creativecommons.org/licenses/by-nc/3.0>) which permits unrestricted non-commercial use, distribution, and reproduction in any medium, provided the original work is properly cited.

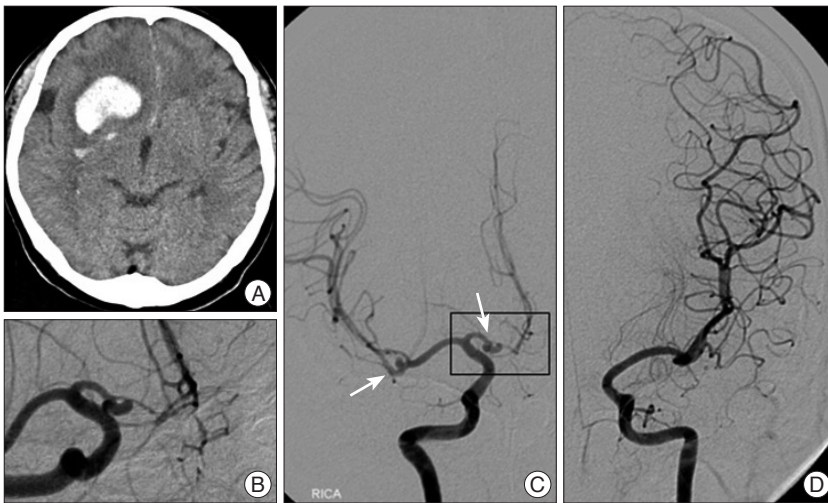


Fig. 1. A : Computed tomography scan showing a large intracerebral hemorrhage in right side frontal lobe extending to basal ganglia. Subarachnoid hemorrhage was also identified at the anterior falx and sulci of medial frontal lobes. B : Angiography revealing an aneurysm arising from the proximal end of fenestrated right A1 segment. C : Right cerebral angiogram showing two aneurysms including one on the proximal end of fenestrated A1 and another on the middle cerebral artery bifurcation. Azygos anterior cerebral artery was visible on the angiogram. D : Left carotid angiogram showing that the right A1 segment is aplastic.

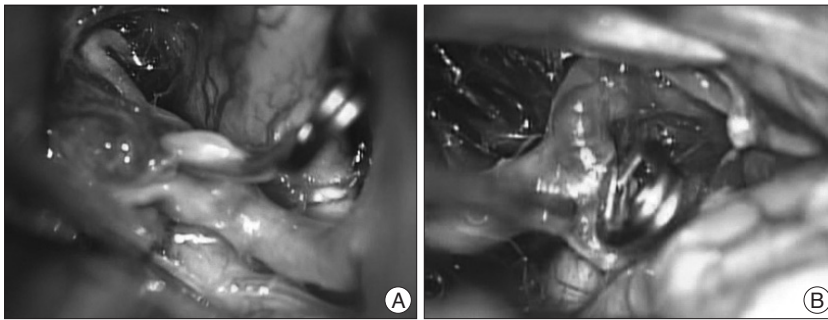


Fig. 2. Intraoperative photographs exposed by left pterional craniotomy. A : The fenestration of right A1 and a clipped saccular aneurysm on the proximal end of the fenestration. B : Photograph of the unruptured middle cerebral artery bifurcation aneurysm after successful clipping.

Under general anesthesia, the aneurysms were surgically clipped via right pterional craniotomy. A ruptured saccular aneurysm with broad neck was identified on the proximal end of fenestrated A1 segment intraoperatively. An aneurysm was projected anteriorly and was occluded by Yasargil mini clip. An unruptured MCA bifurcation aneurysm was also treated by surgical clipping and the intracerebral hematoma was removed (Fig. 2).

The postoperative course was uneventful, and the patient was discharged without any neurologic deficits.

Literature review of fenestrated A1 artery aneurysms

In the literature review, we found 18 cases of aneurysms arising from the fenestrated A1 segment. Characteristics of 19 cases (including present case)^{1-4,6,7,9-13,16-20,22} are summarized in Table 1. There were 9 males and 9 females (1 case, not recorded) with a mean age of 49.7 years (range 33-78 years). The sizes of aneurysms were recorded in 7 out of 19 cases, and the mean aneurysm

size was 5.05 mm (range 2.9-7.0 mm). Twelve aneurysms were developed at the right side while seven were located at left side. All 19 aneurysms were saccular type and 15 cases (79%) were ruptured. Three among the aneurysms were treated by endovascular interventions, while the other aneurysms except for those three were treated by aneurysm clipping.

We could classify the aneurysms into three types based on the arising point of the aneurysm (Fig. 3). Of the 17 cases in which exact location of the aneurysm was described on the original article (including the present case), 14 (82%) aneurysms developed on the proximal end of the fenestrated A1 segment, which was classified as type I. Two cases (12%) were classified as type II which represent the aneurysm located on the midportion of the fenestrated A1. One case (6%) which demonstrated multiple aneurysms including one at the proximal end and another at the posterior aspect of the fenestrated artery was classified as type III. Of the nine reports in which the presence of azygos ACA has been investigated azygos ACA was noted in 3 cases (33%). Hypoplastic A1 or aplasia of A1 was demonstrated in 4 cases (31%) out of 13 cases in which the status of A1 hypoplasia or aplasia were described. In one case, the ipsilateral A1 was hypoplastic while the other three cases represented contralateral hypoplastic A1. Finally, multiple aneurysms were found in 3 cases (16%) including the present case.

DISCUSSION

There were only few articles which have proposed several theories for the development of fenestrated A1 segment. Fenestration of the A1 segment might occur due to the absence of fusion of the plexiform anastomosis which was present in the distal primitive ACA during the 18- to 43-mm stage of the embryo^{1,15}. This failure would possibly increase blood flow in one of the A1 segments because of the contralateral A1 hypoplasia, resulting in increased hemodynamic stress on the ipsilateral A1 segment. Such increased blood flow and hemodynamic stress would prevent normal fusion of the plexiform anastomosis in the distal primitive ACA, resulting in formation of the A1 fenestration, and could also cause aneurysm formation on the fenestrated A1 segment⁴. However, the pathophysiologic mechanism for the devel-

Table 1. Summary of 19 cases of aneurysms associated with A1 fenestration (1983-2011)

Author	Age	Gender	Laterality	Aneurysm size	Rupture/Unrupture	Location	Azygos ACA	A1 aplasia/hypoplasia	Multiplicity	Treatment modality	Outcome
Yamada et al. ²²⁾	43	M	Rt	NR	Ruptured	Proximal end	(-)	(-)	(-)	Clipping	Death
Inagawa et al. ⁶⁾	70	F	Lt	NR	Unruptured	NR	(-)	(-)	(+); (MCA-ruptured)	Conserve	DA
Korosue et al. ⁹⁾	41	M	Rt	NR	Ruptured	Proximal end	(-)	(-)	(-)	Clipping	Death
Handa et al. ³⁾	50	F	Rt	NR	Ruptured	Proximal end	NR	(-)	(-)	Clipping	GR
Wakabayashi et al. ¹⁹⁾	38	M	Rt	6.5	Ruptured	Proximal end	NR	(-)	(-)	Clipping	DA
Wakabayashi et al. ¹⁹⁾	41	M	Rt	5.0	Ruptured	Proximal end	NR	(-)	(-)	Clipping	Death
Minakawa et al. ¹¹⁾	56	M	Rt	NR	Ruptured	Proximal end	NR	NR	(-)	Clipping	NR
Ogasawara et al. ¹³⁾	65	F	Lt	NR	Ruptured	Proximal end	NR	NR	(-)	Clipping	VS
San-Galli et al. ¹⁷⁾	47	M	Lt	NR	Unruptured	Proximal end	NR	NR	(-)	Clipping	GR
Friedlander and Ogliv ¹⁾	33	M	Rt	NR	Ruptured	Proximal end	(+)	(-)	(-)	Clipping	GR
Kachhara et al. ⁷⁾	50	F	Rt	NR	Ruptured	Proximal end	(-)	Contralateral A1	(-)	Clipping	GR
Taylor et al. ¹⁸⁾	68	M	Lt	5.0	Ruptured	Trunk	NR	Ipsilateral A1	(-)	Clipping	GR
Park et al. ¹⁶⁾	35	F	Lt	7.0	Ruptured	Proximal end	NR	NR	(+)	Clipping	GR
Wanibuchi et al. ²⁰⁾	52	F	Lt	4.3	Unruptured	Proximal end	(-)	(-)	(-)	Clipping	GR
Ihara et al. ⁴⁾	78	F	Rt	NR	Ruptured	Trunk	(+)	Contralateral A1	(-)	Clipping	GR
Mitsuhashi et al. ¹²⁾	71	F	Rt	4.5/5.2	Ruptured	Proximal end/Trunk	(-)	(-)	(-); 2 on fenestration	Coiling	GR
Mantatzis et al. ¹⁰⁾	52	M	Rt	NR	Ruptured	NR	NR	NR	(-)	Coiling	GR
Mantatzis et al. ¹⁰⁾	39	NR	Lt	NR	Unruptured	Proximal end	NR	NR	(-)	Coiling	GR
Present case	60	F	Rt	2.9	Ruptured	Proximal end	(+)	Contralateral A1	(+)	Clipping	GR

Location : aneurysm origin relative to fenestrated segment. F : female, M : male, Rt : right, Lt : left, GR : good recovery, DA : disabled, VS : vegetative state, (+) : positive, (-) : negative, NR : not recorded

opment of fenestrated A1 segment is still not clearly understood.

Based on literature review, we classified fenestrated A1 aneurysm into three subtypes based on the location of aneurysms associated with A1 fenestrations, and to our knowledge, this is the first article to make a classification based on the location. In majority of the cases, the aneurysm had developed on the proximal end of the fenestration (82%), while 12% was developed on the trunk of duplicated A1. In our case, the aneurysm was located at the proximal end of the fenestrated A1, and could be determined as type I. Additionally most of fenestrated A1 aneurysms (79%) were ruptured at the time of presentation. Considering that cerebral saccular aneurysms usually arise from the arterial bifurcations where blood flow creates the greatest hemodynamic stress, the development of fenestrated A1 aneurysm also may be strongly associated with the hemodynamic force at the bifurcating point.

The overall incidence of azygos ACA is ranged from 0.22% to

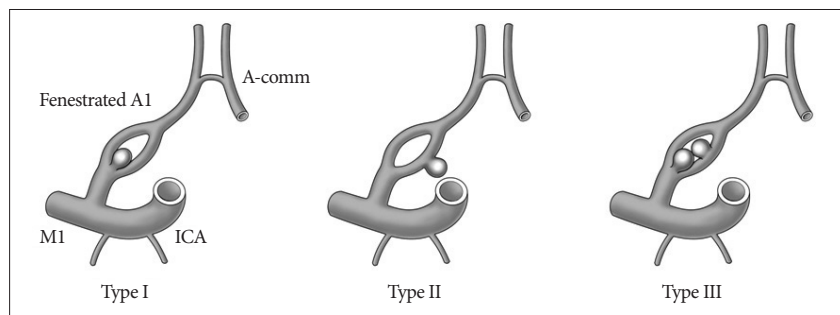


Fig. 3. Classification of fenestrated proximal anterior cerebral artery aneurysms based on the location of the aneurysm. 14 aneurysms (82%) were located on the proximal end of the A1 fenestration, which was classified as type I. 2 cases (12%) were arising from the trunk of the fenestrated A1, which was determined as type II. A single case which was demonstrated multiple aneurysms including one at the proximal end and another at the posterior aspect of the fenestrated A1, was classified as type III. Two cases were excluded from the analysis because the exact location of the aneurysm was not described clearly in the original article. A-comm : anterior communicating artery, ICA : internal cerebral artery, M1 : M1 segment of middle cerebral artery.

1.1%²⁾. There are two theories for azygos ACA formation. Abnormal fusion of paired A2 from the medial branch of the primitive olfactory artery at the 16-mm stage of the embryo, and persistence of the median artery of the corpus callosum at the 20- to 24-mm stage may involve in the regression or lack of development of the ACAs^{4,8,15)}. The azygos ACA is known to be

closely associated with the occurrence of saccular aneurysms^{1,2}. Considering these theories and reviewing several previous studies, we found that the incidence of azygos ACA in patients with fenestrated A1 aneurysm is much higher than the overall incidence of azygos ACA in normal population, which suggests that azygos ACA may be associated with the development of fenestrated A1 aneurysm.

The hypoplasia of the proximal ACA on one side is shown in 7-10% of general population, and is regarded as a normal variant³. However, by literature review, we found that the incidence of A1 hypoplasia or aplasia in patients with fenestrated A1 aneurysm (31%) was significantly higher than that reported in patients without aneurysms. The presence of hypoplastic A1 may lead to the increase of blood flow at the opposite side A1, in which additional hemodynamic stress may be provided. These could be one of the important predisposing factors for development of a fenestrated A1 aneurysm on the contralateral side of hypoplastic A1.

In our case, left A1 aplasia was demonstrated in cerebral angiography. In addition, there was an azygos ACA supplying blood flow to both cerebral hemispheres. Therefore, the right A1 segment was likely to receive strong hemodynamic stress, which may have affected the development of fenestrated A1 segment aneurysm and subsequent rupture.

In the literature review, multiple aneurysms were shown in 16% of patients with fenestrated A1 aneurysms, which was comparable to approximately 15-20% of incidence of multiplicity in all patients with aneurysms^{5,14,21}. Therefore, fenestrated A1 aneurysm may not be associated with the occurrence of multiple aneurysms.

CONCLUSION

Although fenestration of the proximal anterior cerebral artery is a very rare vascular anomaly, it is likely to accompany saccular type aneurysms in the vicinity of the vascular anomaly. The fenestrated A1 aneurysm is also often co-existed with the azygos ACA or contralateral hypoplastic A1. As the aneurysms originated from fenestrated proximal ACA are prone to rupture, early treatment may benefit patients harboring those aneurysms.

References

- Friedlander RM, Oglivy CS : Aneurysmal subarachnoid hemorrhage in a patient with bilateral A1 fenestrations associated with an azygos anterior cerebral artery. Case report and literature review. *J Neurosurg* 84 : 681-684, 1996
- Fujimoto Y, Yamanaka K, Nakajima Y, Yoshimura K, Yoshimine T : Ruptured aneurysm arising from the proximal end of an azygos anterior cerebral artery--case report. *Neurol Med Chir (Tokyo)* 44 : 242-244, 2004
- Handa J, Nakasu Y, Matsuda M, Kyoshima K : Aneurysms of the proximal anterior cerebral artery. *Surg Neurol* 22 : 486-490, 1984
- Ihara S, Uemura K, Tsukada A, Yanaka K, Nose T : Aneurysm and fenestration of the azygos anterior cerebral artery--case report. *Neurol Med Chir (Tokyo)* 43 : 246-249, 2003
- Inagawa T : Incidence and risk factors for multiple intracranial saccular aneurysms in patients with subarachnoid hemorrhage in Izumo City, Japan. *Acta Neurochir (Wien)* 151 : 1623-1630, 2009
- Inagawa T, Takeda T, Taguchi H, Yamada T : A case of fenestrated anterior cerebral artery with an associated aneurysm. *Hiroshima J Med Sci* 32 : 153-155, 1983
- Kachhara R, Nair S, Gupta AK : Fenestration of the proximal anterior cerebral artery (A1) with aneurysm manifesting as subarachnoid hemorrhage--case report. *Neurol Med Chir (Tokyo)* 38 : 409-412, 1998
- Kobayashi S, Yuge T, Sugita Y, Kuratomi A, Katayama M, Iryo O, et al. : Azygos anterior cerebral artery aneurysm associated with fenestration of the anterior cerebral artery. *Kurume Med J* 33 : 149-153, 1986
- Korosue K, Kuwamura K, Okuda Y, Tamaki N, Matsumoto S : Saccular aneurysm arising from a fenestrated anterior cerebral artery. *Surg Neurol* 19 : 273-275, 1983
- Mantatzis M, Kizilkilic O, Albayram S, Kocer N, Islak C : Endovascular treatment of aneurysms associated with fenestrated A1 segment of anterior cerebral artery : report of two cases. *J Neuroimaging* 21 : 165-169, 2011
- Minakawa T, Kawamata M, Hayano M, Kawakami K : Aneurysms associated with fenestrated anterior cerebral arteries. Report of four cases and review of the literature. *Surg Neurol* 24 : 284-288, 1985
- Mitsuhashi T, Sakamoto S, Kiura Y, Kurisu K : Endovascular coil embolization for ruptured kissing aneurysms associated with A1 fenestration. *Surg Neurol Int* 2 : 85, 2011
- Ogasawara H, Inagawa T, Yamamoto M, Kamiya K : Aneurysm in a fenestrated anterior cerebral artery--case report. *Neurol Med Chir (Tokyo)* 28 : 575-578, 1988
- Ostergaard JR, Hög E : Incidence of multiple intracranial aneurysms. Influence of arterial hypertension and gender. *J Neurosurg* 63 : 49-55, 1985
- Padgett DH : The development of the cranial arteries in the human embryo. *Contrib Embryol* 32 : 205-262, 1948
- Park SB, Park JT, Kang SD : Ruptured aneurysm arising from a fenestrated A1 segment of the anterior cerebral artery. *Korean J Cerebrovasc Dis* 2 : 84-86, 2000
- San-Galli F, Leman C, Kien P, Khazaal J, Phillips SD, Guerin J : Cerebral arterial fenestrations associated with intracranial saccular aneurysms. *Neurosurgery* 30 : 279-283, 1992
- Taylor R, Connolly ES Jr, Duong H : Radiographic evidence and surgical confirmation of a saccular aneurysm on a hypoplastic duplicated A1 segment of the anterior cerebral artery : case report. *Neurosurgery* 46 : 482-484, 2000
- Wakabayashi T, Tamaki N, Yamashita H, Saya H, Suyama T, Matsumoto S : Angiographic classification of aneurysms of the horizontal segment of the anterior cerebral artery. *Surg Neurol* 24 : 31-34, 1985
- Wanibuchi M, Kurokawa Y, Ishiguro M, Fujishige M, Inaba K : Characteristics of aneurysms arising from the horizontal portion of the anterior cerebral artery. *Surg Neurol* 55 : 148-154; discussion 154-155, 2001
- Wiebers DO, Whisnant JP, O'Fallon WM : The natural history of unruptured intracranial aneurysms. *N Engl J Med* 304 : 696-698, 1981
- Yamada T, Inagawa T, Takeda T : Ruptured aneurysm at the anterior cerebral artery fenestration. Case report. *J Neurosurg* 57 : 826-828, 1982