

Case Report

Temporary Semi-Jailing Technique for Coil Embolization of Wide-Neck Aneurysm with Small Caliber Parent Artery Following Incomplete Clipping

Jun Soo Byun, M.D.,¹ Jae Kyun Kim, M.D.,¹ Hwa Yeon Lee, M.D.,¹ Sung Nam Hwang, M.D.²

Department of Radiology,¹ Neurosurgery,² Chung-Ang University College of Medicine, Seoul, Korea

The authors describe the use of a self-expandable stent in a temporary deployment for treatment of a very wide-neck A1 segment of anterior cerebral artery (ACA) aneurysm following incomplete clipping. A 39-year-old hypertensive man presenting with seizure-like movement underwent computed tomography, which showed acute subarachnoid hemorrhage and an A1 segment of ACA aneurysm with superior and inferior projection. He underwent surgical clipping of the aneurysm, but superior and posterior portion of wide-neck aneurysm remained. We decided to treat the remnant aneurysm using an endovascular modality. After selection of the aneurysm, coil packing was performed assisted by the temporary semi-jailing technique. The Enterprise stent (Cordis Neurovascular, Miami, FL, USA) was deployed and recaptured repeatedly for angiography to ensure safety of the small caliber parent artery. Successful semi-deployment and recapture of the stent allowed subtotal coil occlusion of the aneurysm with good anatomic and clinical results. No complications were encountered. The stent could be recaptured up to the point where the proximal end of the stent marker was aligned with distal marker band of the microcatheter, approximately 70% of the stent length. The temporary semi-jailing technique is feasible for wide-neck aneurysm with small caliber parent artery.

Key Words : Intracranial aneurysm · Endovascular therapy · Stent · Surgical clipping.

INTRODUCTION

The goal of treatment of cerebral aneurysm is completely obliteration of their lumen, excluding the entire aneurysm from the arterial circulation. Usually microsurgical clipping attains this goal, but aneurysm remnants can occur in 5.2% of patients who undergo postoperative angiography¹⁶. These remnants are associated with potential for subarachnoid hemorrhage from rupture and regrowth over time^{6,7}. In second operation, surgeons often experience technical difficulty because of scars or dense adhesions surrounding the aneurysm, and configuration and location of aneurysm⁵.

There have been technical improvements in endovascular coiling, and technology has allowed some of these remnants to be treated safely^{1,15}. However, endovascular coil embolization also has limitations in the treatment of wide-neck aneurysm due to possible coil migration into the parent artery and long-term recurrence^{4,18}. Technical advances make it possible to treat

wide-neck aneurysm using variety of endovascular strategies such as double catheter technique¹⁰, balloon-assisted coiling¹³, and stent assisted coiling^{2,14}. Recently, the stent-jack³ and semi-jailing^{9,19} techniques have been introduced for patients with broad-necked aneurysm. We report a case of remnant wide-neck aneurysm with small caliber parent artery (about 1 mm) following clipping, treated by a temporary semi-jailing technique¹² using the Enterprise stent system (Cordis Neurovascular, Miami, FL, USA).

CASE REPORT

A 41 years old man with seizure like movement was admitted to our hospital. He had a history of hypertension treatment for 3 years. On neurologic examination, the patient was drowsy (Glasgow Coma Score : E3, V4, M6). He showed 2/5 and 3/5 strength in the right and left lower extremity and 5/5 strength in both upper extremities. Hunt-Hess classification was 3, and

• Received : May 7, 2012 • Revised : November 26, 2012 • Accepted : April 8, 2013

• Address for reprints : Jun Soo Byun, M.D.

Department of radiology, Chung-Ang University Hospital, 102 Heuksuk-dong, Dongjak-gu, Seoul 156-755, Korea

Tel : +82-2-6299-2681, Fax : +82-2-6263-1557, E-mail : flightdr61@cau.ac.kr

• This is an Open Access article distributed under the terms of the Creative Commons Attribution Non-Commercial License (<http://creativecommons.org/licenses/by-nc/3.0>) which permits unrestricted non-commercial use, distribution, and reproduction in any medium, provided the original work is properly cited.

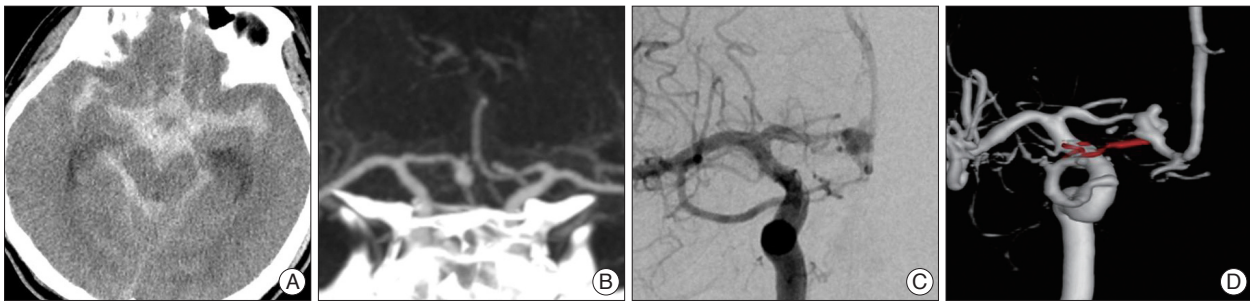


Fig. 1. A and B : Preoperative CT demonstrating subarachnoid hemorrhage and aneurysm in right A1 segment of anterior cerebral artery. C and D : Postoperative angiogram showing a remnant aneurysm in right A1 segment of anterior cerebral artery.

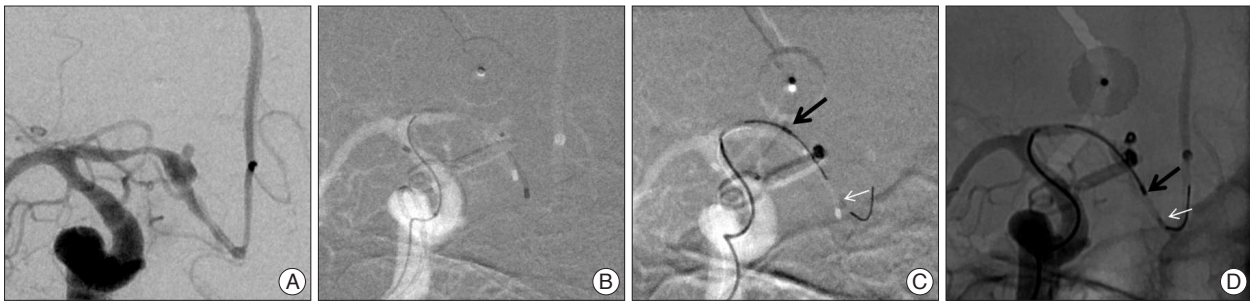


Fig. 2. Sequence of steps during temporary stent-assisted coiling. Note the stent distal markers (white arrow) and microcatheter tip position (black arrow) during coiling. Whenever each coil inserted, the stent was partially recaptured into the Prowler Select Plus microcatheter then the SL-10 microcatheter was removed for angiography to ensure safety of the small caliber parent artery (D).

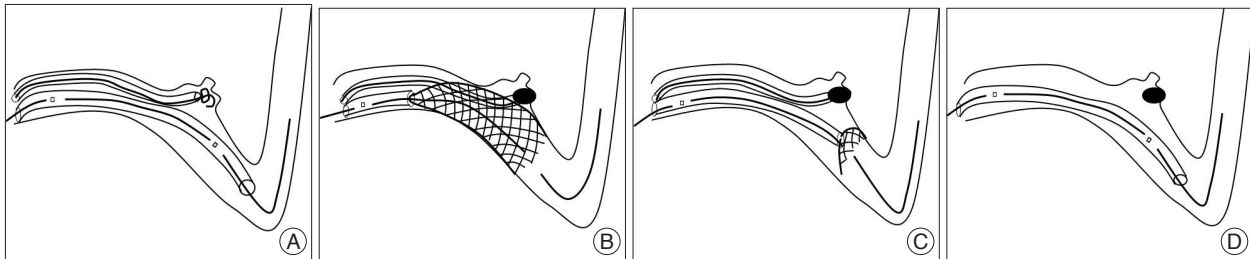


Fig. 3. Illustration of the temporary semi-jailing technique. A : Selection of the aneurysm with microcatheter with a partially introduced coil and introduction of the Enterprise stent. B : Coil embolization with partial deployment of the stent. C : Recapture of the stent after partial coiling. D : Stable coil mass after removal of the microcatheter.

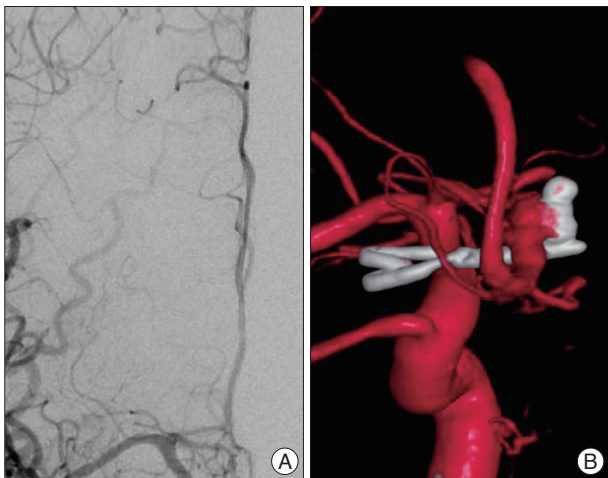


Fig. 4. Final angiography (A) and 3 dimensional reconstruction image (B) demonstrated the coiled aneurysm without parent vessel stenosis or distal flow compromise.

Fisher grade was 4. Initial computed tomography (CT) revealed the presence of a subarachnoid hemorrhage and aneurysm in the A1 segment of the anterior cerebral artery (ACA) with inferior and superior projection. The patient was treated with surgical clipping and upper extremity weakness was fully recovered. But superior and posterior portion of the aneurysm remained on follow-up transfemoral cerebral angiography (Fig. 1). We decided to treat the remnant aneurysm using an endovascular modality.

The patient was placed on 300 mg of clopidogrel, 100 mg of aspirin one day before embolization and 75 mg of clopidogrel, 100 mg of aspirin on the day of operation. Treatment was performed under general anesthesia and via the transfemoral approach. Under full heparinization, a 6-French guide catheter was placed in the right internal carotid artery. A Prowler Select Plus microcatheter (Cordis neurovascular, Miami, FL, USA) was navigated across the aneurysm neck over a 0.014" microguide-wire. An Excelsior SL-10 microcatheter (Striker, Fremont, CA,

USA), for coil delivery were carefully navigated to the aneurysm. Through Prowler Select Plus microcatheter, a 4.5×22 mm Enterprise stent advanced and readied for deployment. The stent was partially deployed (up to 30-60% of its length) bridging the aneurysm's wide neck. Subsequent coil packing (4 coils, sizes ranging from 2×30 mm to 1.5×10 mm, Micrus Endovascular) resulted in subtotal occlusion of the aneurysm without coil herniation through the stent struts into the parent lumen (Fig. 2). Whenever each coil was inserted, the stent was partially recaptured into the Prowler Select Plus microcatheter then the SL-10 microcatheter was removed for angiography to ensure safety of the small caliber parent artery (Fig. 3). A final control angiogram confirmed aneurysm occlusion, and preservation of the blood flow within the territory including A1 segment (Fig. 4). The patient awoke without neurological deficit. One day follow-up CT showed no abnormal low density in ACA territory. Follow-up transcranial doppler ultrasonogram showed patent blood flows of bilateral ACAs (right : left, mean=78 : 74, systolic 118 : 104, diastolic=54 : 55). Further clinical and neurological follow-up examinations are planned after 1 and 3 months, and digital subtraction angiogram (DSA) follow-up are planned after 6 months.

DISCUSSION

The aneurysm remnants after surgical clipping may be caused by anatomic complexities, technical difficulties at the time of surgery and regrowth after surgery^{5,8,11}. In this case, the superior and posterior compartment of aneurysmal sac cannot be clipped because of limitation imposed by the configuration and location of the aneurysm.

Second surgeries usually face scars or dense adhesions surrounding the aneurysm in proportion to the interval between surgeries⁵. With evolution of devices and techniques of endovascular treatment, an alternative to surgical clipping in the management of cerebral aneurysm is now offered. In addition, endovascular and surgical modalities can be successfully incorporated into a single therapeutic plan and can result in good outcome^{7,17}.

From a technical point of view, remnant coiling is usually possible if the remnant is at least as deep as it is wide and if it is at least 2 mm in diameter¹. However, there are several challenging factors in the endovascular treatments of wide-neck aneurysm with small caliber parent artery. First, it is highly possible that protruded coil induce parent artery occlusion. Second, supporting devices such as balloon and stent have several limitations. Using the balloon remodeling technique in small caliber parent artery can cause periodic flow arrest to the parent vessel, which may result in thromboembolic or rupture complications. Permanent stent deployment in small caliber parent artery also has a risk of in-stent stenosis or occlusion as the long-term outcome. The recommended parent vessel diameter for permanent deployment of Enterprise stent is 2.5-4 mm. Another

limitation of stent, not associated with this case, is antiplatelet medication. Stent-assisted coiling of wide-neck aneurysms is not recommended in patients with gastrointestinal bleeding, complex medical problems, or those scheduled for subsequent surgery, and in patients with acute subarachnoid hemorrhage because antiplatelet medication is required. The technique depicted in this case report was very helpful in successfully coiling a wide-neck aneurysm with small caliber parent artery.

There are some important things to do in this procedure that should be discussed. It was very critical to lock the stent delivery wire with a hemostatic valve once the stent was partially deployed, to prevent further deployment of the stent¹². Repeated recapture and coil microcatheter removal are necessary to ensure the patency of a small caliber parent artery on DSA. Before recapture of the stent, it is important to wait for several minutes to make sure of coil mass stability, and ascertain coil mass stability under digital subtraction background during retrieval. If coil movement is detected during stent retrieval, redeployment of the stent would be the rescue maneuver.

CONCLUSION

Temporary stenting for wide neck aneurysm is a feasible technique for wide-neck aneurysm with small caliber parent artery.

References

1. Bendok BR, Ali MJ, Malisch TW, Russell EJ, Batjer HH : Coiling of cerebral aneurysm remnants after clipping. *Neurosurgery* 51 : 693-697; discussion 697-698, 2002
2. Biondi A, Janardhan V, Katz JM, Salvaggio K, Riina HA, Gobin YP : Neuroform stent-assisted coil embolization of wide-neck intracranial aneurysms : strategies in stent deployment and midterm follow-up. *Neurosurgery* 61 : 460-468; discussion 468-469, 2007
3. de Paula Lucas C, Piotin M, Spelle L, Moret J : Stent-jack technique in stent-assisted coiling of wide-neck aneurysms. *Neurosurgery* 62 (5 Suppl 2) : ONS414-ONS416; discussion ONS416-ONS417, 2008
4. Debrun GM, Aletich VA, Kehrli P, Misra M, Ausman JI, Charbel F : Selection of cerebral aneurysms for treatment using Guglielmi detachable coils : the preliminary University of Illinois at Chicago experience. *Neurosurgery* 43 : 1281-1295; discussion 1296-1297, 1998
5. Drake CG, Friedman AH, Peerless SJ : Failed aneurysm surgery. Reoperation in 115 cases. *J Neurosurg* 61 : 848-856, 1984
6. Drake CG, Vanderlinden RG : The late consequences of incomplete surgical treatment of cerebral aneurysms. *J Neurosurg* 27 : 226-238, 1967
7. Feuerberg I, Lindquist C, Lindqvist M, Steiner L : Natural history of postoperative aneurysm rests. *J Neurosurg* 66 : 30-34, 1987
8. Giannotta SL, Litofsky NS : Reoperative management of intracranial aneurysms. *J Neurosurg* 83 : 387-393, 1995
9. Hong B, Patel NV, Gounis MJ, DeLeo MJ 3rd, Linfante I, Wojak JC, et al. : Semi-jailing technique for coil embolization of complex, wide-necked intracranial aneurysms. *Neurosurgery* 65 : 1131-1138; discussion 1138-1139, 2009
10. Kai Y, Hamada J, Morioka M, Yano S, Mizuno T, Kuratsu J : Double microcatheter technique for endovascular coiling of wide-neck aneurysms using a new guiding device for the transcarotid approach : technical note. *Neuroradiology* 47 : 73-77, 2005
11. Lin T, Fox AJ, Drake CG : Regrowth of aneurysm sacs from residual

- neck following aneurysm clipping. *J Neurosurg* 70 : 556-560, 1989
12. Lopes DK, Wells K : Stent remodeling technique for coiling of ruptured wide-neck cerebral aneurysms : case report. *Neurosurgery* 65 : E1007-E1008; discussion E1008, 2009
 13. Mericle RA, Wakhloo AK, Rodriguez R, Guterman LR, Hopkins LN : Temporary balloon protection as an adjunct to endosaccular coiling of wide-necked cerebral aneurysms : technical note. *Neurosurgery* 41 : 975-978, 1997
 14. Pottin M, Blanc R, Spelle L, Mounayer C, Piantino R, Schmidt PJ, et al. : Stent-assisted coiling of intracranial aneurysms : clinical and angiographic results in 216 consecutive aneurysms. *Stroke* 41 : 110-115, 2010
 15. Rabinstein AA, Nichols DA : Endovascular coil embolization of cerebral aneurysm remnants after incomplete surgical obliteration. *Stroke* 33 : 1809-1815, 2002
 16. Thornton J, Bashir Q, Aletich VA, Debrun GM, Ausman JI, Charbel FT : What percentage of surgically clipped intracranial aneurysms have residual necks? *Neurosurgery* 46 : 1294-1298; discussion 1298-1300, 2000
 17. Thornton J, Dovey Z, Alazzaz A, Misra M, Aletich VA, Debrun GM, et al. : Surgery following endovascular coiling of intracranial aneurysms. *Surg Neurol* 54 : 352-360, 2000
 18. Vallee JN, Aymard A, Vicaut E, Reis M, Merland JJ : Endovascular treatment of basilar tip aneurysms with Guglielmi detachable coils : predictors of immediate and long-term results with multivariate analysis 6-year experience. *Radiology* 226 : 867-879, 2003
 19. Yang PF, Liu JM, Huang QH, Zhao WY, Hong B, Xu Y, et al. : Preliminary experience and short-term follow-up results of treatment of wide-necked or fusiform cerebral aneurysms with a self-expanding, closed-cell, retractable stent. *J Clin Neurosci* 17 : 837-841, 2010