

Clinical Article

Back Muscle Changes after Pedicle Based Dynamic Stabilization

Kyung Yun Moon, M.D.,¹ Soo-Eon Lee, M.D.,² Ki-Jeong Kim, M.D.,² Seung-Jae Hyun, M.D.,² Hyun-Jib Kim, M.D., Ph.D.,² Tae-Ahn Jahng, M.D., Ph.D.²

Spine Center, Department of Neurosurgery,¹ Ansan 21st Century Hospital, Ansan, Korea
Department of Neurosurgery,² Seoul National University College of Medicine, Seoul, Korea

Objective : Many studies have investigated paraspinal muscle changes after posterior lumbar surgery, including lumbar fusion. However, no study has been performed to investigate back muscle changes after pedicle based dynamic stabilization in patients with degenerative lumbar spinal diseases. In this study, the authors compared back muscle cross sectional area (MCSA) changes after non-fusion pedicle based dynamic stabilization.

Methods : Thirty-two consecutive patients who underwent non-fusion pedicle based dynamic stabilization (PDS) at the L4-L5 level between February 2005 and January 2008 were included in this retrospective study. In addition, 11 patients who underwent traditional lumbar fusion (LF) during the same period were enrolled for comparative purposes. Preoperative and postoperative MCSAs of the paraspinal (multifidus+longissimus), psoas, and multifidus muscles were measured using computed tomographic axial sections taken at the L4 lower vertebral body level, which best visualize the paraspinal and psoas muscles. Measurements were made preoperatively and at more than 6 months after surgery.

Results : Overall, back muscles showed decreases in MCSAs in the PDS and LF groups, and the multifidus was most affected in both groups, but more so in the LF group. The PDS group showed better back muscle preservation than the LF group for all measured muscles. The multifidus MCSA was significantly more preserved when the PDS-paraspinal-Wiltse approach was used.

Conclusion : Pedicle based dynamic stabilization shows better preservation of paraspinal muscles than posterior lumbar fusion. Furthermore, the minimally invasive paraspinal Wiltse approach was found to preserve multifidus muscles better than the conventional posterior midline approach in PDS group.

Key Words : Dynamic stabilization · Lumbar fusion · Paraspinal muscle · Lumbar spine · Multifidus.

INTRODUCTION

Although spinal fusion is the major surgical option for the treatment of degenerative lumbar spinal disease, many studies have reported subsequent mechanical changes and physiological alterations, which can cause unwanted problems, such as spinal stiffness, the acceleration of adjacent segment degeneration, and chronic low back pain^{6,7}.

Lumbar fusion eliminates motions of functional spinal segments and may overload adjacent segments. Furthermore, surgical trauma and disuse of immobile segments can cause a decrease in paraspinal muscle volume^{8,23,33}. Many authors have addressed the issue of postoperative paraspinal muscle change^{13,14,17,33}. Most have concluded that lumbar fusion affects

back muscles and decreases muscle mass regardless of the surgical approach used.

These drawbacks are known to be related to chronic low back pain and failed back surgery syndrome, and have prompted the developments of alternative procedures and techniques for achieving stabilization without fusion, such as, pedicle based dynamic stabilization. Nevertheless the theoretical advantages of non-fusion pedicle based dynamic stabilization (PDS) over lumbar fusion, such as, the prevention of adjacent segment degeneration^{2,25,27}, have not been clearly confirmed or defined¹⁸. It has also been reported that PDS can preserve to some extent the motion of stabilized segments^{1,19}. However, no study has investigated the effect that this preservation of motion has upon back muscle changes. In the present study, we studied postop-

• Received : August 30, 2012 • Revised : September 25, 2012 • Accepted : February 25, 2013

• Address for reprints : Tae-Ahn Jahng, M.D., Ph.D.

Department of Neurosurgery, Seoul National University Bundang Hospital, 166 Gumi-ro, Bundang-gu, Seongnam 463-707, Korea

Tel : +82-31-787-7171, Fax : +82-31-787-4097, E-mail : taj@snu.ac.kr

• This is an Open Access article distributed under the terms of the Creative Commons Attribution Non-Commercial License (<http://creativecommons.org/licenses/by-nc/3.0>) which permits unrestricted non-commercial use, distribution, and reproduction in any medium, provided the original work is properly cited.

erative back muscle changes after PDS and compared these with back muscle changes after lumbar fusion (LF).

MATERIALS AND METHODS

From February 2005 to January 2008, patients who underwent non-fusion stabilization or fusion were enrolled for this study. The primary diagnosis was degenerative spinal stenosis, and/or degenerative spondylolisthesis. Patients with a history of a previous back operation, revision lumbar surgery, instrumental failure, or perioperative spinal infection were excluded. One senior surgeon performed all surgeries. All patients were followed with our institute routine follow-up protocol, which includes 3-month interval dynamic X-ray and 6-months interval CT scan up to 2 years after operation.

To compare the trend of muscle change with fusion patients, patients with lumbar fusion at L4-L5 segment, operated by same senior surgeon, were enrolled. The author recommended early ambulation, and patients were encouraged to walk immediate postoperative period. There was a difference in wearing time for back brace. It was kept for 3 months after operation in only LF patients, but the patients with PDS did not wear. To quantify muscle changes, paraspinous muscle cross sectional areas (MCSAs) were measured pre- and postoperatively in computerized tomography (CT) images. Postoperative muscle cross sectional area measurements were made using CT scan taken at ≥ 6 months after operation to allow muscle swelling and edema time to subside³¹. Last follow-up CT scans were used. The mean postoperative CT follow-up period was 13.0 ± 8.5 months in the PDS group and 13.6 ± 5.4 months in the LF group. We selected an axial cut parallel to the disc space in the lower L4 body level for measuring MCSAs (Fig. 1). This transaxial cut allowed the paraspinous and psoas muscles to be best visualized with less metallic artifact. The cross sectional area (CSA) of the paraspinous muscle and psoas muscle were measured respectively. The CSA of the multifidus muscle, which contributes most to lumbar segmental stability, and which is more directly affected by heat injury during dissection from the adjacent spine and during retraction, was measured separately. We compared the CSAs of these muscles in the PDS and LF groups, and for different surgical approaches. To exclude fatty degeneration of back muscle, regions of decreased density around the muscle were not included in CSA measurements. However, regions of intramuscular decreased density were not excluded due to technical difficulties. The measurements were made using image analyzer software (M-view[®] version 5.4, Marotech, Seoul, Korea). To test intraobserver reliability, one independent observer repeated measurements three times using the same protocol, and was found to have an accuracy coefficient of 0.71-0.96.

SPSS software (version 12.0, 2003; SPSS Inc., Chicago, IL, USA) was used throughout. The Wilcoxon signed ranks test was used to analyze non-categorical variables, and *p* values of < 0.05 were considered statistically significant.

RESULTS

Thirty-two patients who underwent non-fusion pedicle based dynamic stabilization, including the L4-L5 segments. All patients had interview for surgical approach before operation and only patient who agreed was included for non-fusion stabilization with informed consent and permission of IRB. Posterior midline approach or paraspinous approach was randomly assigned. In the same period, 11 patients was met the same criteria as like non-fusion stabilization during same time period.

In the PDS group, there were 12 males and 20 females of mean age 61.8 years (range 46 to 76 years). All patients in this group underwent pedicle based dynamic stabilization without fusion. The Dynesys[®] (Zimmer Spine, IN, USA) was used in 21 patients, and the N-flex[®] (Synthes Spine, West Chester, PA, USA) controlled stabilization system in the other 11 patients. Regarding, surgical approaches, 21 traditional posterior midline approaches (PDS-PM) and 11 minimally invasive paraspinous Wiltse approaches (PDS-PW) were used. In the 11 patients with lumbar fusion and instrumentation (LF) group, there were 7 males and 4 females of mean age 59.8 years (range 37 to 70 years). All patients underwent lumbar interbody fusion and pedicle screw fixation at L4-L5. For lumbar fusion, a traditional posterior midline (LF-PM) approach was used in 7 patients and the minimally invasive paraspinous Wiltse (LF-PW) approach in 4 as described²².

Mean operative time of whole operative procedure including decompression and instrumentation was 204.2 ± 41.8 minutes (range, 120-300) in PDS group, and it was 223.9 ± 65.5 minutes (range, 100-340) in LF group. In PDS-PM group, the mean operative time was 219.1 ± 44.2 minutes (range, 120-300), while it was 178.3 ± 20.4 minutes (range, 90-200) in PDS-PW group. In LF group, it was 250.8 ± 56.2 minutes (range, 100-340) with PM approach, and it was 197.1 ± 40.4 minutes (range, 90-240) with PW approach.

In the PDS group, mean preoperative MCSA of paraspinous muscles (multifidus+longissimus) was 2122.8 ± 349.9 mm², and mean postoperative MCSA was 1969.2 ± 310.4 mm², which was $93.1 \pm 5.7\%$ of the preoperative value. MCSA decreased by an average of 153.5 mm². Mean postoperative MCSA of the mul-

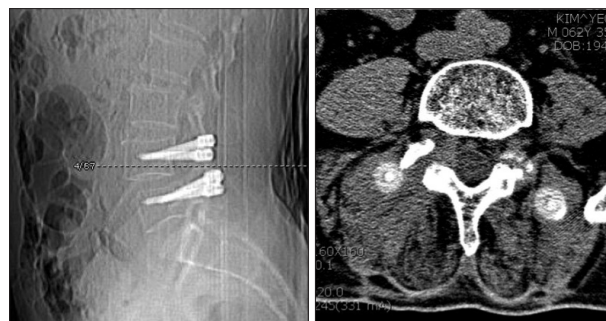

Fig. 1. Postoperative lateral CT image in axial section at the lower L4 body level (left). This imaging technique best visualized paraspinous and psoas muscles and reduced metallic artifacts.

Table 1. Pre- and postoperative values in the PDS and LF groups

	Posterior dynamic stabilization (PDS), n=32	Lumbar fusion (LF), n=11	p-value
Mean age (yrs)	61.8 (46-76)	59.8 (37-70)	0.631
Mean CT follow-up (months)	13±8.5	13.6±5.4	0.189
Operative time (min)	204.2±41.8	223.9±65.5	0.361
Paraspinal MCSA			
Preoperative (mm ²)	2122.8±349.9	2235.9±365	
Postoperative (mm ²)	1969.2±310.4	1963.5±408.6	
Percentage change (%)	93.1±5.7	87.4±6.9	0.012*
Multifidus MCSA			
Preoperative (mm ²)	629.8±182.6	657.9±167.4	
Postoperative (mm ²)	565.3±160.7	481.8±130.7	
Percentage change (%)	90.7±10.8	73.5±9.0	0.001*
Psoas MCSA			
Preoperative (mm ²)	965.4±397.4	985.3±311.3	
Postoperative (mm ²)	918.8±397.3	879.1±294.3	
Percentage change (%)	95.5±9.9	88.7±6.9	0.049*

*p<0.05 (Mann-Whitney U test). MCSA : muscle cross sectional area

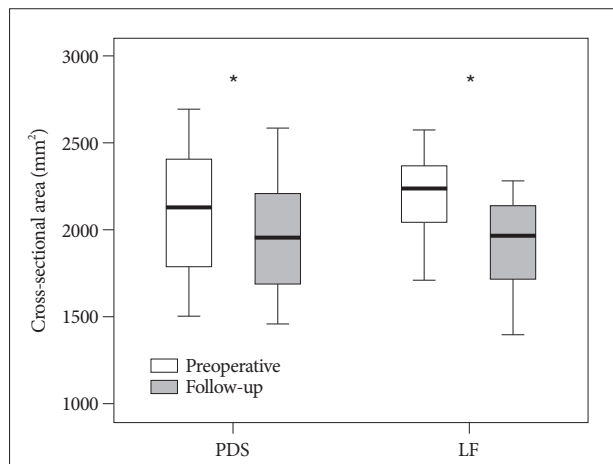


Fig. 2. Postoperative muscle cross-sectional area changes for paraspinal muscles in the posterior dynamic stabilization (PDS) and lumbar fusion (LF) groups. *p<0.05 (Wilcoxon's signed ranks test).

tifidus decreased from a preoperative mean of 629.8±182.6 to 565.3±160.7 mm², which was 90.7±10.8% of the preoperative value. Mean psoas MCSA also decreased to 95.5±9.9% of its preoperative value (965.4±397.4 mm² vs. 918.8±397.3 mm²) (Table 1).

In the LF group, mean paraspinal MCSA decreased significantly (87.4±6.9% decrease, preoperative 2235.9±365 mm², and postoperative 1963.5±408.6 mm²). Mean multifidus MCSA also showed a significant decrease (657.9±167.4 mm² preoperatively and 481.8±130.7 mm² at last follow-up), and this represented an MCSA of only 73.5±9.0% as compared with the preoperative state. The reduction of psoas MCSA mean MCSA was similar to that of paraspinal muscle (88.7±6.9%, 985.3±311.3 vs. 879.1±294.3).

Overall, MCSAs of back muscles decreased in both study groups. The multifidus was the most affected muscle both groups. However, the PDS group showed greater back muscle preservation for all measured muscles. In particular, mean multifidus MCSA decreased more significantly in the LF group. Overall changes in the CSAs of paraspinal muscles (multifidus+longissimus) in the two groups are shown (Fig. 2, 3).

The 32 patients in the PDS group were divided to two subgroups according to surgical approach, namely, into 21 patients that underwent the traditional posterior midline approach (the PDS-PM group, mean age 61.9±7.2 years, mean CT follow-up 13.0±8.6 months), and 11 patients that underwent minimally invasive paraspinal Wiltse's approach (the PDS-PW group, mean age 61.9±9.5 years, mean CT follow-up 13.1±8.6 months).

In the PDS-PM group, mean preoperative paraspinal MCSA was 2124.2±332.1 mm² and this was decreased to 1954.2±316.4 mm² (92.2±5.9%). For the multifidus, MCSA decreased significantly from a mean preoperative value of 661.3±196.7 mm² to a mean postoperative value of 562.4±170.8 mm² (85.8±10.1%). Mean psoas change in the PDS-PM group was similar to that observed in the PDS group (95.0±11.0%). In the PDS-PW group, paraspinal MCSA decreased from 2120±398.7 to 1997.8±311.6 mm² (94.8±5.0%) postoperatively, but mean multifidus MCSA did not decrease (569.5±141.1 mm² preoperatively and 571.0±147.4 mm² postoperatively), and multifidus MCSA was maintained significantly better in the PDS-PW group than in the PDS-PM or LF groups. Paraspinal muscle changes were slightly lower in the PDS-PW group than in the PDS-PM group (Table 2).

Among 11 LF patients, no significant differences were found between the posterior midline approach and the paraspinal Wiltse approach. In the LF-PM group (7 patients), mean preoperative paraspinal MCSA was 2267.4±196.5 mm² and this was decreased to 2046.6±165.7 mm² (90.3±3.9%). For the multifidus, MCSA decreased significantly from a mean preoperative value of 676.8±86.0 mm² to a mean postoperative value of 510.0±112.8 mm² (75.0±10.7%). In the LF-PW group (4 patients), paraspinal MCSA decreased from 2268.3±635.2 mm² to 2000.0±707.2 mm² (86.9±6.8%) postoperatively, and mean multifidus MCSA was decreased to 76.1±13.5% of its preoperative value (637.8±270.0 mm² preoperatively and 471.3±161.9 mm² postoperatively). Mean psoas change was similar in both LF-PM and LF-PW group (88.6±8.5% vs. 90.5±6.4%). Although number of patients was so small to draw conclusion, results revealed minimally invasive LF-PW group did not show better muscle preservation.

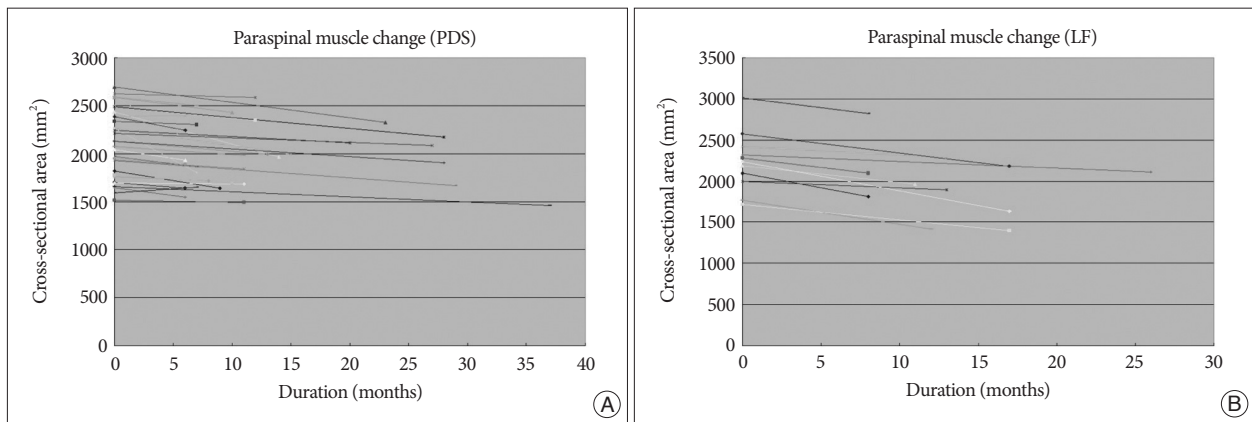


Fig. 3. The longitudinal changes in paraspinal muscle cross-sectional areas in the PDS (A) and LF (B) groups. A : Paraspinal muscle cross-sectional areas changes in patients that underwent dynamic stabilization. B : Paraspinal muscle cross-sectional areas changes in patients that underwent posterior lumbar fusion. PDS : posterior dynamic stabilization, LF : lumbar fusion.

DISCUSSION

Posterior lumbar spine surgery inevitably affects back muscles, and may induce subsequent anatomical and physiological changes. Previous studies have determined that dissection and retraction of the paraspinal musculature can lead to denervation and atrophy, and thus, increase the risk of chronic back pain and failed back surgery syndrome^{6,7,15,30}. In particular, after lumbar fusion, paraspinal muscles may undergo atrophy because of the long duration of muscle retraction, large areas of muscle stripping, mechanical and heat injuries to the dorsal rami of the posterior branches, and disturbance of the arterial supply to paraspinal muscles. This muscle atrophy may be exaggerated by postoperative muscle disuse or deconditioning following immobilization of the spine^{9,10,20,33}.

These changes in paraspinal muscle functions after fusion may cause chronic back pain and failed back surgery syndrome.

All muscles in the lumbar region contribute to lumbar stability. The multifidus muscle, which is the most important muscle in terms of lumbar segmental stability, is the largest paraspinal muscle located in the most medial portion of the paraspinal muscle. Recent study using architectural design demonstrates that the multifidus muscle is uniquely designed as a stabilizer to produce large forces³⁶. The multifidus, is innervated only by the medial branches of the dorsal ramus without intersegmental nerve supply³, and is the muscle most directly affected by heat injury during retraction and dissection from the adjacent spine. To prevent muscle injuries, intermittent release of the retractor during surgery or different surgical approaches have been recommended^{12,34,37}. The paraspinal Wiltse approach allows manual dissec-

Table 2. Pre- and postoperative for the posterior midline and paraspinal Wiltse approaches in the PDS group

	Paraspinal wiltse approach (DS-PW), n=11	Posterior midline (DS-PM), n=21	p-value
Mean age (yrs)	61.9±9.5 (46-76)	61.9±7.2 (50-74)	0.969
Mean CT follow-up (months)	13.1±8.6	13.0±8.6	0.815
Operative time (min)	178.3±20.4	219.1±44.2	0.030
Paraspinal MCSA			
Preoperative (mm ²)	2120.0±398.7	2124.2±332.1	
Postoperative (mm ²)	1997.8±311.6	1954.2±316.4	
Percentage change (%)	94.8±5.0	92.2±5.9	0.389
Multifidus MCSA			
Preoperative (mm ²)	569.5±141.1	661.3±196.7	
Postoperative (mm ²)	571.0±147.7	562.4±170.8	
Percentage change (%)	100.0±3.0	85.5±10.1	<0.001*
Psoas MCSA			
Preoperative (mm ²)	973.8±585.2	961.0±271.2	
Postoperative (mm ²)	939.5±594.5	908.1±260.1	
Percentage change (%)	96.6±7.5	95.0±11.0	0.755

*p<0.05 (Mann-Whitney U test). MCSA : muscle cross sectional area

tion of the multifidus and longissimus muscles to expose the transverse process and lateral aspect of the facet joint with minimal retraction, and thus, this approach may reduce the likelihoods of heat and retraction injuries to paraspinal muscles³³. The paraspinal Wiltse approach and the percutaneous fixation technique are known to preserve paraspinal muscles better in fusion patients because severe muscle injuries and paraspinal muscle denervation can be avoided using these approaches^{11,16,17}. Other reports have shown that the minimally invasive approach causes less paraspinal muscle damage than the traditional approach and that it has positive effects on postoperative trunk muscle performance^{5,11,16}. There were few comparative long-term follow-up studies between minimally invasive surgery (MIS) and traditional fusion surgery. Recent two prospective studies revealed that MIS was a method that minimizes

damage to the soft tissue and regional muscle immediately after surgery; however, after a period of more than 1 year, there was no significant difference in the paraspinal degenerative change between MIS and traditional surgery^{21,35}. In fact, Remes et al.²⁴ noted that all fusion procedures cause back muscle damage in the long-term. In their report, anterior lumbar interbody fusion, which does not involve the manipulation of back muscles directly, was found to be associated with back muscle atrophy like posterior lumbar interbody fusion and circumferential fusion. This implies that loss of motion affects paraspinal muscle integrity regardless of the surgical approach used, especially in long-term. Accordingly, preservation of motion might play an important role in the maintenance of back muscle integrity besides initial surgical trauma.

Recently non-fusion pedicle-based dynamic stabilization has been introduced as an alternative procedure for the surgical treatment of lumbar degenerative spinal disease. This technique was designed to reduce fusion problems, such as, adjacent segment degeneration and chronic back pain, by permitting limited motion and changing loading patterns at stabilized segments without fusion^{26,29,32}. Although some reports have advocated its advantages over fusion and presented excellent clinical outcomes^{4,28,38}, it is uncertain whether PDS can prevent the progression of adjacent segment degeneration (ASD), and no study has yet documented the real benefit of PDS. However, although it remains unclear whether PDS can prevent ASD, most reports demonstrated that the stabilized segment retains some motion. Thus we focused on the effect of this retained motion at stabilized segments, and sought to determine how preserved motion affects back muscle integrity.

In the present study, we found that both procedures were associated with a decrease in back muscle CSA. However, paraspinal muscle cross sectional area was better preserved in the PDS group regardless of the surgical approach. Furthermore, in the PDS group, the minimally invasive paraspinal Wiltse approach better preserved multifidus muscle. In the LF group, postoperative MCSA decreased significantly more than in the PDS group. We also found that LF did not preserve paraspinal muscles even when a minimally invasive approach was used. Although only 4 of the 11 patients in the LF group underwent a minimally invasive procedure and significance was not critical due to small number of patients, minimally invasive paraspinal lumbar fusion revealed similar back muscle decrease compared to the traditional posterior midline approach. Minimally invasive surgery for lumbar fusion may have benefits during the early postoperative stage, but it may not have long-term benefits. Although initial surgical trauma plays a certain role in paraspinal muscle integrity, our results demonstrate that preservation of motion is probably more important than surgical trauma for paraspinal muscle integrity in the long-term. The present study suggests that the preservation of back muscles in the long-term is the real benefit of PDS over LF.

There are several possible explanations as to why PDS better

preserves back muscles. First, PDS can preserve some motion at stabilized segments, and this preserved motion helps prevent muscle disuse and atrophy. Second, PDS requires less operative time than LF and causes less injury. Furthermore, PDS does not require fusion bed preparation, facet joint violation, or a bone harvesting procedure, and thus, is less invasive, less traumatic, and less time consuming than LF. We encourage early ambulation and active back muscle exercises, and this probably contributed to the MCSA differences observed between the two study groups.

Some limitations of this study should be clarified. First, because of the retrospective nature of the study, the level of evidence was not strong as prospective ones. Second, the length of the postoperative follow-up period and the number of patients recruited were not sufficient to evaluate long-term outcome. Third, we compared back muscle cross sectional area and did not perform physiologic functional evaluations. Furthermore, we have no data regarding adjacent segment muscle changes, and it is possible that compensatory hypertrophy occurred at adjacent segment in LF patients as Hu et al.¹⁰ suggested in experimental study. Finally, we did not study relations between muscle change and clinical outcomes. Nevertheless, despite its limitations, the present study is the first to evaluate muscle changes after dynamic stabilization, and it shows that PDS better preserves back muscles than LF. Furthermore, it suggests that motion preservation at stabilized segments is crucial for the maintenance of postoperative back muscle integrity, and that the surgical approach used also plays a role in back muscle preservation.

CONCLUSION

Pedicle-based dynamic stabilization was found to preserve paraspinal muscles better than posterior lumbar fusion in patients with degenerative lumbar spinal diseases. Furthermore, the minimally invasive paraspinal Wiltse approach was found to preserve paraspinal muscles more than the conventional midline approach in PDS group.

This study also suggests that the preservation of motion at stabilized segments contributes more to postoperative back muscle preservation than initial back muscle injury caused by surgical manipulation and retraction.

References

1. Acosta FL, Christensen FB, Coe JD, Jahng TA, Kitchel SH, Meiser HJ, et al. : Early clinical and radiographic results of NFix II posterior dynamic stabilization system. *SAS J* 2 : 69-75, 2008
2. Beastall J, Karadimas E, Siddiqui M, Nicol M, Hughes J, Smith F, et al. : The Dynesys lumbar spinal stabilization system : a preliminary report on positional magnetic resonance imaging findings. *Spine (Phila Pa 1976)* 32 : 685-690, 2007
3. Bogduk N, Wilson AS, Tynan W : The human lumbar dorsal rami. *J Anat* 134 (Pt 2) : 383-397, 1982
4. Cakir B, Ulmar B, Koeppe H, Huch K, Puhl W, Richter M : [Posterior

- dynamic stabilization as an alternative for dorso-ventral fusion in spinal stenosis with degenerative instability]. *Z Orthop Ihre Grenzgeb* 141 : 418-424, 2003
5. Foley KT, Holly LT, Schwender JD : Minimally invasive lumbar fusion. *Spine (Phila Pa 1976)* 28 (15 Suppl) : S26-S35, 2003
 6. Fritzell P, Hägg O, Nordwall A; Swedish Lumbar Spine Study Group : Complications in lumbar fusion surgery for chronic low back pain : comparison of three surgical techniques used in a prospective randomized study. A report from the Swedish Lumbar Spine Study Group. *Eur Spine J* 12 : 178-189, 2003
 7. Fritzell P, Hägg O, Wessberg P, Nordwall A; Swedish Lumbar Spine Study Group : Chronic low back pain and fusion : a comparison of three surgical techniques : a prospective multicenter randomized study from the Swedish lumbar spine study group. *Spine (Phila Pa 1976)* 27 : 1131-1141, 2002
 8. Gille O, Jolivet E, Dousset V, Degrise C, Obeid I, Vital JM, et al. : Erector spinae muscle changes on magnetic resonance imaging following lumbar surgery through a posterior approach. *Spine (Phila Pa 1976)* 32 : 1236-1241, 2007
 9. Hu Y, Leung HB, Lu WW, Luk KD : Consequence of paraspinal muscle after spinal fusion : an experimental study. *Stud Health Technol Inform* 123 : 461-466, 2006
 10. Hu Y, Leung HB, Lu WW, Luk KD : Histologic and electrophysiological changes of the paraspinal muscle after spinal fusion : an experimental study. *Spine (Phila Pa 1976)* 33 : 1418-1422, 2008
 11. Hyun SJ, Kim YB, Kim YS, Park SW, Nam TK, Hong HJ, et al. : Postoperative changes in paraspinal muscle volume : comparison between paramedian interfascial and midline approaches for lumbar fusion. *J Korean Med Sci* 22 : 646-651, 2007
 12. Kawaguchi Y, Matsui H, Gejo R, Tsuji H : Preventive measures of back muscle injury after posterior lumbar spine surgery in rats. *Spine (Phila Pa 1976)* 23 : 2282-2287; discussion 2288, 1998
 13. Kawaguchi Y, Matsui H, Tsuji H : Back muscle injury after posterior lumbar spine surgery. A histologic and enzymatic analysis. *Spine (Phila Pa 1976)* 21 : 941-944, 1996
 14. Kawaguchi Y, Matsui H, Tsuji H : Back muscle injury after posterior lumbar spine surgery. Part 2 : histologic and histochemical analyses in humans. *Spine (Phila Pa 1976)* 19 : 2598-2602, 1994
 15. Kawaguchi Y, Matsui H, Tsuji H : Changes in serum creatine phosphokinase MM isoenzyme after lumbar spine surgery. *Spine (Phila Pa 1976)* 22 : 1018-1023, 1997
 16. Kim DY, Lee SH, Chung SK, Lee HY : Comparison of multifidus muscle atrophy and trunk extension muscle strength : percutaneous versus open pedicle screw fixation. *Spine (Phila Pa 1976)* 30 : 123-129, 2005
 17. Kim K, Isu T, Sugawara A, Matsumoto R, Isobe M : Comparison of the effect of 3 different approaches to the lumbar spinal canal on postoperative paraspinal muscle damage. *Surg Neurol* 69 : 109-113; discussion 113, 2008
 18. Kumar A, Beastall J, Hughes J, Karadimas EJ, Nicol M, Smith F, et al. : Disc changes in the bridged and adjacent segments after Dynesys dynamic stabilization system after two years. *Spine (Phila Pa 1976)* 33 : 2909-2914, 2008
 19. Lee SE, Park SB, Jahng TA, Chung CK, Kim HJ : Clinical experience of the dynamic stabilization system for the degenerative spine disease. *J Korean Neurosurg Soc* 43 : 221-226, 2008
 20. Mayer TG, Vanharanta H, Gatchel RJ, Mooney V, Barnes D, Judge L, et al. : Comparison of CT scan muscle measurements and isokinetic trunk strength in postoperative patients. *Spine (Phila Pa 1976)* 14 : 33-36, 1989
 21. Min SH, Kim MH, Seo JB, Lee JY, Lee DH : The quantitative analysis of back muscle degeneration after posterior lumbar fusion : comparison of minimally invasive and conventional open surgery. *Asian Spine J* 3 : 89-95, 2009
 22. Moon KY, Jahng TA : Minimally invasive lumbar decompression, interbody fusion, and pedicle screw fixation - Preliminary Report -. *J Korean Neurosurg Soc* 35 : 267-272, 2004
 23. Motosuneya T, Asazuma T, Tsuji T, Watanabe H, Nakayama Y, Nemoto K : Postoperative change of the cross-sectional area of back musculature after 5 surgical procedures as assessed by magnetic resonance imaging. *J Spinal Disord Tech* 19 : 318-322, 2006
 24. Remes V, Lamberg T, Tervahartiala P, Helenius I, Schlenzka D, Yrjönen T, et al. : Long-term outcome after posterolateral, anterior, and circumferential fusion for high-grade isthmic spondylolisthesis in children and adolescents : magnetic resonance imaging findings after average of 17-year follow-up. *Spine (Phila Pa 1976)* 31 : 2491-2499, 2006
 25. Rohlmann A, Burra NK, Zander T, Bergmann G : Comparison of the effects of bilateral posterior dynamic and rigid fixation devices on the loads in the lumbar spine : a finite element analysis. *Eur Spine J* 16 : 1223-1231, 2007
 26. Sapakas GS, Themistocleous GS, Mavrogenis AF, Benetos IS, Metaxas N, Papagelopoulos PJ : Stabilization of the lumbar spine using the dynamic neutralization system. *Orthopedics* 30 : 859-865, 2007
 27. Schmoelz W, Huber JF, Nydegger T, Dipl-Ing, Claes L, Wilke HJ : Dynamic stabilization of the lumbar spine and its effects on adjacent segments : an in vitro experiment. *J Spinal Disord Tech* 16 : 418-423, 2003
 28. Schnake KJ, Schaeren S, Jeanneret B : Dynamic stabilization in addition to decompression for lumbar spinal stenosis with degenerative spondylolisthesis. *Spine (Phila Pa 1976)* 31 : 442-449, 2006
 29. Sengupta DK : Dynamic stabilization devices in the treatment of low back pain. *Orthop Clin North Am* 35 : 43-56, 2004
 30. Sihvonen T, Herno A, Paljärvi L, Airaksinen O, Partanen J, Tapaninaho A : Local denervation atrophy of paraspinal muscles in postoperative failed back syndrome. *Spine (Phila Pa 1976)* 18 : 575-581, 1993
 31. Stevens KJ, Spenciner DB, Griffiths KL, Kim KD, Zwienerberg-Lee M, Alamin T, et al. : Comparison of minimally invasive and conventional open posterolateral lumbar fusion using magnetic resonance imaging and retraction pressure studies. *J Spinal Disord Tech* 19 : 77-86, 2006
 32. Stoll TM, Dubois G, Schwarzenbach O : The dynamic neutralization system for the spine : a multi-center study of a novel non-fusion system. *Eur Spine J* 11 Suppl 2 : S170-S178, 2002
 33. Suwa H, Hanakita J, Ohshita N, Gotoh K, Matsuoka N, Morizane A : Postoperative changes in paraspinal muscle thickness after various lumbar back surgery procedures. *Neurol Med Chir (Tokyo)* 40 : 151-154; discussion 154-155, 2000
 34. Taylor H, McGregor AH, Medhi-Zadeh S, Richards S, Kahn N, Zadeh JA, et al. : The impact of self-retaining retractors on the paraspinal muscles during posterior spinal surgery. *Spine (Phila Pa 1976)* 27 : 2758-2762, 2002
 35. Wang HL, Lü FZ, Jiang JY, Ma X, Xia XL, Wang LX : Minimally invasive lumbar interbody fusion via MAST Quadrant retractor versus open surgery : a prospective randomized clinical trial. *Chin Med J (Engl)* 124 : 3868-3874, 2011
 36. Ward SR, Kim CW, Eng CM, Gottschalk LJ 4th, Tomiya A, Garfin SR, et al. : Architectural analysis and intraoperative measurements demonstrate the unique design of the multifidus muscle for lumbar spine stability. *J Bone Joint Surg Am* 91 : 176-185, 2009
 37. Weiner BK, Walker M, Brower RS, McCulloch JA : Microdecompression for lumbar spinal canal stenosis. *Spine (Phila Pa 1976)* 24 : 2268-2272, 1999
 38. Welch WC, Cheng BC, Awad TE, Davis R, Maxwell JH, Delamarter R, et al. : Clinical outcomes of the Dynesys dynamic neutralization system : 1-year preliminary results. *Neurosurg Focus* 22 : E8, 2007