

Clinical Article

Effect of Electromagnetic Navigated Ventriculoperitoneal Shunt Placement on Failure Rates

Nayoung Jung, M.D., Dongwon Kim, M.D., Ph.D.

Department of Neurosurgery, Dongsan Medical Center, Keimyung University College of Medicine, Daegu, Korea

Objective : To evaluate the effect of electromagnetic (EM) navigation system on ventriculoperitoneal (VP) shunt failure rate through comparing the result of standard shunt placement.

Methods : All patients undergoing VP shunt from October 2007 to September 2010 were included in this retrospective study. The first group received shunt surgery using EM navigation. The second group had catheters inserted using manual method with anatomical landmark. The relationship between proximal catheter position and shunt revision rate was evaluated using postoperative computed tomography by a 3-point scale. 1) Grade I; optimal position free-floating in cerebrospinal fluid, 2) Grade II; touching choroid or ventricular wall, 3) Grade III; tip within parenchyma.

Results : A total of 72 patients were participated, 27 with EM navigated shunts and 45 with standard shunts. Grade I was found in 25 patients from group 1 and 32 patients from group 2. Only 2 patients without use of navigation belonged to grade III. Proximal obstruction took place 7% in grade I, 15% in grade II and 100% in grade III. Shunt revision occurred in 11% of group 1 and 31% of group 2. Compared in terms of proximal catheter position, there was growing trend of revision rate according to increase of grade on each group. Although infection rate was similar between both groups, the result had no statistical meaning ($p=0.905$, chi-square test).

Conclusion : The use of EM navigation in routine shunt surgery can eliminate poor shunt placement resulting in a dramatic reduction in failure rates.

Key Words : Hydrocephalus · Neuronavigation · Ventriculoperitoneal shunt · Revision.

INTRODUCTION

Proximal catheter obstruction is known to be the most common cause of malfunctioning of ventriculoperitoneal (VP) shunt followed by infection and disconnection^{14,17}. The optimal position of the catheter tip was focused to reduce potential occlusion of proximal catheter by ventricular parenchyma or choroidal tissues^{1,4,12}. Many studies including Tuli et al.²² have shown that a ventricular catheter tip surrounded by cerebrospinal fluid (CSF) could decrease the risk of shunt failure²⁵.

Accurate placement of ventricular catheter is related with both proper insertion trajectory and proper catheter tip positioning. So recently, many studies have validated accuracy in VP shunt with the development of frameless neuronavigation in the field of neurosurgery^{2,25}. However, it has not clearly proven that the role of the catheter position using navigation system on failure rates. The authors conducted a retrospective study of navigated shunt placement about real impact on clinical shunt failure

rates, comparing with standard shunt placement.

MATERIALS AND METHODS

Patient population and study design

A retrospective analysis was performed on 72 patients who underwent first VP shunt surgery at our institution within four years from October 2007 to September 2010. All adult and pediatric patients with hydrocephalus of any origin participated in this study. Patients with slit ventricles and those with revision cases were excluded to minimize selection bias.

Each patient had a precise chart review with multiple variables including age, causes of hydrocephalus, the number of shunt revisions, interval time between the first shunt operation and revision, and reason for shunt failure. All patients had preoperative and postoperative brain imaging to reveal the outcomes of shunt surgery.

All patients were divided into 2 groups according to the use

• Received : August 3, 2012 • Revised : December 27, 2012 • Accepted : February 25, 2013

• Address for reprints : Dongwon Kim, M.D., Ph.D.

Department of Neurosurgery, Dongsan Medical Center, Keimyung University College of Medicine, 56 Dalseong-ro, Jung-gu, Daegu 700-712, Korea
Tel : +82-53-250-7333, Fax : +82-53-250-7356, E-mail : dongwon@dsmc.or.kr

• This is an Open Access article distributed under the terms of the Creative Commons Attribution Non-Commercial License (<http://creativecommons.org/licenses/by-nc/3.0>) which permits unrestricted non-commercial use, distribution, and reproduction in any medium, provided the original work is properly cited.

of electromagnetic (EM) navigation on surgery. The first group received surgery using EM navigation (Stealth Station Axiem navigation system, Medtronic Incorporation, Louisville, USA) for routine shunt placement. The second group had catheters inserted using manual method with anatomical landmark. Each of shunt revision cases was reconsidered focusing on the causes of shunt failure and catheter position. Patients with shunts were followed up for more than 3 months or until the shunt failure in both groups.

Statistics were generated such as percentages and mean/median values by the data collected from the patients' medical records. Data were analyzed by using statistical methods on the Statistical package for the social sciences version 19. Statistical significance was set at $p < 0.05$.

Surgical techniques

Shunt procedures were performed by neurosurgeons with various training levels. The valve type and catheter were determined depending on the surgeon's preference. In the standard group, skin incision and trepanation of the cranium were done by using anatomical landmarks like Kocher's point or Frazier's point. Ventricular catheter length was determined based on surgeon's measurement using brain computed tomography (CT) imaging. In the EM group, preoperative data acquisition in 3 planes was obtained by CT or magnetic resonance imaging. The dynamic reference frame (DRF), a magnetic field detector within the navigational field, was implanted in an area away from the proposed catheter entry site like Kocher's point or Frazier's point (Fig. 1). After system registration, the surgical plan could be created from the entry site to the final tip position of catheter. The ventricular catheter was placed over the guiding stylet which the detector coils wrapped around the tip of it. The complex was intended to penetrate the ventricular wall along the planned pathway.

Grading system of shunt placement

Proximal catheter position was graded on postoperative brain CT imaging on each case. All patients were graded according the following 3-point scale developed for this study (Fig. 2) : 1) Grade I; catheter tip position free-floating in CSF, away from ventricular wall or choroid plexus, 2) Grade II; catheter tip touching choroid plexus or ventricular

wall, 3) Grade III; tip within parenchyma or failure to reach the intraventricular space.

RESULTS

A total of 72 patients were participated in this study, 27 with the EM navigated shunts and 45 with the standard shunts. Eleven patients were children (11% of in the EM group, as 17% of the standard group) and 61 patients were adults. Patients had numerous causes from congenital anomaly to spontaneous or traumatic intracranial hemorrhage. Time interval of follow-up period was various from a day to 20 months. The baseline characteristics of the study patients are shown in Table 1.

Grade of shunt placement

Grade I was found in 25 patients (93% of 27 patients) from the EM guided group and 32 patients (71% of 45 patients) from the standard group. The EM navigated shunts had catheter tip more free floating in CSF (Grade I) compared with one of the standard shunts ($p=0.03$, chi-square test). Eleven patients (24%) in the standard shunts were classified as grade II compared with 2 patients (7%) in the EM navigated group. Only 2 shunts (4%) were

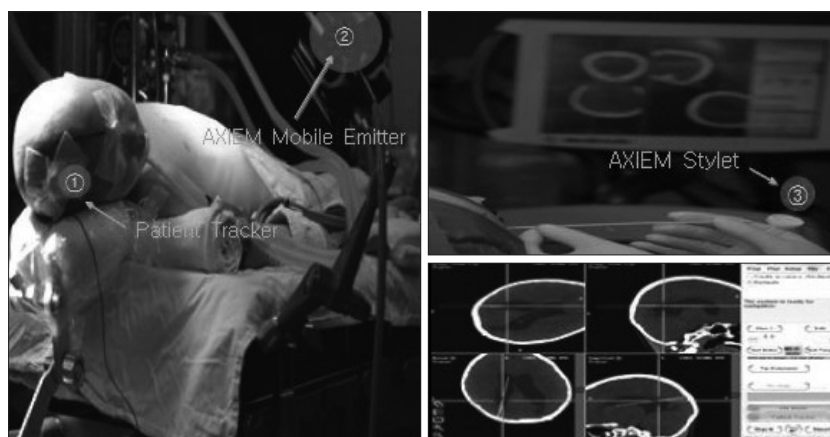


Fig. 1. The operation with electromagnetic navigation system. A noninvasive dynamic reference frame applied to the scalp is shown to identify the location of anatomy within the frame of reference. The bur hole and catheter trajectory were planned preoperatively in three planes to achieve optimal catheter tip position. The navigation stylet is used as the catheter trocar.

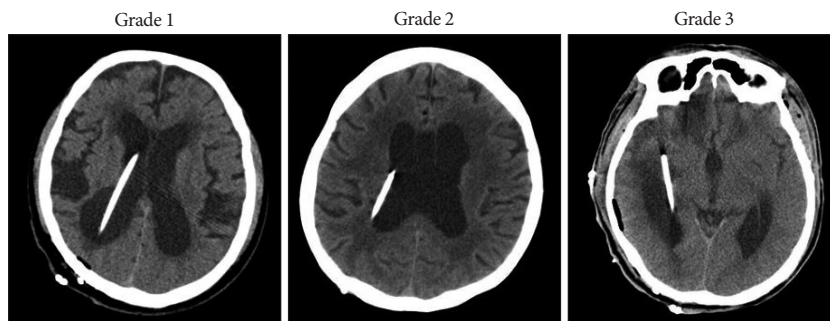


Fig. 2. Grading of ventricular catheter position (three-point scales). 1) Grade I; optimal catheter tip position free-floating in CSF. 2) Grade II; catheter tip touching choroid plexus or ventricular lining wall. 3) Grade III; tip within parenchyma or failure to reach the intraventricular space. CSF : cerebrospinal fluid.

Table 1. The baseline characteristics of the patients in this study

	Number of patients in EM group	Number of patients in standard group
Age		
Neonate	3	2
Children <18	0	6
Adults	24	37
Cause of hydrocephalus		
Congenital	4	6
SAH/AVM	8	16
ICH or IVH	8	6
Infection	0	1
NPH	2	4
Tumor	2	4
Traumatic injury	3	8
Grade of placement		
1	25	32
2	2	11
3	0	2
Total cases	27	45

SAH : subarachnoid hemorrhage, AVM : arteriovenous malformation, ICH : intracerebral hemorrhage, IVH : intraventricular hemorrhage, EM : electromagnetic

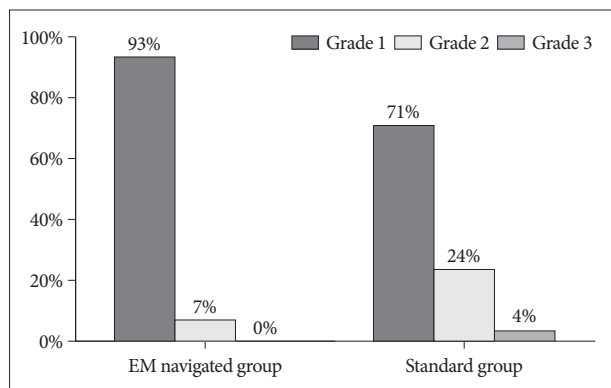


Fig. 3. Grade of shunt catheter placement. This paragraph demonstrates that EM-navigated group can get the optimal catheter tip position within ventricle. EM : electromagnetic.

determined to be grade III in the standard group. This result showed that the EM navigated group can get the high potential to have optimal catheter tip position within ventricle (Fig. 3).

Shunt failure rate and characteristics of failure cases

The Table 2 showed characteristics of shunt failure cases. There were 14 shunt failure cases (31%) in the standard group compared with 3 cases (11%) in the EM group. The most common cause of shunt failure in the standard group was proximal obstruction comparing with no revision case from proximal obstruction in the EM navigated group ($p=0.020$, chi-square test). For distal obstruction, there was higher rate of revision in the standard group (6.7%) than the EM group (3.7%). Similar result of shunt failure rate between 2 groups was revealed with infection. Comparison of distal obstruction and infection showed no

statistically significance (distal obstruction $p=0.879$, infection $p=0.905$).

Shunt failure rate according to catheter position

Fig. 4 shows comparison of failure rate among the grades. In grade I, about 16% of cases received revision surgery, as 46% of grade II. Two shunts were included in grade III and those cases all required shunt revision ($p=0.002$, chi-square test). When compared in terms of proximal catheter position on each group, grade I tended to have lower risk of revision. 2 patients (8%) of grade I and 1 patient (50%) of grade II needed shunt revision on group 1. In group 2, there was growing trend of revision rate according to increase of grade. Revision surgery was performed on 7 patients (21%) of grade I, 5 patients (47%) of grade II and 2 patients (100%) of grade III.

Proximal obstruction was seen in 8 patients in the standard group, especially 100% (two of two patients) in grade III, 15% (2 of 13 patients) in grade II and 5% (3 of 57 patients) in grade I. In the other hand, there was no proximal obstruction in the EM group.

Statistical considerations

This study has several statistical limitations. The number of the samples was too small to represent the population of shunt patients. And it was necessary to consider other factors that might have influenced the results. However, we tried to include patients who had various factors as possible. Other factors were already proven to have no statistical significance except catheter tip position by using multiple regression analysis (age : $p=0.138$, sex : $p=0.430$, cause : $p=0.226$).

The type of shunt could be an important factor to affect the catheter function, but there was insufficient consideration about that point in this study. There has been no specific study to confirm the relationship between shunt types and shunt obstruction up to the present except Tuli et al.²¹⁾ assumed many factors to have effect on shunt failure including valve type and shunt type. They verified that shunt valve itself could not be a predictor of shunt revision using the multivariable model. However, it would be challenging to prove that shunt type is related with catheter obstruction on the basis of valve’s composition. And even if same type of valve was used, shunt valve pressure could make another bias.

DISCUSSION

According to the results of the previous studies, various meth-

ods have been suggested to improve the accuracy of catheter tip position. Pang and Grabb¹⁵⁾ described a method of calculating catheter length based on bony landmarks on skull radiographs and a shunt placement by free-hand passage using simple stereotactic guidance and palpable surface anatomy. Serlo et al.¹⁸⁾ ascertained the catheter position using X-ray imaging by filling the catheter with contrast medium. Neuroendoscopic procedures have also been used effectively^{16,24)}. Kestle et al.¹³⁾ compared the revision rates after endoscopically versus non-endoscopically placed ventricular catheter. Despite placement of catheter tip under direct vision, that study concluded no differences in failure rates between 2 cohorts because burr hole and catheter trajectory were still based on anatomical landmarks^{1,11)}.

Frameless stereotaxy has been shown to be helpful for precise location of catheter tip and avoiding unnecessary injury to brain tissue, leading to prevent repeated shunt revisions in children with slit ventricles^{8,9,18)}. This study has demonstrated that neuronavigation in the placement of ventricular catheters assures optimal catheter position within ventricles, reducing revision rate in not only special cases, but also general shunt surgeries.

VP shunts are still often complicated by malfunction, predominantly with proximal catheter obstruction despite improved surgical equipment and operative skill^{10,14,19,25)}. About 30% to 50% of shunts fail within the first year and only 30% to 37% of shunts survive for 10 years without revision^{3,21,22,25)}. Choroid plexus has generally been considered to be the most frequent cause of ventricular catheter obstruction^{4,12,14,17)}. It is well known that the ideal placement of the proximal catheter tip is the frontal horn away from the choroid plexus^{5,7)}. The obstruction of catheter tip is caused by connective tissue, inflammatory changes, and foreign bodies which are found frequently at the ventricular end. Astrocytes and fibroconnective tissues are especially capable of proliferation. They may fill the side holes in the 15 mm from their tip and the inside of the catheter, leading obstruction of catheters²⁾. Choroid plexus and ependymal cells also have proliferative capability under some conditions. Collins et al.⁶⁾ frequently found choroid plexus in catheter tips placed in behind the foramen of Monro, but ependyma predominated in catheters placed in front of it.

A ventricular catheter tip surrounded by CSF decreased the risk of shunt failure to one-fifth, whereas a catheter tip touching the brain decreased the risk to one-third, compared with a catheter tip surrounded by brain tissue^{21,25)}. The significant relation-

Table 2. The characteristics of the shunt failure cases

Number	Grade of placement	Time to failure (months)	Reason for failure
Standard			
1	1	51	Infection
2	2	2	Catheter injury
3	1	545	Proximal obstruction
4	2	166	Infection
5	2	62	Distal obstruction
6	3	0	Proximal obstruction
7	2	261	Proximal obstruction
8	1	42	Proximal obstruction
9	1	94	Proximal obstruction
10	1	40	Infection
11	2	167	Proximal obstruction
12	1	7	Proximal obstruction
13	1	62	Distal obstruction
14	3	29	Proximal obstruction
EM guided			
1	1	38	Infection
2	1	12	Infection
3	2	34	Distal obstruction

EM : electromagnetic

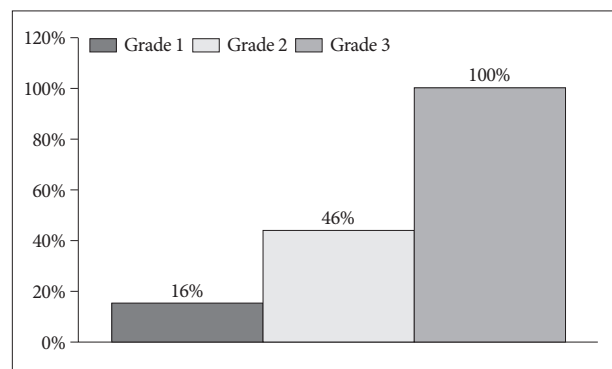


Fig. 4. Comparison of revision rate between grades. All cases in grade 3 required shunt revision surgery.

ship of tip position and shunt failure rate has already reported in our study. There might be several other factors to affect shunt catheter obstruction like type of catheter.

Although it is already demonstrated that endoscopically guided catheter insertion could get intended position of the tip with controversy, image guidance like neuronavigation system may be helpful in determining the entry point and approach trajectory before and during the procedure¹⁷⁾. The EM group of this study has been found more in grade I, representing the close relationship of navigation and catheter position. Therefore, the formula can be established that use of EM navigation lead an ultimate catheter placement, resulting decrease of shunt failure rate.

There are several disadvantages to frameless neuronavigation which include the prolongation of operation time and dependence on expensive technology^{8,23,25)}. More operation time can

have risk to increase intraoperative infection rate. In fact, 5 to 10 minutes can be required to install and to register the navigation by skilled person¹¹). Stieglitz et al.²⁰) described that the additional time needed for preparations did not exceed 15 minutes with their experiences. The DRF can be placed while anesthesia personnel are obtaining intravenous access¹¹). The other problem is that frameless stereotaxy is expensive program. It requires additional imaging to be used for navigation with additional radiation dosage¹¹). It also adds cost to the procedure of neuronavigation and to the use of a navigation stylet. As a practice matter, average 40% of total sum of money was charged to operation fee at our institution with EM navigation shunts. But, revision surgery needs more cost added on the first surgery¹¹). Hayhurst et al.¹¹) measured that cost of a shunt revision was ten times greater than the cost of a using navigation in their own country. Furthermore, the time span between revisions shortens progressively after second revision, indicating that economical disadvantages can be replicated¹⁴). Therefore, the cost-benefit ratio must be carefully established to obviate its need.

CONCLUSION

Mechanical malfunction and infection are the most significant problems associated with shunts for the treatment of hydrocephalus. Above all, a significant proportion of shunt failures were due to obstruction of the ventricular catheter, and accurate placement of the shunt catheter is highly important to reduce the incidence of shunt malfunction.

In conclusion, the use of EM navigated system in routine shunt surgery can eliminate poor shunt placement resulting in a dramatic reduction in shunt revision rates.

References

1. Azeem SS, Oigitano TC : Ventricular catheter placement with a frameless neuronavigational system : a 1-year experience. *Neurosurgery* 60 (4 Suppl 2) : 243-247; discussion 247-248, 2007
2. Bierbrauer KS, Storrs BB, McLone DG, Tomita T, Dauser R : A prospective, randomized study of shunt function and infections as a function of shunt placement. *Pediatr Neurosurg* 16 : 287-291, 1990-1991
3. Browd SR, Ragel BT, Gottfried ON, Kestle JR : Failure of cerebrospinal fluid shunts : part I : Obstruction and mechanical failure. *Pediatr Neurol* 34 : 83-92, 2006
4. Cho TH, Park JY, Lee JK, Park YK, Chung HS, Lee KC, et al. : Radiologic location of ventricular tip and the patency of ventriculoperitoneal shunt. *J Korean Neurosurg Soc* 26 : 513-517, 1997
5. Choudhury AR : Avoidable factors that contribute to the complications of ventriculoperitoneal shunt in childhood hydrocephalus. *Childs Nerv Syst* 6 : 346-349, 1990
6. Collins P, Hockley AD, Woollam DH : Surface ultrastructure of tissues occluding ventricular catheters. *J Neurosurg* 48 : 609-613, 1978
7. Dickerman RD, McConathy WJ, Morgan J, Stevens QE, Jolley JT, Schneider S, et al. : Failure rate of frontal versus parietal approaches for proximal catheter placement in ventriculoperitoneal shunts : revisited. *J Clin Neurosci* 12 : 781-783, 2005
8. Gil Z, Siomin V, Beni-Adani L, Sira B, Constantini S : Ventricular catheter placement in children with hydrocephalus and small ventricles : the use of a frameless neuronavigation system. *Childs Nerv Syst* 18 : 26-29, 2002
9. Haase J : Neuronavigation. *Childs Nerv Syst* 15 : 755-757, 1999
10. Hakim S : Observations on the physiopathology of the CSF pulse and prevention of ventricular catheter obstruction in valve shunts. *Dev Med Child Neurol Suppl* 20 : 42-48, 1969
11. Hayhurst C, Beems T, Jenkinson MD, Byrne P, Clark S, Kandasamy J, et al. : Effect of electromagnetic-navigated shunt placement on failure rates : a prospective multicenter study. *J Neurosurg* 113 : 1273-1278, 2010
12. Kang JK, Lee IW : Long-term follow-up of shunting therapy. *Childs Nerv Syst* 15 : 711-717, 1999
13. Kestle JR, Drake JM, Cochrane DD, Milner R, Walker ML, Abbott R 3rd, et al. : Lack of benefit of endoscopic ventriculoperitoneal shunt insertion : a multicenter randomized trial. *J Neurosurg* 98 : 284-290, 2003
14. Lazareff JA, Peacock W, Holly L, Ver Halen J, Wong A, Olmstead C : Multiple shunt failures : an analysis of relevant factors. *Childs Nerv Syst* 14 : 271-275, 1998
15. Pang D, Grabb PA : Accurate placement of coronal ventricular catheter using stereotactic coordinate-guided free-hand passage. Technical note. *J Neurosurg* 80 : 750-755, 1994
16. Rhoten RL, Luciano MG, Barnett GH : Computer-assisted endoscopy for neurosurgical procedures : technical note. *Neurosurgery* 40 : 632-637; discussion 638, 1997
17. Sekhar LN, Moosy J, Guthkelch AN : Malfunctioning ventriculoperitoneal shunts. Clinical and pathological features. *J Neurosurg* 56 : 411-416, 1982
18. Serlo W, Heikkinen E, Saukkonen AL, von Wendt L : Classification and management of the slit ventricle syndrome. *Childs Nerv Syst* 1 : 194-199, 1985
19. Stein SC, Guo W : Have we made progress in preventing shunt failure? A critical analysis. *J Neurosurg Pediatr* 1 : 40-47, 2008
20. Stieglitz LH, Giordano M, Samii M, Luedemann WO : A new tool for frameless stereotactic placement of ventricular catheters. *Neurosurgery* 67 (3 Suppl Operative) : ons131-ons135; discussion ons135, 2010
21. Tuli S, Drake J, Lawless J, Wigg M, Lamberti-Pasculli M : Risk factors for repeated cerebrospinal shunt failures in pediatric patients with hydrocephalus. *J Neurosurg* 92 : 31-38, 2000
22. Tuli S, O'Hayon B, Drake J, Clarke M, Kestle J : Change in ventricular size and effect of ventricular catheter placement in pediatric patients with shunted hydrocephalus. *Neurosurgery* 45 : 1329-1333; discussion 1333-1335, 1999
23. Tulipan N, Lavin PJ, Copeland M : Stereotactic ventriculoperitoneal shunt for idiopathic intracranial hypertension : technical note. *Neurosurgery* 43 : 175-176; discussion 176-177, 1998
24. Wagner W, Gaab MR, Schroeder HW, Sehl U, Tschiltschke W : Experiences with cranial neuronavigation in pediatric neurosurgery. *Pediatr Neurosurg* 31 : 231-236, 1999
25. Wan KR, Toy JA, Wolfe R, Danks A : Factors affecting the accuracy of ventricular catheter placement. *J Clin Neurosci* 18 : 485-488, 2011