

## 앙와위와 좌측 기울린위치에서의 좌심실의 공간적 관계 변화. 임신부 심폐소생술 측면에서

윤종근<sup>†</sup> · 이병국<sup>\*</sup>

동강대학교 응급구조과, \*전남대학교병원 응급의학과

### Spatial Relationship of the Left Ventricle in the Supine Position and the Left Lateral Tilt Position (Implication for Cardiopulmonary Resuscitation in Pregnant Patients)

Jong Geun Yun<sup>†</sup> · Byung Kook Lee<sup>\*</sup>

Professor, Department of Emergency Medical Technology, Dongkang University

\*Department of Emergency Medicine, Chonnam National University Hospital

(Received September 26, 2013; Revised October 11, 2013; Accepted October 11, 2013)

#### 요 약

임신부의 경우 심폐소생술동안 좌측 기울림을 적용하도록 권장하고 있다. 하지만, 이 좌측으로 기울리면 임신부의 자궁 뿐만이 아니라 좌심실도 좌측으로 편위되어 심폐소생술의 심장펌프기능이 떨어질 가능성이 있다. 이에 좌측 기울림이 심폐소생술동안 흉골 운동 방향을 대변하는 전후축과 좌심실의 공간적 관계에 미치는 영향을 알아보고자 하였다. 컴퓨터 단층촬영을 이용한 가상내시경검사를 받은 90명의 환자를 대상으로 의무기록과 컴퓨터단층촬영결과를 후향적으로 조사하였다. 가상내시경은 앙와위와 좌측 기울림 위치 모두에서 실시되었다. 좌심실 단면적이 가장 넓은 측면에서 전후축과 좌심실축사이의 각도( $\text{Angle}_{\text{AP-LV}}$ ), 전후축과 좌심실 중앙사이 최단거리( $D_{\text{AP-MidLV}}$ ), 및 전후축과 좌심실첨부사이 최단거리( $D_{\text{AP-Apex}}$ )를 측정하였다. 대상환자 중 87명(96.7%)에서는 앙와위에서 좌심실이 전후축의 좌측에 위치하였다. 좌측으로 기울린 영상에서의 기울림 각도는  $43.4 \pm 11.0^\circ$ 였다.  $D_{\text{AP-MidLV}}$ 와  $D_{\text{AP-Apex}}$ 는 좌측 기울린 위치에서 의미있게 길었지만 ( $p < 0.001$ ),  $\text{Angle}_{\text{AP-LV}}$ 는 두 자세 사이에 비슷했다. 심장정지인 임신부에서 좌측으로 기울림은 흉부압박의 심장펌프 효과를 떨어뜨릴 수도 있다.

#### ABSTRACT

Application of the left lateral tilt position has been recommended during cardiopulmonary resuscitation (CPR) of pregnant patients. However, the left lateral tilt could displace the left ventricle (LV) besides the gravid uterus and may compromise the cardiac pump mechanism of CPR. Thus, we investigated the effect of left lateral tilt on the spatial relationship between the anterior-posterior axis (AP axis), which represents the direction of sternal displacement during CPR, and the LV. We retrospectively reviewed the medical records and multidetector computed tomography (MDCT) scans of 90 patients who underwent virtual gastroscopy using MDCT. Virtual gastroscopy was performed with the patient both in the left lateral tilt position and in the supine position. On an axial image showing the maximal area of the LV, the angle between the AP axis and the LV axis ( $\text{Angle}_{\text{AP-LV}}$ ), the shortest distance between the AP axis and the mid-point of LV cavity ( $D_{\text{AP-MidLV}}$ ) and the shortest distance between the AP axis and the LV apex ( $D_{\text{AP-Apex}}$ ) were measured. In the supine scans, the LV was situated on the left side of the AP axis in 87 patients (96.7%). On the left lateral tilt scans, the mean tilt angle was  $43.4 \pm 11.0^\circ$ .  $D_{\text{AP-MidLV}}$  and  $D_{\text{AP-Apex}}$  were significantly longer in the left lateral tilt position ( $p < 0.001$ ), but  $\text{Angle}_{\text{AP-LV}}$  was comparable between the positions. This study indicates that the left lateral tilt position may compromise the cardiac pump mechanism of chest compression in pregnant cardiac arrest patients.

**Keywords :** Heart arrest, Cardiopulmonary resuscitation, Pregnancy, Patient positioning

<sup>†</sup>Corresponding Author, E-Mail: emt-jonggun@hanmail.net  
TEL: +82-62-520-2305, FAX: +82-62-520-2527

ISSN: 1738-7167  
DOI: <http://dx.doi.org/10.7731/KIFSE.2013.27.5.75>

## 1. Introduction

Cardiac arrest in pregnancy is a rare obstetric emergency<sup>(1)</sup>. Although pregnant women are generally younger than typical cardiac arrest patients, the survival rate is worse in pregnant cardiac arrest patients<sup>(2)</sup>. In late pregnancy, the gravid uterus causes vena caval compression in the supine position which may result in decreased venous return and cardiac output<sup>(3)</sup>, and may negatively affect the cardiac output produced by chest compressions. Thus, relief of caval compression during cardiopulmonary resuscitation (CPR) is crucial for survival. The left lateral tilt position has long been used to alleviate caval compression by displacing the gravid uterus laterally. Several studies in non-cardiac arrest pregnant patients indicate that left lateral tilt position improves blood pressure and cardiac output<sup>(4,5)</sup>.

Currently, there are two theories to explain the mechanism of forward blood flow during CPR; the cardiac pump theory and the thoracic pump theory<sup>(6,7)</sup>. Several previous studies have suggested that the cardiac pump, rather than the thoracic pump, is the dominant mechanism in generating forward blood flow during CPR<sup>(7-9)</sup>. According to the cardiac pump theory, compression of the left ventricle (LV) at the level of maximal diameter is required for effective CPR<sup>(7,10)</sup>.

The current CPR guidelines recommend the application of the left lateral tilt position during CPR of pregnant patients, based on previous studies in non-cardiac arrest pregnant patients<sup>(11)</sup>. No study has determined that the left lateral tilt position could maintain cardiac output during CPR similar to that which occurs in the supine position. From the view point of the cardiac pump, the left lateral tilt could displace the LV as well as the gravid uterus, and, thus, may compromise the cardiac pump. To our knowledge, no study has evaluated the effect of left lateral tilt on the position of the LV.

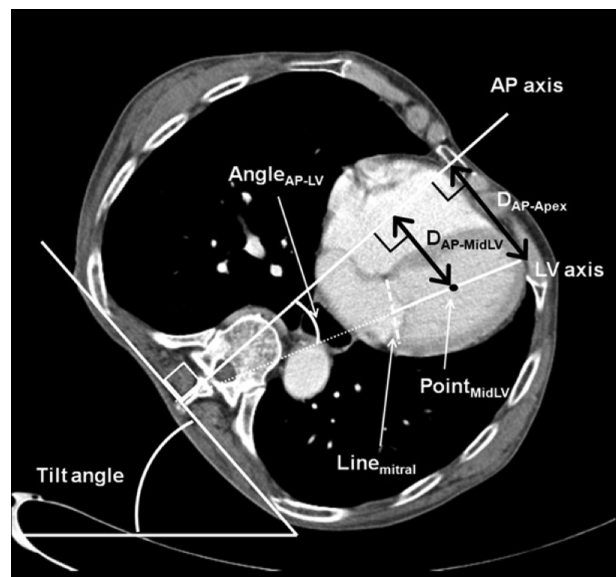
In this study, we sought to investigate the effect of left lateral tilt on the spatial relationship between the anterior-posterior axis (AP axis), which represents the direction of sternal displacement by chest compression, and the LV.

## 2. Methods

This study was approved by the Institutional Review Board of Chonnam National University Hospital (CNUH-2012-067). We retrospectively reviewed the medical records and multidetector computed tomography (MDCT) scans of patients who underwent virtual gastroscopy using MDCT as an evaluation for gastric cancer between January 2008

and December 2011 in our hospital. According to our institutional protocol, virtual gastroscopy was performed first with the patient in the left lateral tilt position by placing a rolled blanket under the right side of trunk to facilitate evaluation of gastric angle and antrum, then with the patient in the supine position. Exclusion criteria were as follows: severe chest deformity such as funnel chest, presence of conditions that could shift mediastinal organs including atelectasis, pleural effusion, large amount of ascites, and space-occupying mass within thoracic cavity and previous thoracoabdominal surgery. We also excluded patients whose CT scan did not cover the LV at the level of maximal area.

Demographic data, height and weight of the patients were obtained from medical records. The CT used in this study was Somatom Sensation Cardiac 64 and SOMATOM Definition Flash (Siemens Medical Solutions, Malvern, USA). The picture archiving and communication system (MAROSIS Maroview, Marotech Inc., Seoul, Korea) was used to analyse the images. We selected an axial image showing the maximal area of the LV in both the supine and left lateral tilt scans, respectively. At the axial image, an



**Figure 1.** Measurement and analysis of computed tomography. Line<sub>Mitral</sub>, an imaginary line between the points of mural attachment of the mitral valve leaflets; LV axis, a line between the mid-point of the Line<sub>Mitral</sub> and the LV apex; Point<sub>MidLV</sub>, a mid-point of the LV axis; AP axis, a line passing through the sternum to represent the direction of sternal displacement during chest compressions; Tilt angle, an angle between the horizontal plane and the tilted plane of thoracic cage; Angle<sub>AP-LV</sub>, the angle between the AP axis and the LV axis; D<sub>AP-MidLV</sub>, shortest distance between the AP axis and the Point<sub>MidLV</sub>; D<sub>AP-Apex</sub>, shortest distance between the AP axis and the LV apex.

imaginary line (Line<sub>Mitral</sub>) was drawn between the points of mural attachment of the mitral valve leaflets (Figure 1). LV axis was defined as a line between the mid-point of the Line<sub>Mitral</sub> and the LV apex. Point<sub>MidLV</sub> was defined as a mid-point of the LV axis.

The AP axis was defined as a line passing through the sternum to represent the direction of sternal displacement during chest compressions, which was perpendicular to the horizontal plane in the supine position or perpendicular to the tilted plane in the left lateral tilt position, respectively. The tilt angle was defined as an angle between the horizontal plane and the tilted plane of the thoracic cage. The relationship between the AP axis and the LV was evaluated in the axial image of supine scans. With these definitions, the following are measured respectively in the supine and the left lateral tilt images: Angle<sub>AP-LV</sub> (angle between the AP axis and the LV axis), D<sub>AP-MidLV</sub> (shortest distance between the AP axis and the Point<sub>MidLV</sub>), D<sub>AP-Apex</sub> (shortest distance between the AP axis and the LV apex). The differences in Angle<sub>AP-LV</sub>, D<sub>AP-MidLV</sub> and D<sub>AP-Apex</sub> between the supine and the left lateral tilt positions were calculated and defined as delta-Angle<sub>AP-LV</sub>, delta-D<sub>AP-MidLV</sub> and delta-D<sub>AP-Apex</sub>, respectively.

Data were analysed using SPSS 15.0 (Chicago, IL, USA). Continuous variables were investigated for normality using the Shapiro-Wilk test. Normally distributed continuous variables were summarised as means and standard deviations (SD). The paired t test was conducted to compare between the two positions. Non-normally distributed continuous variables were summarised as medians with interquartile ranges. Categorical variables were summarised as frequencies and percentages. Pearson’s correlation was used to examine the relationships between the tilt angle and the delta values. Significance was set at p<0.05.

### 3. Results

During the study period, a total of 187 patients underwent virtual gastrography for evaluation of gastric cancer. Among them, we excluded one patient who had a large pleural effusion, 48 patients whose CT scans did not cover the LV at the level of maximal area and 48 patients for whom either supine scans or left lateral tilt scans were not performed. As a result, 90 patients were included in this study. The number of male subjects was 54 (60%), and the mean age was 63.4±11.6 years. The mean weight and the mean height was 62.0 kg (55.0-70.0) and 161.0±8.7 cm, respectively.

In the supine scans, the LV was situated on the left side of AP axis in 87 patients (96.7%). Only 3 patients (3.3%)

**Table 1.** Spatial Relationship between the Left Ventricle and the Antero-posterior Axis Passing through the Sternum

	Supine (n=90)	Left lateral tilt (n=90)	p-Value
Angle <sub>AP-LV</sub> , °	41.0±8.9	40.5±8.5	0.364
D <sub>AP-MidLV</sub> , mm	48.9±7.8	59.7±8.0	<0.001
D <sub>AP-Apex</sub> , mm	76.9±11.4	87.7±11.4	<0.001

Angle<sub>AP-LV</sub>, angle between the AP axis and the LV axis; D<sub>AP-MidLV</sub>, shortest distance between the AP axis and the Point<sub>MidLV</sub>; D<sub>AP-Apex</sub>, shortest distance between the AP axis and the LV apex.

**Table 2.** Correlation between the Tilt Angle and delta-Angle<sub>AP-LV</sub>, delta-D<sub>AP-MidLV</sub> and delta-D<sub>AP-Apex</sub>

		r	p-Value
delta-Angle <sub>AP-LV</sub> , °	-0.52±5.39	-0.016	0.881
delta-D <sub>AP-MidLV</sub> , mm	10.78±5.42	0.041	0.699
delta-D <sub>AP-Apex</sub> , mm	10.87±5.95	0.066	0.534

had at least some of the LV cavity located below the sternum. On the left lateral tilt scans, the mean tilt angle was 43.4±11.0°. The spatial relationship between the LV and the AP axis in both positions is shown in Table 1.

D<sub>AP-MidLV</sub> and D<sub>AP-Apex</sub> were significantly longer in left lateral tilt position (p<0.001), but Angle<sub>AP-LV</sub> was comparable between the positions. The tilt angle did not show a significant correlation with delta-Angle<sub>AP-LV</sub>, delta-D<sub>AP-MidLV</sub> and delta-D<sub>AP-Apex</sub>, respectively (Table 2).

The differences in Angle<sub>AP-LV</sub>, D<sub>AP-MidLV</sub>, and D<sub>AP-Apex</sub> between the supine and the left lateral tilt positions were defined as delta-Angle<sub>AP-LV</sub>, delta-D<sub>AP-MidLV</sub> and delta-D<sub>AP-Apex</sub>, respectively.

### 4. Discussion

In this study, the LV was located more laterally in the left lateral tilt position compared with the supine position. This finding indicates that the left lateral tilt position may compromise the cardiac pump mechanism in pregnant cardiac arrest patients. Thus, the benefit of the left lateral tilt position on maintaining venous return may be offset by its deleterious effects on the cardiac pump mechanism.

Apart from the possible deleterious effects on the cardiac pump mechanism, the left lateral tilt position in pregnant cardiac arrest patients may have several other drawbacks. Tilting a pregnant patient during CPR may require interruption of chest compression and it is well known that interruptions in chest compressions affect resuscitation out-

comes adversely<sup>(12)</sup>. The left lateral tilt may also affect the quality of the chest compressions, because the direction of chest compression forces is not perpendicular to the horizontal plane. In a study by Rees and Willis, which assessed the efficacy of chest compressions with a manikin at various angles of inclination in the left lateral tilt, the chest compression force decreased as the angle of inclination of the plane increased<sup>(13)</sup>. They also reported that the manikin tended to slide off the incline plane at angles above 30°. Several recent studies have indicated that manual left uterine displacement in the supine position is as effective as the left lateral tilt in relieving caval compression<sup>(14,15)</sup>. For these reasons, the present guidelines recommend performing manual left uterine displacement in the supine position before placing the patient in a left lateral tilt position<sup>(11)</sup>. The findings of this study also suggest that the manual leftward displacement of the gravid uterus, rather than the left lateral tilt, should be used as an initial method to relieve caval compression during CPR.

There are several limitations to this study. First, this study could not demonstrate either the haemodynamic effects of left lateral tilt positioning or the effect on resuscitation outcomes. Thus, more studies are needed to validate our findings regarding whether or not the left lateral tilt affects resuscitation outcomes adversely. Second, our study patients were not women in late pregnancy. Late pregnancy, by itself, may affect the spatial relationship of LV. Third, because the CT scans were not taken during CPR, this study did not give realistic information during CPR.

## 5. Conclusions

Despite its limitations, the present study indicates that the left lateral tilt position may compromise cardiac pump mechanism of chest compression in pregnant cardiac arrest patients. Further study is required to reach a decisive conclusion on the clinical effects of left lateral tilt positioning during CPR in pregnant women.

## 6. Conflict of Interest

The authors have no conflict of interest.

## References

1. S. Morris and M. Stacey, "Resuscitation in Pregnancy", *BMJ*, Vol. 327, pp. 1277-1279 (2003).
2. A. Dijkman, C. M. A. Huisman, M. Smit, J. M. Scu-

3. M. G. Kerr, D. B. Scott and E. Samuel, "Studies of the Inferior Vena Cava in Late Pregnancy", *Br. Med. J.*, Vol. 1, pp. 532-533 (1964).
4. C. Mendonca, J. Griffiths, B. Ateleanu and R. E. Collis, "Hypotension Following Combined Spinal-epidural Anaesthesia for Caesarean Section. Left Lateral Position vs. Tilted Supine Position", *Anaesthesia*, Vol. 58, pp. 428-31 (2003).
5. J. H. Bamber and M. Dresner, "Aorticaval Compression in Pregnancy: The Effect of Changing the Degree and Direction of Lateral Tilt on Maternal Cardiac Output", *Anesth Analg*, Vol. 97, pp. 256-258 (2003).
6. H. R. Halperin, J. E. Tsitlik, A. D. Guerci, E. D. Mellits, H. R. Levin, A. Y. Shi, N. Chandra and M. L. Weisfeldt, "Determinants of Blood Flow to Vital Organs During Cardiopulmonary Resuscitation in Dogs", *Circulation*, Vol. 73, pp. 539-550 (1986).
7. G. W. Maier, G. S. Tyson, C. O. Olsen, K. H. Kernstein, J. W. Davis, E. H. Conn, D. C. Sabiston Jr. and J. S. Rankin, "The Physiology of External Cardiac Massage: High-impulse Cardiopulmonary Resuscitation", *Circulation*, Vol. 70, pp. 86-101 (1984).
8. W. Hackl, P. Simon, W. Mauritz and K. Steinbereithner, "Echocardiographic Assessment of Mitral Valve Function During Mechanical Cardiopulmonary Resuscitation in Pigs", *Anesth Analg*, Vol. 70, pp. 350-356 (1990).
9. S. O. Hwang, K. H. Lee, J. H. Cho, J. Yoon and K. H. Choe, "Changes of Aortic Dimensions as Evidence of Cardiac Pump Mechanism During Cardiopulmonary Resuscitation in Humans", *Resuscitation*, Vol. 50, pp. 87-93 (2001).
10. S. O. Hwang, P. G. Zhao, H. J. Choi, K. H. Park, K. C. Cha, S. M. Park, S. C. Kim, H. Kim and K. H. Lee, "Compression of the Left Ventricular Outflow Tract During Cardiopulmonary Resuscitation", *Acad. Emerg. Med.*, Vol. 16, pp. 928-933 (2009).
11. T. L. Vanden Hoek, L. J. Morrison, M. Shuster, M. Donnino, E. Sinz, E. J. Lavonas, F. M. Jeejeebhoy and A. Gabrielli, "Part 12: Cardiac Arrest in Special Situations: 2010 American Heart Association Guidelines for Cardiopulmonary Resuscitation and Emergency Cardiovascular Care", *Circulation*, Vol. 122, pp. S829-S861 (2010).
12. R. A. Berg, A. B. Sanders, K. B. Kern, R. W. Hilwig, J. W. Heidenreich, M. E. Porter and G. A. Ewy, "Adverse Hemodynamic Effects of Interrupting Chest Compressions for Rescue Breathing During Cardiopulmonary Resuscitation for Ventricular Fibrillation Cardiac Arrest", *Circulation*, Vol. 104, pp. 2465-2470 (2001).
13. G. A. Rees and B. A. Willis, "Resuscitation in Late Preg-

- nancy”, *Anaesthesia*, Vol. 43, pp. 347-349 (1988).
14. P. Kundra, S. Khanna, S. Habeebullah and M. Ravishankar, “Manual Displacement of the Uterus During Caesarean Section”, *Anaesthesia*, Vol. 62, pp. 460-465 (2007).
15. A. Amaro, E. Capelli, M. Cardoso, M. Rosa and J. Carvalho, “Manual Left Uterine Displacement or Modified Crawford’s Edge: A Comparative Study in Spinal Anesthesia for Cesarean Delivery”, *Rev. Bras. Anest.*, Vol. 48, pp. 99-104 (1998).