

## RESEARCH ARTICLE

# An Australian Retrospective Study to Evaluate the Prognostic Role of p53 and eIF4E Cancer Markers in Patients with Head and Neck Squamous Cell Carcinoma (HNSCC): Study Protocol

Jagtar Singh<sup>1</sup>, Rama Jayaraj<sup>1\*</sup>, Siddhartha Baxi<sup>2</sup>, Mariana Mileva<sup>3</sup>, Justin Curtin<sup>4</sup>, Mahiban Thomas<sup>4</sup>

### Abstract

Complete surgical resection of the primary tumour is a crucial predictive step for head and neck squamous cell carcinoma (HNSCC), because incomplete resection may lead to increase in the recurrence rate. Molecular cancer markers have been investigated as potential predictors of prognosis marker, to identify patients who are at high risk of local recurrence. This retrospective study aimed to determine the prognostic correlation between p53 and eIF4E expression and clinical characteristics, recurrence and overall survival. Forty eight HNSCC patients were selected between 2006 and 2009 diagnosed at the Royal Darwin Hospital, Darwin, Northern Territory, Australia. Out of 48, only those 24 with negative surgical margins with hematoxylin and eosin (HandE) were chosen for further analysis. A total of 77 surgical margins were obtained and subsequently analysed by immunohistochemical (IHC) staining with monoclonal p53 and polyclonal eIF4E antibodies. Contingency table and  $\chi^2$ -test were used to investigate the correlation between p53 and eIF4E expression and clinical characteristics, recurrence and overall survival of the HNSCC patients. The follow up period was 74 months (range 1-74 months). The Kaplan-Meier method was used to generate recurrence and survival curves. This is a first retrospective study of Northern Territory patients, including Indigenous and non-Indigenous Australians. Molecular study of surgical margins could help to identify patients with and without clear margins after surgery and help in choice of the most appropriate adjuvant treatment for HNSCC patients.

**Keywords:** Head and neck squamous cell carcinoma - p53 - eIF4E - immunohistochemistry - recurrence - survival

*Asian Pac J Cancer Prev*, 14 (8), 4717-4721

### Introduction

Head and neck cancer squamous cell carcinoma (HNSCC) is a term given to epithelial malignancies that arise in the oral cavity, paranasal sinuses, nasal cavity, pharynx, and larynx (Argiris et al., 2008; Rudolph et al., 2011). Almost 90% of HNSCC originating from the mucosal lining of these regions (Dobrossy, 2005). HNSCC is strongly associated with certain environmental and lifestyle risk factors including tobacco smoking and high alcohol consumption (Dobrossy, 2005). The successful treatment of these patients depends on early detection and appropriate therapy (Rezende et al., 2010). The incomplete resection of primary tumour frequently leads to decrease in the survival rate as a consequence of increased risk of recurrence; therefore, complete surgical resection of the tumour is a crucial prognostic step for HNSCC (Armstrong et al., 2010; Jalali et al., 2011).

Molecular markers can be used to establish tumour free surgical margins and assist in complete resection of

the tumour (Nathan et al., 1999). To establish the reliable molecular cancer markers, the marker should be specific for tumour cells that could differentiate normal and tumour cells (Roncella et al., 2005). Potential biomarkers have greatly expanded our understanding of molecular pathways involved in tumour initiation and tumour progression (Pai and Westra, 2009). The ability to detect malignancy at the molecular level with appropriate tumour markers could help to prevent the high local recurrence rate by allowing for a more precise determination of cancer involvement at the surgical margins. This would also help in predicting recurrence and possibly lead to adjunctive therapies for patients at higher risk for recurrence (Nathan et al., 1997). Molecular examination of surgical margins could be better therapeutic method over histopathology to identify patients with high risk of local recurrence and tumour related deaths.

The p53 is one the most frequently studied molecular markers in HNSCC (Van Houten et al., 2002; Waitzberg et al., 2004; Poeta et al., 2007; Jalali et al., 2011). It is

<sup>1</sup>School of Psychological and Clinical Sciences, Charles Darwin University, <sup>2</sup>Alan Walker Cancer Care Centre, <sup>3</sup>Anatomical Pathology, <sup>4</sup>Department of Head and Neck Surgery, Royal Darwin Hospital, Darwin, Northern Territory, Australia \*For correspondence: Rama.Jayaraj@cdu.edu.au

the p53 that plays a significant role in pathways that are responsible for maintaining cellular integrity (Bradford et al., 2013). The p53 network is activated when cells are damaged or stressed. In the activation form, the p53 protein can lead to cell cycle arrest and DNA repair, or it can cause programmed cell death (van Oijen and Slootweg, 2000). Alteration in p53 protein function may result from either mutation in its gene or sequestration by the other cellular protein (Gasco and Crook, 2003). Mutations of p53 gene are one of the common genetic abnormalities in many cancers including HNSCC (Hardisson, 2003; Jalali et al., 2011). The mutation of p53 genes leads to the pathogenesis of HNSCC patients with expression range of p53 protein from 50 to 60% of the tumour cells (Nathan et al., 2000; Bradford et al., 2013). The significant function of p53 expression has been widely analysed by IHC methods to identify the number of cancers, including breast cancer. However, the role of p53 protein in HNSCC is incompletely understood (Song et al., 2006). IHC analysis of p53 network may be diagnostic and prognostic use in the clinical management of HNSCC (Gasco and Crook, 2003).

Eukaryotic translation factor 4E (eIF4E) is protein involved in the initiation of protein synthesis (Chen et al., 2004). However, overexpression of eIF4E not only induces the transformation and tumorigenesis, but also initiates metastasis (De Benedetti and Graff, 2004). Overexpression of eIF4E is sufficient to develop the transformation of fibroblasts and primary epithelial cells (Avdulov et al., 2004). In a clinical trial, eIF4E overexpression indicates to increase cancer susceptibility because eIF4E transgenic mice develop lymphomas, angiosarcomas, lung carcinomas, and hepatomas (Ruggero et al., 2004). Previous studies have been observed 100% expression of eIF4E in HNSCC (Cardesa and Nadal, 2011; Nathan et al., 1997). One study has reported that eIF4E overexpression found in cancer tissue than the normal mucosa by using IHC (Rosenwald et al., 2001). Association between p53 and eIF4E expression and clinical outcomes

A previous study suggests that IHC staining with p53 has an advantage over histopathology to identify the patients at high risk for local recurrence (Van Houten et al., 2004). This finding indicate some limitations of histological diagnosis and the potential for molecular markers to guide clinicians in the management of HNSCC (Nathan et al., 2000). It has been highlighted that the overexpression of p53 is often associated with clinicopathological findings of the tumour, lymph node metastases, and survival of HNSCC patients (Waitzberg et al., 2004).

The 5-year survival rate for HNSCC remains low after diagnosis, that is approximately 50% (Jemal et al., 2008; Kokko et al., 2011). Significantly, five year survival rate in HNSCC is lower than other cancers, such as those of colorectal, cervix, and breast origin, due to detection of advanced stage disease (Jemal et al., 2008; Clark et al., 2010). With advent of new surgical procedures, improved radiotherapy and concomitant chemotherapy, there is a considerable improvement in local recurrence (Van Houten et al., 2004). However, the survival rates for

HNSCC have not significantly improved (Partridge et al., 2007; Argiris et al., 2008). It is generally believed that incomplete resection of the primary tumour is the principal reason of death from HNSCC type of cancer (Armstrong et al., 2010). A previous study of p53 observed that the survival rate was higher with p53 negative patients than p53 positive (Jalali et al., 2011).

In retrospective studies of breast, bladder, and HNSCC, the overexpression of eIF4E protein was correlated with an increased risk of disease progression and poor prognosis (Crew et al., 2000; De Benedetti and Graff, 2004; Liangping, 2005). Elevated level of eIF4E in tumour free surgical margins was correlated with local regional recurrence in patients with HNSCC (Chakraborty et al., 2008). A previous study on lung cancer indicated that the patients with high eIF4E expression showed poor survival after surgery than patients with low eIF4E expression (Wang et al., 2009). The study of breast cancer patients observed that the patients with high expression of eIF4E had significantly higher rate of recurrence and cancer related death (Holm et al., 2008). The above studies on lung and breast cancer found that the expression of eIF4E can be considered as an independent prognostic predictor for recurrence and survival.

### *Hypothesis*

The p53 and eIF4E have been used to detect the sub-optical tumours including HNSCC. Clinical pathologists use light microscopy to investigate correlation between recurrent/residual cancer and overexpression of these molecular markers in optically negative margins of HNSCC resection. The absence of p53 and eIF4E overexpression may benefit the patient in terms of avoiding unnecessary treatment, decrease local recurrence and increase survival. This will also help decrease the incidence of residual disease, perhaps downstage the need for radiation therapy, and certainly aid in the reduction of disease-specific mortality in head and neck cancers.

### *Objectives*

i) To determine the correlation between p53 and eIF4E expression in the surgical margin and clinical outcomes; ii) To determine the correlation between expression of p53 and eIF4E in positive surgical tumour margins and clinical characteristics; iii) To investigate whether eIF4E is a more sensitive molecular marker than p53 in surgical margins to predict successful outcomes from surgical treatment, and prevention of recurrence of cancer.

## **Materials and Methods**

### *Design of study*

This retrospective study was performed on the paraffin embedded tissue sections of patients who underwent primary surgical resection for HNSCC. Primarily, we have selected 48 HNSCC patients between 2006 and 2009. They were diagnosed at the Royal Darwin Hospital. The study design is illustrated in Figure 1. Paraffin embedded samples from histologically tumour free surgical margins of HNSCC patients were examined. The expressions of p53 and eIF4E protein were evaluated with IHC method

by using p53 and eIF4E antibodies.

The patient's clinical characteristics including demographic and pathological characteristics were collected for this study (Table 1). Then, relationship between expression of p53 and eIF4E and clinical characteristics were analysed (Figure 2). The primary endpoint is local recurrence and secondary endpoint is overall survival of 24 HNSCC patients.

#### Patients selection and eligibility criteria

##### Target population and level of involvement

There was no patient involvement in the project. Tissue samples from the patients diagnosed and treated for mucosal oro-pharyngeal HNSCC (excluding superficially excised skin malignancies) from March 2005 to December 2009 at Royal Darwin Hospital.

##### Inclusion criteria

Out of 48, 24 patients were included in our study with histologically tumour free surgical margins. Experienced pathologists were examined the surgical margins of 48 HNSCC patients.

##### Exclusion criteria

The remaining twenty four patients were excluded because they had histologically positive surgical margins.

##### Follow-up

The follow up period for 24 HNSCC patients was 74 months (range 1-74 months). We have reviewed the effect of recurrence with p53 and eIF4E expression in the 24 HNSCC patients. Out of 24 patients, 7 patients had local recurrence and 12 patients died during the follow-up period.

##### Immunohistochemical staining

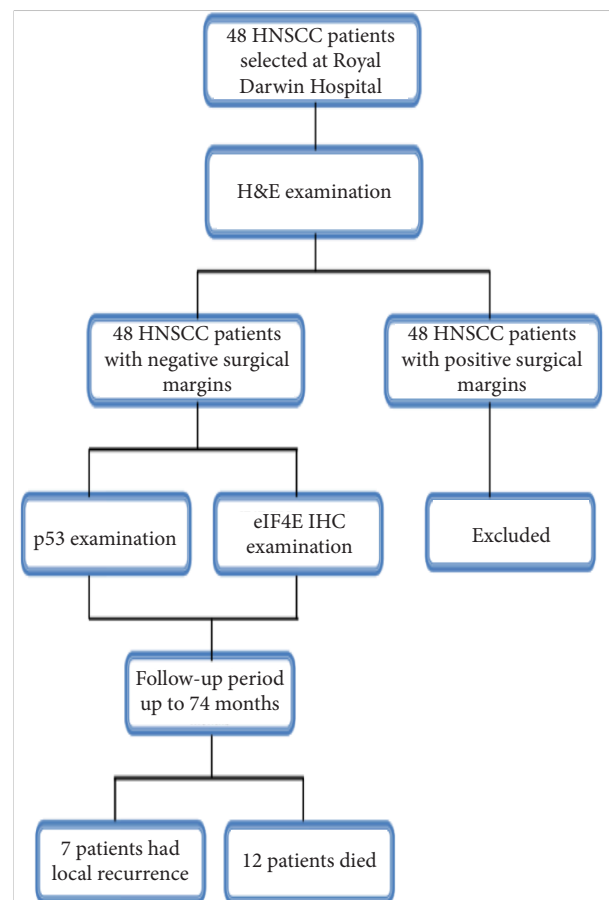
All slides with tissue section were labelled with an appropriate bar code before the IHC staining procedure. These labelled slides were placed horizontally by metal clip on the level carousel in the temperature-equilibrated chamber of Ventana Benchmark XT machine (Ventana Pty Ltd). The Ventana Benchmark XT machine commenced processing the tissue samples upon loading of the programmed p53 and eIF4E IHC procedure file. Each procedure file consisted of a specific sequence of buffer rinse, enzyme inhibitors, blocking serum, antibody detection complexes, chromogens, and counter-stains, which were used according to the manufacturer's instructions.

After a series of buffer rinses and normal serum pre-incubation, antibodies (monoclonal mouse p53 antibody (Dako Pty Ltd, Australia) at 1:200 and polyclonal eIF4E (Abcam Pty Ltd, USA) antibody at 1:500 dilutions) were dispensed using 100 $\mu$ l metered dose per slide. The slides were treated with streptavidin-enzymes conjugated and a brown staining with diaminobenzidine (DAB) (Dako Pty Ltd, Australia) with copper sulphate enhancement. Each staining step was incubated for exact time and at 42°C standard temperature. After the incubation, the instruments in each section were rinsed to halt the reaction and remove

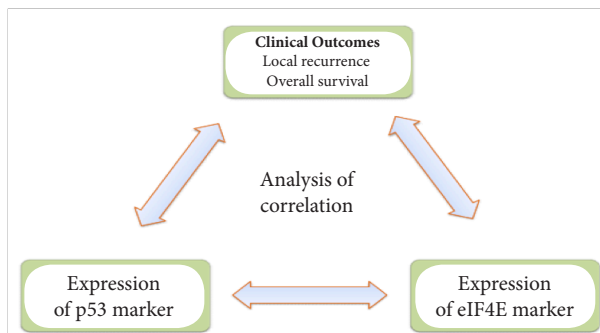
**Table 1. Patient's Clinical Characteristics**

Clinical characteristics	Category
Age	$\geq 50$ $\leq 50$
Sex	Male Female
Race	Indigenous non-Indigenous
Anatomical sites	Floor of mouth Tongue Lips Tonsil
Tumour stage*	T1 T2 T3 T4
Nodal status	Positive Negative
Nodal stage**	N0 N1 N2b
Post-op XRT***	No Yes
Histological grade	Poorly differentiated Moderate differentiated Well differentiated

\*Tumour stage I (T1)=Tumour 2 cm or less, Tumour stage II (T2)=Tumour larger than 2 cm but not larger than 4 cm, Tumour stage III (T3)=Tumour larger than 4 cm, Tumour stage IV (T4)=Tumour with extension to bone, muscle, skin, antrum, neck, \*\*Nodal stage 0 (N0)=No regional lymph node involvement, Nodal stage 1 (N1)=involvement of regional lymph node smaller than 3 cm, Nodal stage 2b (N2b)=involvement of multiple regional lymph nodes smaller than 6 cm, \*\*\*Post-op XRT=post operative irradiation therapy



**Figure 1. The Study Schema of the p53 and eIF4E Molecular Study**



**Figure 2. The Relationship between Expression of p53 and eIF4E and Clinical Outcomes**

the unbounded material that could cause unnecessary background staining.

At the end of automated staining process, the slides were washed in hot water with detergent for 3 minutes to remove the oily material. Then slides were dehydrated through the series of ethanol dilutions and then followed by treatment in xylene. Finally, the cover slips were placed on each slide and fixed with permanent mounting material.

#### *Microscopic examination of p53 and eIF4E expression*

All the IHC stained slides were evaluated for the expression of p53 and eIF4E protein by light microscopy 'in blinded manner' by two pathologists who were unaware of the clinical details. The stained slides of tumour margins were evaluated for p53 and eIF4E protein expression. The 5% cut-off value was selected on the basis of p53 and eIF4E expression in tumour cells in the basal cell layer of surgical margin (Nathan et al., 2000). Therefore, surgical margins were considered as a positive if IHC staining observed in >5% of the cells in epithelial layer.

These tumour margins were graded as positive with p53 if there is brown nuclear staining in the basal cell layer of epithelium. Similarly, surgical margins were considered as positive with eIF4E if there is reddish brown peri-nuclear cytoplasmic staining of >5% in the layer of epithelium.

## Results

The clinical characteristics of 24 HNSCC patients and surgical margins were examined statistically with SPSS software (SPSS Version 19) for this research. Time to recurrence was considered as the period from surgery to the date of the first documented recurrence (Nathan et al., 2000). Local recurrence was defined as a recurrence in the original tumour bed (Chao et al., 2012). The overall survival time was defined as the interval between the dates of the beginning of the treatment (surgery) and the death or the last information for censored observations (Waitzberg et al., 2004).

The records of 24 HNSCC patient's status were obtained from the Royal Darwin Hospital and the Department of Births, Deaths and Marriages, Darwin, Australia. Those records were reviewed for patient's survival. In our study, we have compared the effect of survival rate with the expression of p53 and eIF4E in the

surgical margins.

Contingency Tables and  $\chi^2$ -test were used to evaluate the association of p53 and eIF4E in the surgical margins with age, sex, race, anatomical sites, tumour stage, nodal status, nodal stage, post-operative therapy and histological grade. Univariate analysis was performed to identify significant involvement of the above variables with cancer prognosis. Event time distribution for recurrence and survival rate were estimated by the Kaplan-Meier method and compared by the log-rank test (Nathan et al., 2000; Song et al., 2006).

#### *Outcomes and significance*

The translation of the proposed research study in the clinical setting will have a direct impact on Australian Indigenous community health and health services in the Northern Territory. While the target population of our research study primarily comprises of Australian Indigenous patients, the outcomes of this project will impact on cancer care for all such patients in the Northern Territory.

The use of molecular markers to identify the clear surgical margins may decrease local recurrence of HNSCC. Determining the correlation between biomarkers and clinical outcomes will allow for better patient care planning in the future.

The use of these p53 and eIF4E detection may become routine practice protocols in our clinical pathology setting, dictated by the study findings.

#### *Clinical implications of this study*

If our null hypothesis concerning immunohistochemical (p53 or eIF4E) margins being positive in a setting where routine histology reports a tumour free margin is confirmed, the clinical implications in the clinical setting will be: *i)* Routine usage of p53 and eIF4E in the primary assessment of surgical margins for all HNSCC tumours resected; *ii)* Additional therapy, either as more resection and/or radiation therapy to ensure that the primary ablation is complete; *iii)* Improved outcomes, with reduced recurrence and/or residual disease and potential metastatic disease; increased disease free survival after treatment for HNSCC in the Northern Territory; *iv)* Reduced overall costs to the patient, family, community and health services.

## Discussion

This study will significantly contribute to the field of head and neck oncology. It will also help to improve the service delivery for surgeon and raise awareness of the incidence of HNSCC in the Northern Territory population. Findings from this study will highlight the rate of complications in the management of head and neck oncology in the Northern Territory and this will allow comparison with other centres.

Molecular study of the surgical margin could help to identify patients with and without clear margins after surgery. It also helps to choose the appropriate adjuvant treatment for HNSCC patients. The role of p53 and eIF4E marker expression in the future management of HNSCC is significant. It appears logical and feasible that rapid testing

will inform the surgical team if their resection is adequate, and permit further guide excision at directed margins.

## References

- Argiris A, Karamouzis MV, Raben D, et al (2008). Head and neck cancer. *The Lancet*, **371**, 1695-709.
- Armstrong W, Vokes DE, Maisei RH (2010). Malignant tumors of the larynx, Cummings otolaryngology head and neck surgery, 5<sup>th</sup> edn, America: Mosby Elsevier.
- Avdulov S, Li S, Michalek V (2004). Activation of translation complex eIF4F is essential for the genesis and maintenance of the malignant phenotype in human mammary epithelial cells. *Cancer Cell*, **5**, 553-63.
- Bradford CR, Kumar B, Bellile E, et al (2013). Biomarkers in advanced larynx cancer: triological society thesis. *Laryngoscope*, [Epub ahead of print].
- Cardesa A, Nadal A (2011). Carcinoma of the head and neck in the HPV era. *Acta Dermatoven APA*, **20**, 161-73.
- Chakraborty S, Mohiyuddin SM, Gopinath KS, et al (2008). Involvement of TSC genes and differential expression of other members of the mTOR signaling pathway in oral squamous cell carcinoma. *BMC Cancer*, **8**, 163.
- Chao YK, Chuang WY, Yeh CJ, et al (2012). High phosphorylated 4E-binding protein 1 expression after chemoradiotherapy is a predictor for locoregional recurrence and worse survival in esophageal squamous cell carcinoma patients. *J Surg Oncol*, **105**, 288-92.
- Chen CN, Hsieh FJ, Cheng YM, et al (2004). Expression of eukaryotic initiation factor 4E in gastric adenocarcinoma and its association with clinical outcome. *J Surg Oncol*, **86**, 22-7.
- Clark C, Shah S, Herman-Ferdinand L, et al (2010). Teasing out the best molecular marker in the AKT/mTOR pathway in head and neck squamous cell cancer patients. *Laryngoscope*, **120**, 1159-65.
- Crew JP, Fuggle S, Bicknell R, et al (2000). Eukaryotic initiation factor-4E in superficial and muscle invasive bladder cancer and its correlation with vascular endothelial growth factor expression and tumour progression. *Br J Cancer*, **82**, 161-6.
- De Benedetti A, Graff JR (2004). eIF-4E expression and its role in malignancies and metastases. *Oncogene*, **23**, 3189-99.
- Dobrossy L (2005). Epidemiology of head and neck cancer: magnitude of the problem. *Cancer and Met Rev*, **24**, 9-17.
- Gasco M, Crook T (2003). The p53 network in head and neck cancer. *Oral Oncol*, **39**, 222-31.
- Hardisson D (2003). Molecular pathogenesis of head and neck squamous cell carcinoma. *Eur Arch Otorhinolaryngol*, **260**, 502-8.
- Holm N, Byrnes K, Johnson L, et al (2008). A prospective trial on initiation factor 4E (eIF4E) overexpression and cancer recurrence in node-negative breast cancer. *Ann Surg Oncol*, **15**, 3207-15.
- Jalali MM, Heidarzadeh A, Zavarei MJ, et al (2011). p53 overexpression impacts on the prognosis of laryngeal squamous cell carcinomas. *Asian Pac J Cancer Prev*, **12**, 1731-4.
- Jemal A, Siegel R, Ward E (2008). Cancer statistics. *Cancer J Clin*, **58**, 71-96.
- Kokko LL, Hurme S, Maula SM, et al (2011). Significance of site-specific prognosis of cancer stem cell marker CD44 in head and neck squamous-cell carcinoma. *Oral oncol*, **47**, 510-6.
- Liangping X (2005). The prognostic value of pathological and molecular margins marked by p53 and eIF4E in laryngeal carcinoma. *Chinese-German J Clin Oncol*, **4**, 56-60.
- Nathan CAO, Franklin S, Abreo FW, et al (1999). Analysis of surgical margins with the molecular marker eIF4E: a prognostic factor in patients with head and neck cancer. *J Clin Oncol*, **17**, 2909.
- Nathan CAO, Liu L, Li B (1997). Detection of the proto-oncogene eIF4E in surgical margins may predict recurrence in head and neck cancer. *Oncogene*, **15**, 579-84.
- Nathan CAO, Sanders K, Abreo FW, et al (2000). Correlation of p53 and the proto-oncogene eIF4E in larynx cancers: prognostic implications. *Cancer Res*, **60**, 3599.
- Pai SI, Westra WH (2009). Molecular pathology of head and neck cancer: implications for diagnosis, prognosis, and treatment. *Annu Rev Pathol*, **4**, 49-70.
- Partridge M, Costea DE, Huang X (2007). The changing face of p53 in head and neck cancer. *Int J Oral Maxillofac Surg*, **36**, 1123-38.
- Poeta ML, Manola J, Goldwasser MA, et al (2007). TP53 mutations and survival in squamous-cell carcinoma of the head and neck. *New Eng J Med*, **357**, 2552-61.
- Rezende TM, de Souza Freire M, Franco OL (2010). Head and neck cancer: proteomic advances and biomarker achievements. *Cancer*, **116**, 4914-25.
- Roncella S, Ferro P, Bacigalupo B, et al (2005). Human mammaglobin mRNA is a reliable molecular marker for detecting occult breast cancer cells in peripheral blood. *J Exp Clin Cancer Res*, **24**, 265-71.
- Rosenwald IB, Hutzler MJ, Wang S, et al (2001). Expression of eukaryotic translation initiation factors 4E and 2alpha is increased frequently in bronchioloalveolar but not in squamous cell carcinomas of the lung. *Cancer*, **92**, 2164-71.
- Rudolph E, Dyckhoff G, Becher H, et al (2011). Effects of tumour stage, comorbidity and therapy on survival of laryngeal cancer patients: a systematic review and a meta-analysis. *Eur Archives Oto-Rhino-Laryngology*, **268**, 165-79.
- Ruggero D, Montanaro L, Ma L (2004). The translation factor eIF-4E promotes tumor formation and cooperates with c-Myc in lymphomagenesis. *Nat Med*, **10**, 484-6.
- Song HS, Do YR, Kang SH, et al (2006). Prognostic significance of immunohistochemical expression of p53 gene product in operable breast cancer. *Cancer Res Treat*, **38**, 218-23.
- Van Houten VMM, Leemans CR, Kummer JA, et al (2004). Molecular diagnosis of surgical margins and local recurrence in head and neck cancer patients. *Clin Cancer Res*, **10**, 3614-20.
- Van Houten VMM, Tabor MP, van den Brekel MW, et al (2002). Mutated p53 as a molecular marker for the diagnosis of head and neck cancer. *J Pathol*, **198**, 476-86.
- Van Oijen MG, Slootweg PJ (2000). Gain-of-function mutations in the tumor suppressor gene p53. *Clin Cancer Res*, **6**, 2138-45.
- Waitzberg AF, Nonogaki S, Nishimoto IN, et al (2004). Clinical significance of c-myc and p53 expression in head and neck squamous cell carcinomas. *Cancer Detect Prev*, **28**, 178-86.
- Wang R, Geng J, Wang J, et al (2009). Overexpression of eukaryotic initiation factor 4E (eIF4E) and its clinical significance in lung adenocarcinoma. *Lung Cancer*, **66**, 237-44.