

## Diagnosis and Treatment of Feline Inflammatory Polyp with Video Otoscopy : A Case Report

Se-Jin Park\*, Seung-Yong Lee\*, Young-Ki Kim\*\*\*, Seong-Hoon Seok\*, Jae-Min Hwang\*,  
Dong-Hyuk Jeong\*, Hee-Chun Lee\*\* and Seong-Chan Yeon\*<sup>1</sup>

\*Laboratory of Veterinary Surgery and Behavior, College of Veterinary Medicine,  
Gyeongsang National University, Jinju 660-701, Korea

\*\*Laboratory of Veterinary Medical Imaging, College of Veterinary Medicine, Gyeongsang National University, Jinju 660-701, Korea

\*\*\*Haeundae Animal Medical Center, Busan 612-842, Korea

(Accepted: August 6, 2013)

**Abstract :** Otic mass removal was performed in a 19-month-old, castrated domestic shorthair cat. The patient had 1-year history of recurrent otitis externa, and then otic mass in the right ear canal was found. Under general anesthesia, 2.7 mm rigid endoscope was inserted to the right ear canal with the irrigation system. The ovoid-shaped, 4.9 mm in diameter red otic mass located in the right ear canal was removed via traction-avulsion. Then, rupture of the tympanic membrane was revealed and otic flushing was performed with sterile isotonic (0.9%) saline to remove exudates. Histologically, the removed polyp was diagnosed as granulation tissue with severe ulceration. The patient didn't reveal any remarkable abnormality after surgery, and no recurrence were found after 5 months follow up. The video otoscopy seems to offer a useful option for treatment of a feline inflammatory polyp.

**Key words :** cat, feline inflammatory polyp, video otoscopy, otic flushing.

### Introduction

Feline inflammatory polyps are non-neoplastic masses that originating from the mucosa of either the tympanic bulla or the auditory tube (1,11). Polyps can either extend into the pharynx and nasopharynx via auditory tube or the external ear canal via tympanic membrane (5,6,8). The cause of feline inflammatory polyps is unknown (1,6,9,13,17). It has been usually found in young cats (1-3,15), but occurs rarely (3), and not associated with breed or sex differences (10,15). Previous study reported that affected animals could show clinical signs of stertorous respiration, nasal discharge, sneezing, dyspnea, otorrhea, head tilt, nystagmus and ataxia (14). And inflammatory polyps typically tend to involve secondary bacterial otitis media (8). Inflammatory polyps present in the tympanic bulla may be both consequence and predisposition of otitis media, due to an obstruction of an auditory tube with the accumulated fluid and debris in the bulla (10). Furthermore, otitis media could occur in patients with ruptured tympanic membrane (4). The influence of middle ear may cause Horner's syndrome or facial nerve paralysis, while neurologic abnormalities including head tilt, ataxia and nystagmus have been known as a result of inner ear disorders (5,10,12,17).

Anderson *et al* (1) reported that patients with mild clinical signs disclosed better prognosis in comparison with more severe patients. There are several methods for treatment of feline inflammatory polyps have been announced, but surgical removal of the polyps was typically revealed good prognosis (1,2). Surgical techniques noted for the treatment of feline inflammatory polyps including traction-avulsion, ventral bulla osteotomy, myringotomy, lateral ear resection, ear canal ablation combined with lateral bulla osteotomy, and in a limited role, laser debulking and sterilization of the middle ear (13). Operator can choose one or more surgical technique according to the location of a polyp, presence or absence of radiologic finding, and surgeon's preference as well (13).

In general, not only for feline inflammatory polyps, otoscopic examination is a common method for diagnosis of ear disease in small animal practice. Recently, video otoscopy have been introduced, it is possible to get an improved examination of the ear canal and tympanic membrane better than hand-held otoscopy. Video otoscopy allows veterinarians to magnify image of external and middle ear with detailed resolution, as well as project it on a monitor (4,8,16). In this case report, we described diagnosis and treatment of a feline inflammatory polyp under video otoscopy.

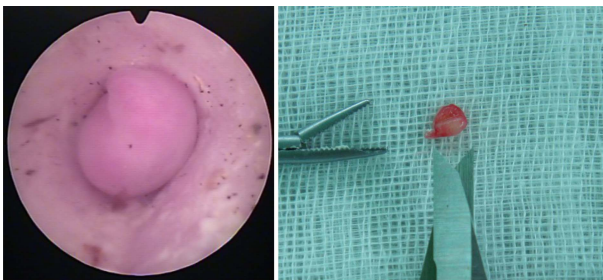
### Case

A 19-month-old, 5 kg, castrated male domestic shorthair

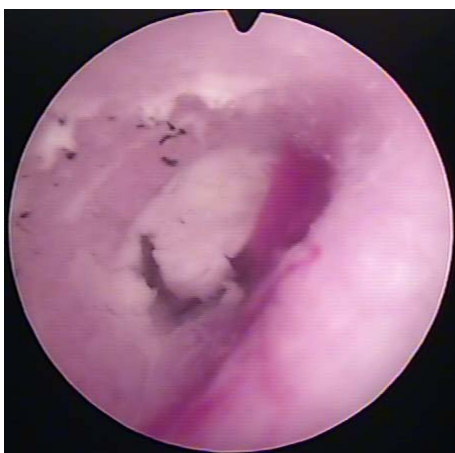
<sup>1</sup>Corresponding author.  
E-mail : scyeon@gnu.ac.kr

cat was referred to the Gyeongsang National University Animal Medical Center for removal of mass in the right ear canal. The patient had 1-year history of recurrent otitis externa with scratching, rubbing the ear, and head shaking. There were no notable improvements presented during few months of typical treatment at the local animal hospital, and then otic mass in the right ear canal has been found by hand-held otoscopy lately. On the physical examination, the patient was in good body condition and couldn't identify any sign of respiratory or neurologic disorder. The results of complete blood count and serum biochemistry were unremarkable. Because of the owner's strong request for less invasive treatment, traction-avulsion of mass with video otoscopy was selected instead of other surgical methods.

The cat was placed in left lateral recumbency under general anesthesia after standard preanesthetic medication. Video otoscopy was then performed using 2.7 mm rigid endoscope (Panoview telescope 8672.422, Richard Wolf GmbH, Germany) with 30° viewing angled which was encased in the arthroscopy sheath. We used irrigation system (Fluid Control 2203, Richard Wolf GmbH, Germany) at the time, because it is necessary to cleaning the ear canal for best visualization. There was no stenosis in right ear canal, and the ovoid-

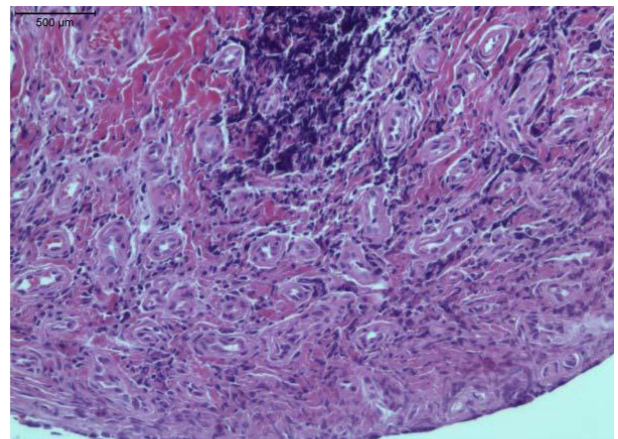


**Fig 1.** The ovoid-shaped, 4.9 mm in diameter red otic mass located in the right ear canal was found via video otoscopy and removed through traction-avulsion.

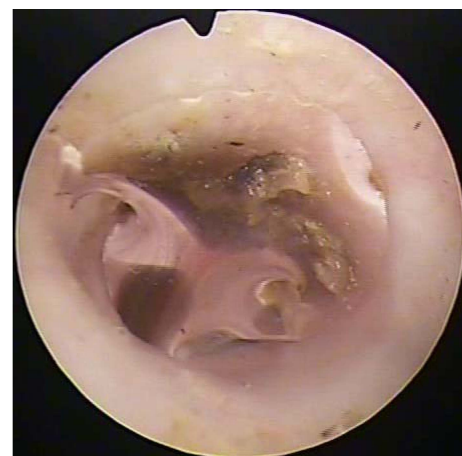

**Fig 2.** After traction-avulsion of otic mass, mild bleeding and soft waxy exudates inside middle ear were occupied in video otoscopic view.

shaped, 4.9 mm in diameter red otic mass was occupied (Fig 1). The mass was removed via traction-avulsion with alligator forceps gently. When finished, only mild bleeding was occurred. Then, ruptured tympanic membrane and soft waxy exudates inside middle ear were found in video otoscopic view (Fig 2). Using a small-diameter curette, the soft waxy exudates were removed carefully not to inflict unnecessary tissue damage. Video otoscopic examination was ended by otic flushing with a large amount of warm sterile isotonic (0.9%) saline. The patient discharged on that day and prescribed to give a daily PO administration of 5 mg/kg enrofloxacin (Baytril®, Bayer Korea Ltd, Korea) for 4 weeks. Tissue sample submitted to the commercial pathology laboratory (Neodin Vetlab, Korea). Histologically, polyp diagnosed as granulation tissue with severe diffuse ulceration of mucosal epithelium including large numbers of degenerative neutro-



**Fig 3.** Histologically, polyp diagnosed as granulation tissue with severe diffuse ulceration of mucosal epithelium including large numbers of degenerative neutrophils. High vascularization and fibrosis were found in the submucosa (H&E stain).



**Fig 4.** Only a little earwax and healing of the tympanic membrane with no evidence of inflammatory changes were identified in the right ear canal via follow-up video otoscopic examination eight weeks postoperatively.

phils. High vascularization and fibrosis were found in the submucosa (Fig 3).

Eight weeks after, follow-up video otoscopic examination was performed for evaluation of prognosis. Only a little ear-wax and healing of the tympanic membrane with no evidence of inflammatory changes were identified in the right ear canal (Fig 4). According to the owner, the patient didn't show corresponding abnormal clinical signs. Although the follow-up period is only 5 months, there has been no evidence of recurrence observed.

## Discussion

In this report, the patient underwent traction-avulsion of the inflammatory polyp, though traction-avulsion method had a disadvantage in terms of recurrence. According to previous studies, treatment with traction-avulsion alone showed a higher rate of recurrence when compared to other surgical methods like ventral bulla osteotomy (1,17). Because it is difficult to remove affected tissue perfectly that remains in the middle ear (1,11). After traction, hemorrhage may be occurred, but usually it can be controlled easily via pressure with cotton-tipped applicators or cotton (13). However, traction-avulsion can be first-choice therapy while video otoscopy performing, because it needs no additional invasive surgical approach as well as less expensive and less time consuming. Extra surgery may be required if any clinical evidence of recurrence was revealed after traction-avulsion. It should be warned to understand potential recurrence of inflammatory polyp when clients requested operation of traction-avulsion alone (13).

Video otoscopy is known as a visual diagnosis method of ear canal and it commonly indicated in clinical signs of otitis externa or media. Video otoscopy could exploit best performance concerning visualization and diagnosis when combined with anesthesia and irrigation (16). It can be challenging to apply video or handheld otoscopy in patients with cats, small dogs, and stenosed ear canal because of the diameter of the tip (4). In this case, the patient (body weight, 5 kg) allowed to be revealed tympanic bulla uneventfully by 2.7 mm video otoscopy. Moreover, it was possible to use several instruments simultaneously during otoscopic exploration. Although arthroscopy sheath we possessed had no instrument channel, there were no remarkable difficulties in regard to manipulation of instruments. However, it may be difficult to perform the same procedure in smaller patients because of narrow ear canals.

In this patient, otic flushing was performed to remove the materials within the tympanic bulla. Otic flushing have been reported that it is most important technique for treatment of otitis media (8), and it is recommended generally for situations such as otitis media, a foreign body, or neoplasia is suspected as well as failure of owner-administered therapy for infection in a practical duration (7). Besides, easier suctioning of mucus that trapped within the mucoperiosteum could

be performed by hydrating with the flushing solution (8). The process of otic flushing in cats fundamentally not different from that in dogs, but a careful handling is required because of higher risk of neurologic side effects (7). Using video otoscopy, full examination of the ear during otic flushing is possible, and there are several advantages following this method: improved visualization, magnification, sampling, documentation of the ear before and after flushing (7,8). And for clearing the field of view, general anesthesia is advised (16).

About complications after surgical treatment of feline inflammatory polyps, it is well-known that ventral bulla osteotomy and total ear canal ablation with lateral bulla osteotomy has a higher rate of postoperative complications when compared with simple traction-avulsion (1,13,15). Above all, Horner's syndrome which may be revealed as neurologic signs secondary to middle ear disease also have a tendency to occur highly after ventral bulla osteotomy than after traction-avulsion, so clients should be cautioned about risk and manifestations of Horner's syndrome, although those symptoms are mostly self-limited in weeks to months (13). Otherwise, care must be taken during otic intervention because vestibular symptoms and deafness could arise as a result of mechanical trauma by manipulation of instruments, aggressive otic flushing, and ototoxic agents (7). And because secondary otitis media commonly involves, it is recommended to perform bacterial culture and antibiotics sensitivity test to improve prognosis (6). Hearing loss may occur when a tumor or a polyp located in the middle ear, but it will be complicated to diagnose the unilateral deafness (8).

In this case, we performed traction-avulsion of mass and otic flushing via video otoscopy in a patient of the feline inflammatory polyp with otitis externa and media. The patient didn't reveal any remarkable abnormality after surgery, and no signs of recurrence were found after 5 months follow up. It seems that video otoscopy will offer a useful option in therapy for following feline inflammatory polyp cases.

## References

1. Anderson DM, Robinson RK, White RA. Management of inflammatory polyps in 37 cats. *Vet Rec* 2000; 147: 684-687.
2. Baker G. Nasopharyngeal polyps in cats. *Vet Rec* 1982; 111: 43.
3. Bedford PG, Coulson A, Sharp NJ, Longstaffe JA. Nasopharyngeal polyps in the cat. *Vet Rec* 1981; 109: 551-553.
4. Cole LK. Otoscopic evaluation of the ear canal. *Vet Clin North Am Small Anim Pract* 2004; 34: 397-410.
5. Cook LB, Bergman RL, Bahr A, Boothe HW. Inflammatory polyp in the middle ear with secondary suppurative meningo-encephalitis in a cat. *Vet Radiol Ultrasound* 2003; 44: 648-651.
6. Fan TM, de Lorimier LP. Inflammatory polyps and aural neoplasia. *Vet Clin North Am Small Anim Pract* 2004; 34: 489-509.
7. Gortel K. Otic flushing. *Vet Clin North Am Small Anim Pract* 2004; 34: 557-565.
8. Gotthelf LN. Diagnosis and treatment of otitis media in

- dogs and cats. *Vet Clin North Am Small Anim Pract* 2004; 34: 469-487.
9. Ko SB, Jung JY, Kim JH, Kang SC, Yoon JS, Yang JH, Shin YE. Inflammatory polyps in 2 cats. *J Vet Clin* 2010; 27: 622-625.
  10. Kudnig ST. Nasopharyngeal polyps in cats. *Clin Tech Small Anim Pract* 2002; 17: 174-177.
  11. Lee DM, Yu DH, Nho DH, Song RH, Kim JH, Cho HS, Park JH, Park C. Nasopharyngeal polyp in a domestic short hair cat. *J Vet Clin* 2011; 28: 435-437.
  12. London CA, Dubilzeig RR, Vail DM, Ogilvie GK, Hahn KA, Brewer WG, Hammer AS, O'Keefe DA, Chun R, McEntee MC, McCaw DL, Fox LE, Norris AM, Klausner JS. Evaluation of dogs and cats with tumors of the ear canal: 145 cases (1978-1992). *J Am Vet Med Assoc* 1996; 208: 1413-1418.
  13. Muilenburg RK, Fry TR. Feline nasopharyngeal polyps. *Vet Clin North Am Small Anim Pract* 2002; 32: 839-849.
  14. Pope ER. Feline inflammatory polyps. *Semin Vet Med Surg (Small Anim)* 1995; 10: 87-93.
  15. Pratschke KM. Inflammatory polyps of the middle ear in 5 dogs. *Vet Surg* 2003; 32: 292-296.
  16. Rawlings CA. Diagnostic rigid endoscopy: otoscopy, rhinoscopy, and cystoscopy. *Vet Clin North Am Small Anim Pract* 2009; 39: 849-868.
  17. Veir JK, Lappin MR, Foley JE, Getzy DM. Feline inflammatory polyps: historical, clinical, and PCR findings for feline calici virus and feline herpes virus-1 in 28 cases. *J Feline Med Surg* 2002; 4: 195-199.

## 고양이에서 비디오 이경검사법을 이용한 염증성 폴립의 진단 및 치료 1례

박세진\* · 이승용\* · 김영기\*\*\* · 석성훈\* · 황재민\* · 정동혁\* · 이희천\*\* · 연성찬\*<sup>1</sup>

\*경상대학교 수의과대학 수의외과 · 행동학 연구실,

\*\*경상대학교 수의과대학 수의영상의학 실험실, \*\*\*해운대 동물 메디컬 센터

**요 약** : 1년 간 우측 귀에 재발성 외이염을 앓다가 이도 내 종괴가 발견된 19개월령의 증성화된 수컷 잡종 고양이에서 종괴의 제거를 시행하였다. 전신마취 후 2.7 mm 내시경을 우측 이도로 삽입하였으며, 원활한 시야 확보를 위해 이도 내 세척을 동시에 시행하였다. 이도 내에서 4.9 mm 직경의 둥근 붉은색 종괴가 확인되었고 traction-avulsion 방법으로 제거되었다. 제거 후 고막 파열이 확인되었으며, 고실 내의 삼출물 제거를 위해 0.9% 멸균생리식염수로 귀를 플러싱하였다. 제거된 종괴는 조직검사 결과 심한 궤양을 동반한 육아조직으로 진단되었다. 술 후 환축은 특별한 부작용을 나타내지 않았으며, 5개월이 경과된 현재 재발의 징후는 발견되지 않았다. 비디오 이경검사법의 사용은 고양이 염증성 폴립의 치료를 위한 효과적인 방법이 될 수 있을 것으로 생각된다.

**주요어** : 고양이, 염증성 폴립, 비디오 이경검사법, 귀 플러싱