

Deep Vein Thrombosis Due to Hematoma as a Rare Complication after Femoral Arterial Catheterization

Minsoo Kim, Jong-Young Lee¹, Cheol Whan Lee¹, Seung-Whan Lee¹,
Soo-Jin Kang¹, Yong Hoon Yoon, Sang Yong Om, Young-Hak Kim¹

Departments of Internal Medicine, ¹Cardiology, Asan Medical Center, University of Ulsan College of Medicine, Seoul, Korea

Hematoma is quite a common complication of femoral arterial catheterization. However, to the best of our knowledge, there have been no previous studies regarding deep vein thrombosis (DVT) caused by compression of a vein due to a hematoma. We report a case of a hematoma developing after femoral arterial catheterization and causing extensive symptomatic DVT. A 59-year-old male was seen in our Emergency Department with right lower leg swelling 15 days after coronary stent implantation performed using right femoral artery access. Computed tomographic (CT) scanning revealed a large hematoma (45 mm in its longest diameter) compressing the common femoral vein and with DVT from the right external iliac vein to the popliteal vein. Due to the extensive DVT involvement, we decided to release the compressed common femoral vein by surgical evacuation of the large hematoma. However, even following evacuation of the hematoma, as the DVT did not resolve soon, further mechanical thrombectomy and catheter-directed thrombolysis were performed. Angiography then showed nearly resolved DVT, and the leg swelling was improved. The patient was discharged with the anticoagulation medication, warfarin.

Key Words: Angioplasty, Catheterization, Hematoma, Venous thrombosis, Thrombolytic therapy

INTRODUCTION

Vascular complications related to arterial catheterization occur in 1.7% to 8.4% of the percutaneous coronary interventions performed using femoral access.¹⁻⁵ Most of the reported complications are bleeding, hematoma, and pseudoaneurysm. Deep-vein thrombosis (DVT) as a complication of femoral arterial catheterization has also been reported with an infrequent incidence of 0.05% to 2.4%,^{6,7} and most of the reported cases were considered to have been caused by prolonged manual compression after the removal of sheath. We report a case of hematoma related to femoral arterial

catheterization causing compressive venous obstruction and thrombosis. In this case, surgical evacuation of the hematoma, mechanical thrombectomy, and catheter-directed thrombolysis were required in order to improve the venous thrombosis.

CASE

A 59-year-old male patient was seen in our Emergency Department with right, lower extremity swelling and a right inguinal mass lesion. Approximately 15 days before being seen in the Emergency Department, the patient had undergone elective coronary stenting (Xience Prime[®], Abbott Vascular, Ireland; 4.0×18 mm) in the proximal right coronary artery and performed using right femoral arterial catheterization with a 7Fr. Sheath. The procedure was completed without any complications. A vascular closure device (PercloseProglide[®], Abbott Vascular, Ireland; 6Fr.) was used for management of the puncture site. The patient was discharged with 100 mg of aspirin and 75 mg of clopidogrel one day following the

Received: October 11, 2012, Revised: October 19, 2012,
Accepted: October 22, 2012

Corresponding Author: Young-Hak Kim, Department of Cardiology, Asan Medical Center, University of Ulsan College of Medicine, 88, Olympic-ro 43-gil, Songpa-gu, Seoul 138-736, Korea
Tel: 82-02-3010-3955, Fax: 82-2-486-5918
E-mail: mdyhkim@amc.seoul.kr

stent. Fifteen days after his discharge, the patient revisited the Emergency Department due to aggravated, right lower extremity swelling and a mass in the puncture site.

Distal arterial pulsation in the dorsalis pedis and the posterior tibial arteries was intact, and the patient did not complain of any other symptoms such as chest pain, dyspnea or dizziness. Hemoglobin was 13.9 g/dL which was not decreased from that seen at discharge. Other laboratory data were unremarkable (WBC 8,500/mm³, platelet 313,000/mm³, aPTT 32.0 sec, PT 103.4%, AST 26 IU/L, ALT 24 IU/L, total bilirubin 0.4 mg/dL, creatinine 0.78 mg/dL, C-reactive protein 0.1 mg/dL, CK 75 IU/L, CK-MB 0.3 ng/mL, troponin-I 0.006 ng/mL, and BNP 25 pg/mL). Computed tomography (CT) of the lower extremity revealed a large hematoma (45 mm in its longest diameter) in the right inguinal area (Fig. 1A) and extensive DVT from the right external iliac vein (EIV) to the popliteal vein (Fig. 1B). Pulmonary embolism CT showed no evidence of pulmonary thrombo-embolism. Anticoagulation with intravenous infusion of unfractionated heparin (target aPTT: 50.0-75.0 sec) was administered immediately. After 24-hours of heparin, infusion venography via the popliteal vein was performed. There was complete obstruction of the common femoral vein (CFV) due to external compression from the hematoma (Fig. 1C). Dilatation using a balloon 10-mm in diameter for CFV occlusion was unsuccessful due to the immediate recoil (Fig. 1D).

On the next day, surgical hematoma evacuation for release of external compression was successfully performed. On the surgical field, adhesive hematoma mixed with inflammation and fat tissue rather than pure hematoma, was observed. The pathology findings showed fibroblastic proliferation with hemorrhage and a heterotopic, chondro-osseous lesion, thus suggesting ossified hematoma.

Two days following the evacuation, the surgical site oozed with pus. Distal edema aggravated and leukocytosis (WBC 13,100/mm³) developed with elevated C-reactive protein (4.55 mg/dL). Antibiotics (cefazolin 2 gram per 8 hours) were administered in order to address the risk of infection. After administration of the antibiotics, the surgical site improved and inflammatory markers such as the leukocyte count as well as the C-reactive protein value normalized. However, despite the improving infection signs at the surgical site, distal edema still remained.

Even after seven days of continuous anticoagulation with

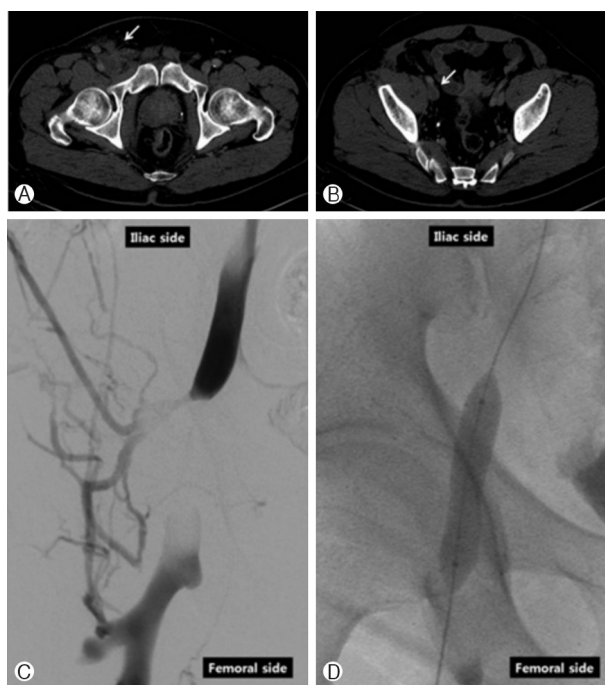


Fig. 1. CT and venography with balloon dilatation before the hematoma evacuation. (A) Hematoma as a low-density lesion in the right inguinal area (arrow). (B) Venous thrombosis in the right external iliac vein (arrow). (C) Complete obstruction of the common femoral vein due to external compression. (D) 10-mm balloon dilatation which inflated easily, but immediately recoiled.

intravenous heparinization, the patient's right leg swelling did not improve. CT angiography was then performed to evaluate the response to the anticoagulation. Multiple, small hematomas with indistinct delineation around the right CFV, remained, although the main hematoma was resolved after surgical evacuation, and compression of the right CFV was partially relieved (Fig. 2A). DVT in the EIV was resolved, although it still remained from the superficial femoral vein (SFV) to the calf veins (Fig. 2B-D). Transluminal mechanical thrombectomy with heparinization via a right popliteal vein approach was then done, and extensive thrombi were extracted (Fig. 3A). An immediate, follow-up angiogram showed extensive remaining thrombosis which had rapidly developed (Fig. 3B). Additional, catheter-directed thrombolysis with urokinase was then performed (4,400 units/kg intravenously during the initial 10 minutes and then 2,200 units/kg per hour for 12 hours). The final, follow-up angiogram showed much resolved thrombi (Fig. 3C), after which the edema resolved gradually and the patient was discharged and instructed to take aspirin,

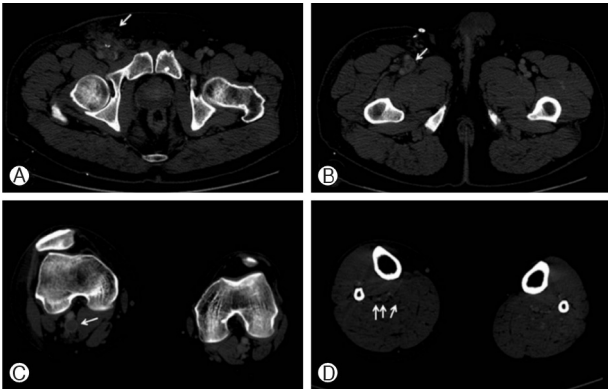


Fig. 2. CT obtained six days after the hematoma evacuation. (A) Remaining, multiple, small hematomas with indistinct delineation around the right common femoral vein (arrow). (B) Venous thrombosis in the femoral vein (arrow). (C) Venous thrombosis in the popliteal vein (arrow). (D) Venous thrombosis in the calf veins (arrows).

clopidogrel, and warfarin with a target INR of 2.0 to 3.0.

DISCUSSION

Vascular complications, such as bleeding, hematoma, and pseudoaneurysm, related to the femoral arterial catheterization, occur in 1.7% to 8.4% of patients.^{1,5} Among these complications, major bleeding has been associated with increased mortality. Doyle et al. found that major femoral bleeding and blood transfusions were associated with a significant increase in the 30-day mortality rate.³ In other studies, association of one-year mortality to major bleeding has been reported. Applegate et al. reported that vascular complication is an independent predictor of non-fatal myocardial infarction or death by one year, if accompanied by thrombolysis in myocardial infarction major and minor bleeding.⁵ Romaguera et al. reported that vascular complications with decreased hematocrit of more than 9.2% caused an increased risk for death by one year.⁴ Risk factors for femoral bleeding after catheterization include periprocedural use of heparin or fibrinolytic therapy, repeated procedures, peripheral artery disease, advanced patient age, obesity, duration of time that the sheath remains in place particularly if >15 hours, the use of an intra-aortic balloon pump, larger arterial sheath size, and cannulation of the superficial femoral artery.^{8,9} Vascular closure devices, bivalirudin, a mechanical clamp, and a radial approach can, therefore, be the optimal strategies for reducing hemorrhagic complications. Although meta-analyses regar-

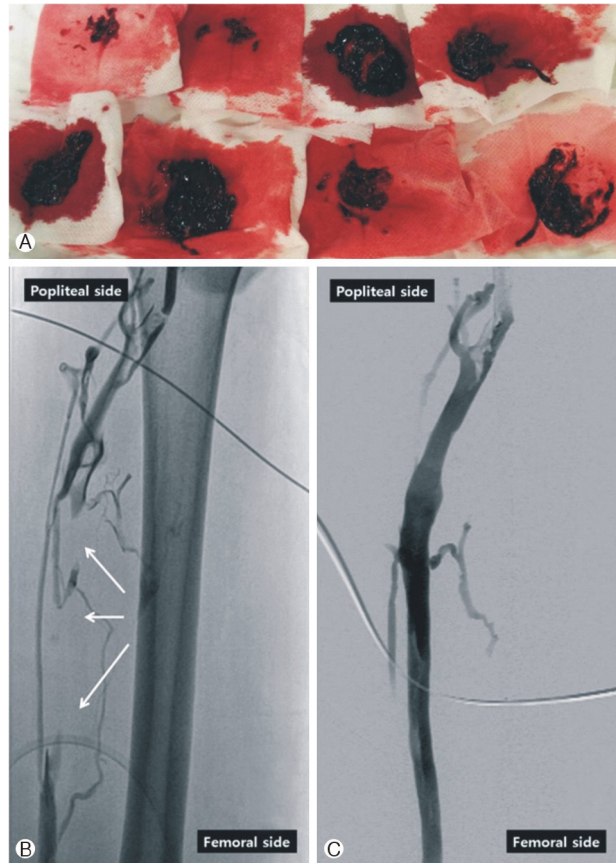

Fig. 3. (A) Extracted thrombi. (B) Venogram obtained after the mechanical thrombectomy shows rapidly developing venous thrombosis (arrows). (C) Venograms obtained after additional, catheter-directed thrombolysis show much resolved thrombi.

ding the vascular closure devices have reported unchanged or even an increased bleeding risk,^{10,11} a large amount of recent data from the National Cardiovascular Data Registry showed a decreased bleeding risk, particularly among the patients at greatest risk for bleeding.¹² The use of direct thrombin inhibitors such as bivalirudin rather than heparin and a glycoprotein 2b/3a receptor blocker are associated with a lower risk of hemorrhagic complications.^{13,14} A mechanical clamp reduced the frequency of ultrasounddefined vascular complications by 63 percent in one trial.¹⁵ Despite the absence of the risk factors listed above, and even with the usage of a vascular closure device, hematoma causing compressive DVT occurred in our patient. Therefore, a learning curve in order to be familiar with and be able to skillfully use a closure device, is necessary. Therefore, even with the use of a closure device, additional mechanical compression and intense surveillance are required.

The incidence of DVT as a complication of femoral arterial catheterization has been reported as occurring in 0.05% to 2.4% of patients.^{6,7} Filis et al. reported five cases of DVT in 10,450 patients who underwent femoral arterial puncture for cardiac catheterization.⁷ In all five of these patients, DVT was detected after the discharge during the antiplatelet treatment and was successfully resolved using conservative management. Post-catheterization manual compression was the obvious cause for DVT in all of these cases. Zahn et al. prospectively examined duplex sonography for 450 consecutive patients undergoing diagnostic cardiac catheterization.⁶ Partially occluding venous thrombi were detected in¹¹ patients, and only one patient had extravascular compression. Only two patients had clinical symptoms of DVT, such as edema, and no one developed symptoms of pulmonary embolism. There are also some case reports regarding DVT caused by manual compression following femoral arterial catheterization.^{16,17} Concurrent pulmonary embolism and stroke via the foramen ovale have even been reported,¹⁸ and there are only two reported cases of DVT associated with extravascular compression following cardiac catheterization.^{19,20} Because both of these cases resulted from pseudoaneurysm, ours is the first case report of DVT associated with extravascular compression from hematoma following femoral arterial catheterization.

Post-thrombotic syndrome (PTS) consisting of leg pain, edema, venous ectasia, and skin induration with ulceration, occurs in 20% to 50% of chronic DVT patients. PTS has a significant impact on their disease-specific quality of life.²¹ Compared to anticoagulation alone, catheter-directed thrombolysis (CDT) successfully improved their quality of life, and this effect was correlated with successful lysis on phlebography.²² The safety and successful long-term patency of CDT have been reported.^{23,24} In our patient, hematoma evacuation and transluminal mechanical thrombectomy failed to resolve the DVT, although CDT successfully improved the DVT. A further, randomized study to determine the efficacy of early CDT in DVT is currently in progress.²⁵

REFERENCES

1. Sherev DA, Shaw RE, Brent BN. Angiographic predictors of femoral access site complications: implication for planned percutaneous coronary intervention. *Catheter Cardiovasc Interv* 2005;65:196-202.
2. Ohlow MA, Secknus MA, von Korn H, Neumeister A, Wagner A, Yu J, et al. Incidence and outcome of femoral vascular complications among 18,165 patients undergoing cardiac catheterisation. *Int J Cardiol* 2009;135:66-71.
3. Doyle BJ, Ting HH, Bell MR, Lennon RJ, Mathew V, Singh M, et al. Major femoral bleeding complications after percutaneous coronary intervention: incidence, predictors, and impact on long-term survival among 17,901 patients treated at the Mayo Clinic from 1994 to 2005. *JACC Cardiovasc Interv* 2008;1:202-9.
4. Romaguera R, Wakabayashi K, Laynez-Carnicero A, Sardi G, Maluenda G, Ben-Dor I, et al. Association between bleeding severity and long-term mortality in patients experiencing vascular complications after percutaneous coronary intervention. *Am J Cardiol* 2012;109:75-81.
5. Applegate R, Sacrinty M, Little W, Gandhi S, Kutcher M, Santos R. Prognostic implications of vascular complications following PCI. *Catheter Cardiovasc Interv* 2009;74:64-73.
6. Zahn R, Fromm E, Thoma S, Lotter R, Zander M, Wagner S, et al. Local venous thrombosis after cardiac catheterization. *Angiology* 1997;48:1-7.
7. Filis K, Arhontovasilis F, Theodorou D, Albanopoulos K, Lagoudianakis E, Manouras A, et al. Management of early and late detected vascular complications following femoral arterial puncture for cardiac catheterization. *Hellenic J Cardiol* 2007;48:134-42.
8. Muller DW, Shamir KJ, Ellis SG, Topol EJ. Peripheral vascular complications after conventional and complex percutaneous coronary interventional procedures. *Am J Cardiol* 1992;69:63-8.
9. Popma JJ, Satler LF, Pichard AD, Kent KM, Campbell A, Chuang YC, et al. Vascular complications after balloon and new device angioplasty. *Circulation* 1993;88:1569-78.
10. Biancari F, D'Andrea V, Di Marco C, Savino G, Tiozzo V, Catania A. Meta-analysis of randomized trials on the efficacy of vascular closure devices after diagnostic angiography and angioplasty. *Am Heart J* 2010;159:518-31.
11. Koreny M, Riedmüller E, Nikfardjam M, Siostrzonek P, Müllner M. Arterial puncture closing devices compared with standard manual compression after cardiac catheterization: systematic review and meta-analysis. *JAMA* 2004;291:350-7.
12. Marso SP, Amin AP, House JA, Kennedy KF, Spertus JA, Rao SV, et al. Association between use of bleeding avoidance strategies and risk of periprocedural bleeding among patients undergoing percutaneous coronary intervention. *JAMA* 2010;303:2156-64.
13. Stone GW, McLaurin BT, Cox DA, Bertrand ME, Lincoff AM, Moses JW, et al. Bivalirudin for patients with acute coronary syndromes. *N Engl J Med* 2006;355:2203-16.
14. Stone GW, White HD, Ohman EM, Bertrand ME, Lincoff AM, McLaurin BT, et al. Bivalirudin in patients with acute coronary syndromes undergoing percutaneous coronary intervention: a subgroup analysis from the Acute Catheterization and Urgent Intervention Triage strategy (ACUITY) trial. *Lancet* 2007;369:907-19.
15. Pracyk JB, Wall TC, Longabaugh JP, Tice FD, Hochrein J, Green C, et al. A randomized trial of vascular hemostasis techniques to reduce femoral vascular complications after

- coronary intervention. *Am J Cardiol* 1998;81:970-6.
16. Klein-Weigel P, Pillokat A, Klemens M, Köning C, Wolbergs S, Schröder H, et al. Proximal deep venous thrombosis following PTA of the superficial femoral artery--an obligation to disclose a complication that is rarely taken into account. *Vasa* 2006;35:41-4.
 17. Ardal H, Yilmaz O, Arbatli H, Kuzucu K, Sönmez B. Deep venous thromboembolism and pulmonary embolization as a rare complication of diagnostic femoral catheterization and prevention of recurrence with inferior vena cava filter prior to cardiac surgery. *Phlebology* 2010;25:207-9.
 18. Chisci E, Setacci F, Giubolini M, de Donato G, Setacci C. Stroke and pulmonary embolism following manual and bandage compression after bleeding from a common femoral artery access site. *J Cardiovasc Surg (Torino)* 2011;52:849-51.
 19. Slyska R, Mondek P, Lofaj P, Sefránek V. Post-catheterization pseudoaneurysm of the femoral artery--an unusual cause of femoral vein thrombosis--case report and review of the literature. *Rozhl Chir* 2004;83:113-7.
 20. Gauthier GM, Dieter RS. Successful treatment of a femoral artery pseudoaneurysm mimicking a deep venous thrombosis following cardiac catheterization. *Catheter Cardiovasc Interv* 2002;57:75-8.
 21. Kahn SR, Hirsch A, Shrier I. Effect of postthrombotic syndrome on health-related quality of life after deep venous thrombosis. *Arch Intern Med* 2002;162:1144-8.
 22. Comerota AJ, Throm RC, Mathias SD, Haughton S, Mewissen M. Catheter-directed thrombolysis for iliofemoral deep venous thrombosis improves health-related quality of life. *J Vasc Surg* 2000;32:130-7.
 23. Mewissen MW, Seabrook GR, Meissner MH, Cynamon J, Labropoulos N, Haughton SH. Catheter-directed thrombolysis for lower extremity deep venous thrombosis: report of a national multicenter registry. *Radiology* 1999;211:39-49.
 24. Baekgaard N, Broholm R, Just S, Jørgensen M, Jensen LP. Long-term results using catheter-directed thrombolysis in 103 lower limbs with acute iliofemoral venous thrombosis. *Eur J Vasc Endovasc Surg* 2010;39:112-7.
 25. Comerota AJ. The ATTRACT trial: rationale for early intervention for iliofemoral DVT. *Perspect Vasc Surg Endovasc Ther* 2009;21:221-4.