

## Extended Aortic Arch Replacement Through the L-Incision Approach

Jin-Ho Choi, M.D.<sup>1</sup>, Jung-Joo Hwang, M.D.<sup>1</sup>, Hyun-Min Cho, M.D.<sup>2</sup>, Tae-Yeon Lee, M.D.<sup>2</sup>

There are various methods for approaching the aortic arch, such as median sternotomy or lateral thoracotomy. However, accessing the site of distal anastomosis is problematic when the distal arch is extensively involved. We report a case of extended aortic arch replacement and coronary artery bypass through the L-incision approach.

Key words: 1. Aorta, arch  
2. Aneurysm

### CASE REPORT

A 55-year-old man was admitted with progressing dysphagia and dyspnea. He had been diagnosed with aortic arch aneurysm 4 years earlier. At that time, a computed tomography (CT) scan had demonstrated a huge aortic arch aneurysm with a maximal diameter of about 6.8 cm (Fig. 1A). However, he had refused further treatment at the time. On arrival, a chest radiograph revealed marked aneurysmal dilatation of the entire arch (Fig. 1B). On the follow-up CT scan, the size of the aneurysm had increased up to a maximal diameter about 9 cm and the trachea was nearly collapsed and deviated into the right side (Fig. 1C). The proximal descending aorta was also involved down to the level of the 7th thoracic vertebra. The patient was also diagnosed with single vessel disease by coronary angiography performed for pre-operative evaluation. Therefore, we planned total arch replacement and a coronary arterial bypass graft.

General anesthesia was administered and a double-lumen endotracheal tube was used to permit deflation of the left

lung during the distal anastomosis. The patient was maintained in a supine position with the left chest elevated by about 30 degrees. Initially, the right axillary artery and left femoral artery were exposed for cardiopulmonary bypass. After exposure of the right axillary artery and left femoral artery, an L-shaped skin incision was made through an upper partial sternotomy and left anterior thoracotomy along the 5th intercostal space (Fig. 2). Thereafter, the left internal thoracic artery was harvested for coronary arterial bypass grafting in a skeletonized fashion. After exposure of the innominate artery and left common carotid artery, the left subclavian artery was exposed through a small left supraclavicular incision to the neck because the left subclavian artery was seated deeply and deviated upwards. After systemic heparinization, arterial cannulae in each artery for systemic circulation were inserted through the right axillary and left femoral artery with Seldinger's technique. Venous drainage was performed through a single two-stage cannula inserted into the right atrial appendage. Cardiopulmonary bypass was established and a left ventricular vent catheter was inserted through the right

Department of Thoracic and Cardiovascular Surgery, <sup>1</sup>Eulji University School of Medicine, <sup>2</sup>Konyang University College of Medicine

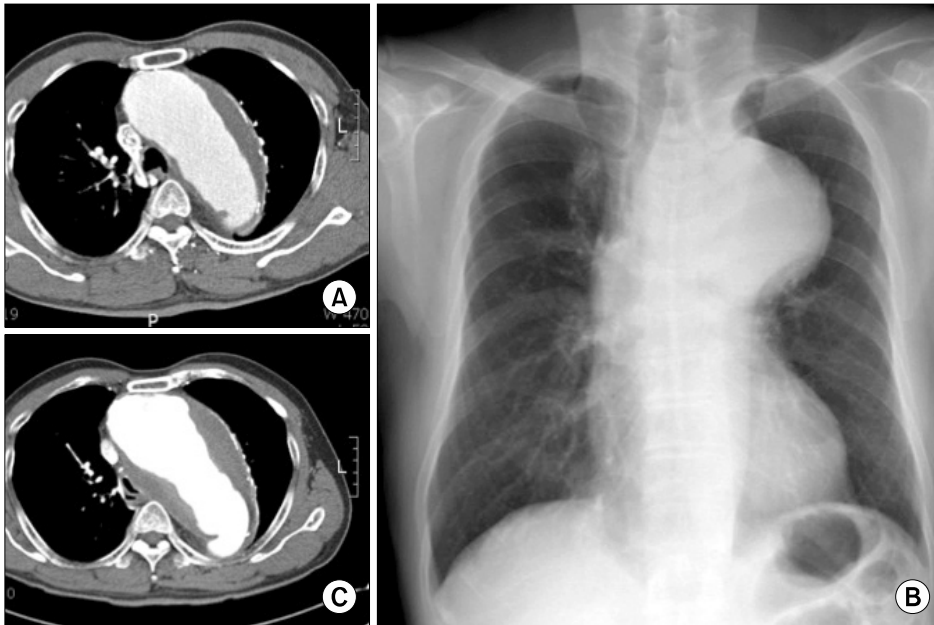
Received: September 3, 2012, Revised: November 5, 2012, Accepted: November 14, 2012

Corresponding author: Jin-Ho Choi, Department of Thoracic and Cardiovascular Surgery, Eulji University School of Medicine, 77 Gyeryong-ro 771beon-gil, Jung-gu, Daejeon 301-746, Korea

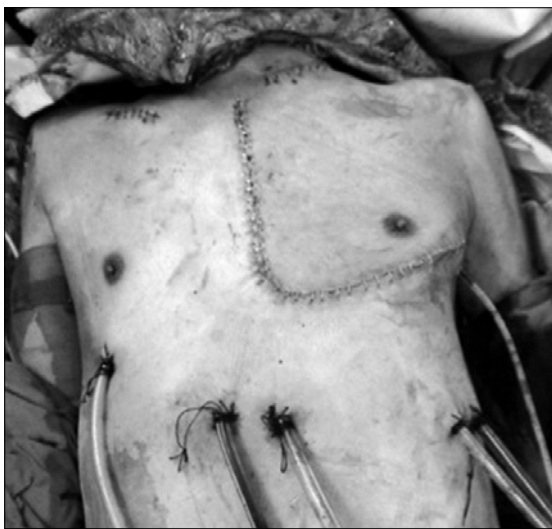
(Tel) 82-42-611-3159 (Fax) 82-42-600-9090 (E-mail) [jinhc72@hanmail.net](mailto:jinhc72@hanmail.net)

© The Korean Society for Thoracic and Cardiovascular Surgery. 2013. All rights reserved.

© This is an open access article distributed under the terms of the Creative Commons Attribution Non-Commercial License (<http://creativecommons.org/licenses/by-nc/3.0>) which permits unrestricted non-commercial use, distribution, and reproduction in any medium, provided the original work is properly cited.

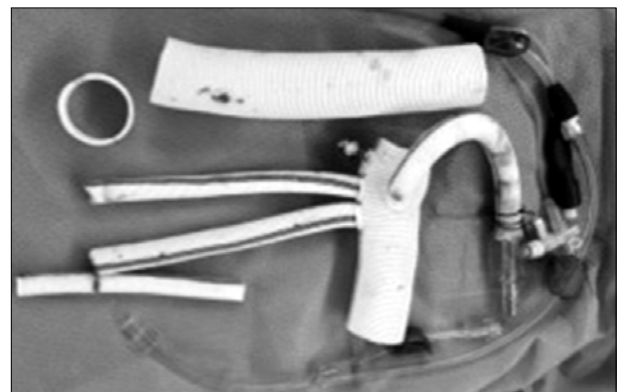

**Fig. 1.** Computed tomography (CT) scan and chest radiograph show total arch aneurysm. (A) About 6.8 cm sized aneurysm was revealed on previous CT scan 4 years ago. (B) Chest radiograph shows mediastinal widening and prominent aortic arch on arrival. (C) The size of aneurysm was increased up to 9 cm on follow-up CT scan.



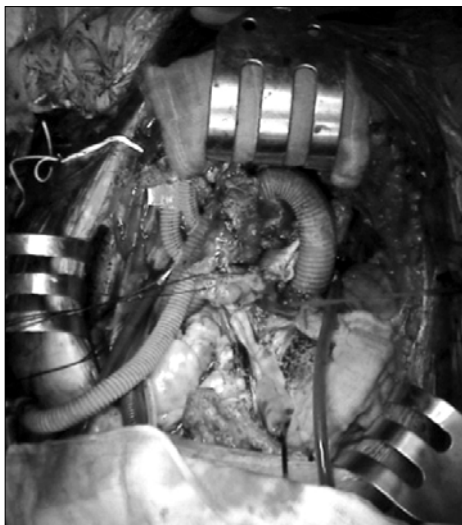
**Fig. 2.** L-incision approach (combined partial median sternotomy and left thoracotomy using 6th intercostal space) for extended total arch replacement.

upper pulmonary vein prior to lowering the body temperature. After aortic cross-clamping, HTK solution (Custodiol; Kohler Chemie, Alsbach-Hahnlein, Germany) was delivered via the aortic root. The ascending aorta was transected at the sinotubular junction level and proximal anastomosis was constructed with a three-branched Dacron graft prepared previously (Fig. 3) from a 28 mm InterGard four-branched graft



**Fig. 3.** Sealed graft with four branches was prepared with ligation of distal arch vessel and connection of side branch with 3-way valve for reperfusion of the heart after proximal anastomosis.

(Maquet, Rastatt, Germany). After hypothermic circulatory arrest was accomplished by cooling to a rectal temperature of 20°C with cardiopulmonary bypass, the aortic arch was opened. The innominate artery was clamped and antegrade selective cerebral perfusion was started using the right axillary artery and a catheter placed into the left carotid artery. After clamping the descending aorta at the level of the 9th thoracic vertebra, cardiopulmonary bypass was started for lower body perfusion through the femoral artery cannula. Next, the left subclavian artery was ligated with an EndoGIA

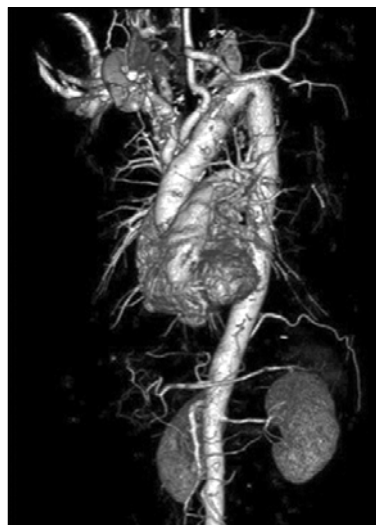

**Fig. 4.** After graft anastomosis, heart and brain were reperfused from the other branch of the graft after discontinuation of cerebral perfusion.

30×4.8 mm stapler (Covidien, Mansfield, MA, USA) and an innominate artery and left common carotid artery were reconstructed with the branches of the graft. The heart and brain were reperfused from the other branch of the graft after discontinuation of cerebral perfusion (Fig. 4). After left lung deflation, distal anastomosis was performed with another 28 mm Dacron tube graft. Finally, proximal graft and distal graft anastomosis was performed during whole body perfusion. After completion of the graft anastomosis, we performed a carotid to left subclavian bypass graft using a remnant of the 8 mm Dacron graft through the left supraclavicular incision previously made. Systemic rewarming was then initiated. During rewarming, we performed a left internal mammary artery to left anterior descending artery bypass graft. The total operation time was 350 minutes. The total cardiopulmonary bypass time and aortic cross clamping time were 280 and 120 minutes, respectively. The operation was uneventful and the patient was discharged after 2 weeks. A postoperative follow-up CT scan revealed no aneurysmal dilatation of the aorta (Fig. 5).

## DISCUSSION

Although many surgical approaches have been reported for



**Fig. 5.** Postoperative follow-up computed tomography scan revealed no aneurysmal dilatation of aorta.

treatment of aortic arch aneurysm [1,2], the median sternotomy is most frequently used [3,4]. However, in patients who have extensive aortic pathology involving the distal arch, exposure through a sternotomy frequently results in the need for troublesome procedures. In general, a two-stage operation is recommended for the treatment of extensive aortic disease involving the distal arch. However, it is not rare that a single-stage operation is inevitable. Kouchoukos [5] reported excellent results through bilateral anterior thoracotomy. Choi et al. [6] reported entire thoracic aortic replacement via full sternotomy and anterior thoracotomy. However, frequently, these approach methods involve respiratory and wound complications closely related to extensive bone splitting and muscle division. The L-incision approach has several advantages over these approaches. It secures a clear view during distal anastomosis and intracardiac procedures comparable to previous approaches; therefore, it can reduce the risk of occurrence of postoperative hemorrhage from the site of distal anastomosis. At the same time, the lower part of the sternum is not split, and the structure of the thorax can be maintained, which is favorable for maintaining postoperative pulmonary function and for wound healing [7].

In conclusion, the L-incision approach should be considered one useful option for operating on extensive aortic arch disease. In addition, through the L-incision approach, it is

feasible to perform coronary revascularization or intracardiac procedures.

### CONFLICT OF INTEREST

No potential conflict of interest relevant to this article was reported.

### REFERENCES

1. Sasaguri S, Yamamoto S, Fukuda T, Hosoda Y. *Retrograde cerebral perfusion through antero-axillary thoracotomy in the aortic arch surgery*. Eur J Cardiothorac Surg 1997;11: 657-60.
2. Imazeki T, Yamada T, Irie Y, Katayama Y, Kiyama H. *Trapdoor thoracotomy as a surgical approach for aortic arch aneurysm*. Ann Thorac Surg 1998;66:272-4.
3. Borst HG, Heinemann MK, Stone CD. *Surgical treatment of aortic dissection*. New York: Churchill Livingstone International; 1996.
4. Svensson LG, Crawford ES. *Cardiovascular and vascular disease of the aorta*. Philadelphia: WB Saunders; 1997.
5. Kouchoukos NT. *One-stage repair of extensive thoracic aortic disease*. J Thorac Cardiovasc Surg 2010;140(6 Suppl): S150-3.
6. Choi JH, Park KH, Jun TG, Lee YT, Park PW. *Single stage replacement of entire thoracic aorta for chronic aortic dissection*. Korean Thorac Cardiovasc Surg 2001;34:865-9.
7. Tominaga R, Kurisu K, Ochiai Y, et al. *Total aortic arch replacement through the L-incision approach*. Ann Thorac Surg 2003;75:121-5.