

# Apical foramen morphology according to the length of merged canal at the apex

Hee-Ho Kim, Jeong-Bum Min, Ho-Keel Hwang\*

Department of Conservative Dentistry, Chosun University School of Dentistry, Gwangju, Korea

**Objectives:** The aim of this study was to investigate the relationship between the apical foramen morphology and the length of merged canal at the apex in type II root canal system. **Materials and Methods:** This study included intact extracted maxillary and mandibular human premolars ( $n = 20$ ) with fully formed roots without any visible signs of external resorption. The root segments were obtained by removing the crown 1 mm beneath the cementum-enamel junction (CEJ) using a rotary diamond disk. The distance between the file tip and merged point of joining two canals was defined as Lj. The roots were carefully sectioned at 1 mm from the apex by a slow-speed water-cooled diamond saw. All cross sections were examined under the microscope at  $\times 50$  magnification and photographed to estimate the shape of the apical foramen. The longest and the shortest diameter of apical foramen was measured using ImageJ program (1.44p, National Institutes of Health). Correlation coefficient was calculated to identify the link between Lj and the apical foramen shape by Pearson's correlation. **Results:** The average value of Lj was 3.74 mm. The average of proportion (P), estimated by dividing the longest diameter into the shortest diameter of the apical foramen, was 3.64. This study showed a significant negative correlation between P and Lj ( $p < 0.05$ ). **Conclusions:** As Lj gets longer, the apical foramen becomes more ovally shaped. Likewise, as it gets shorter, the apical foramen becomes more flat shaped. (*Restor Dent Endod* 2013;38(1):26-30)

**Key words:** Apical foramen; Type II root canal system

Received October 17, 2012;  
 Revised November 5, 2012;  
 Accepted November 9, 2012.

Kim HH; Min JB; Hwang HK,  
 Department of Conservative Dentistry, Chosun University School of Dentistry, Gwangju, Korea

**\*Correspondence to**

Ho-Keel Hwang, DDS, PhD.  
 Professor, Department of Conservative Dentistry, Chosun University School of Dentistry, 375 Seosuk-dong, Dong-gu, Gwangju, Korea 501-825  
 TEL, +82-62-220-3840; FAX, +82-62-223-9064; E-mail, rootcanal@hanmail.net

## Introduction

A thorough knowledge of the anatomy of root canal system is required to improve the success rate of endodontic treatment.<sup>1-4</sup> Because the root canal system is complex, canals may branch, divide, and rejoin taking various pathways to the apex. In clinical situation, clinicians usually depend on two-dimensional radiograph for understanding the anatomy of root canal system. The early recognition of these configurations facilitates cleaning, shaping, and obturation of the root canal system. Unfortunately, two-dimensional radiographic images do not reveal all anatomic characteristics.<sup>5,6</sup>

Furthermore, the apical foramen often does not represent a round shape.<sup>7</sup> Many root canals represent an oval or flat apical foramen that makes measuring the diameter of root canals difficult.<sup>8-10</sup> With regard to obturation, some studies verified that many of the canal surfaces (especially in the apical region) are not touched during canal preparation because of the oval or irregular configuration.<sup>11-13</sup> These untouched canal surfaces may account for the failure of endodontic treatment.

※This study was supported by research fund from Chosun university dental hospital in the year of 2012.

This is an Open Access article distributed under the terms of the Creative Commons Attribution Non-Commercial License (<http://creativecommons.org/licenses/by-nc/3.0>) which permits unrestricted non-commercial use, distribution, and reproduction in any medium, provided the original work is properly cited.

Weine categorized the root canal systems in single root into four basic types: Type I, single canal from the pulp chamber to the apex; Type II, two separate canals leaving the chamber but merging short of the apex to form only one canal; Type III, two separate canals leaving the chamber and exiting the root in separate apical foramina; Type IV, one canal leaving the pulp chamber but dividing short of the apex into two separate and distinct canal with separate apical foramina.<sup>14</sup> Vertucci *et al.* had reported the anatomy of Type II root canal systems.<sup>15</sup> The complexity of Type II root canal systems prevents these canals from being cleaned, shaped, and obturated effectively during root canal therapy. Once recognized, the type II root canal systems provide challenges with respect to debridement and obturation. In point of debridement, Jeong *et al.* investigated the sizes of master apical file by instrumentation in type II root canal systems.<sup>16</sup>

The aim of this study was to investigate the relationship between the apical foramen morphology and the length of the merged canal at the apex in type II root canal systems.

## Materials and methods

### 1. Selection and preparation of teeth

The teeth were collected from a general dental practice and had been extracted for pulpal, periodontal, and orthodontic reasons. This study included intact extracted maxillary and mandibular human premolars ( $n = 20$ ) with fully formed roots without any visible signs of external resorption. None of these teeth had prior root canal treatment. The teeth were manually cleaned from the calculus and periodontal tissues. The teeth were stored in a 0.1% chlorhexidine solution. Preoperative radiographs were taken to estimate the root canal type. And the teeth with Type II root canal systems were classified. The root segments were obtained by removing the crown 1 mm beneath the cementum-enamel junction (CEJ) using rotary diamond disk. The root canals were negotiated with a size 10 K hand file to avoid modifying the canal's apical anatomy and irrigated with 5.25% sodium hypochlorite.

### 2. Measurement

The reference length of the root canal was measured as follows. First, a size 10 K hand file was inserted into the root canal until the file tip was visible at the apical foramen. Another 10 K hand file was inserted into the root canal until the file tip was joined with existing file. The two 10 K hand files joined at the point. The distance between the file tip and merged point of joining two canals was defined as  $L_j$ . And  $L_j$  was measured using ImageJ program (1.44p, National Institutes of Health, Bethesda, MD, USA). Postoperative radiographs were taken to estimate  $L_j$  (Figure 1).

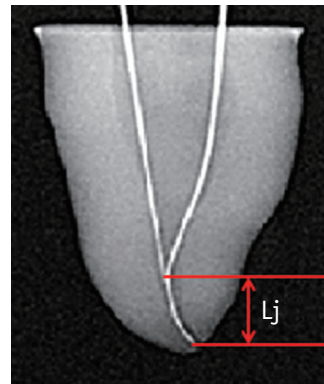


Figure 1. The distance between the file tip and merging point of two joining canals ( $L_j$ ) on radiograph.

### 3. Evaluation

The specimens were embedded in epoxy resin. After the epoxy resin had set, the roots were carefully sectioned at 1 mm from the apex by slow-speed water-cooled diamond saw (Isomet, Buehler Ltd., Lake Bluff, IL, USA) positioned perpendicularly to the root canal and prepared for microscopic analysis. Each cross section was prepared with ethylenediaminetetraacetic acid (EDTA) irrigant (PREP EDTA Gel, Vision, Seoul, Korea) for 5 minutes, then rinsed with saline and dried. Afterwards, each cross section was stained with methylene blue to highlight the contours of the root canal, then rinsed with saline and dried. All cross sections were examined under the microscope (BX60MF, Olympus Optical Co. Ltd., Japan) at  $\times 50$  magnification and photographed to estimate the shape of the apical foramen. The longest and the shortest diameter of apical foramen was measured using ImageJ program (1.44p, National Institutes of Health). Criteria of the apical foramen shapes were as follows. A root canal which two diameters were equal was categorized as round shape. Likewise, a root canal that one diameter is longer than another one by more than the radius was oval shape. Lastly, one with the diameter 2 times longer than that of another was flat shape.

### 4. Statistical analysis

For each cross section, the proportion ( $P$ ) between the longest ( $D_l$ ) and the shortest diameter ( $D_s$ ) was related to  $L_j$ . Correlation coefficient was calculated to identify the link between  $L_j$  and the apical foramen shape by Pearson's correlation. All data were summarized with means, maximum, minimum, standard deviation (SD) and analyzed correlation between  $L_j$  and the apical foramen shape using the software SPSS version 17.0 (SPSS Inc, Chicago, IL, USA).


## Results

The distance between the file tip and merging point of two joining canals (Lj), the longest diameter (DL), the shortest diameter (Ds), the proportion between DL and Ds (P) and the apical foramen shape (AFS) was shown in the Table 1. The apical foramen shape from this study was indentified as oval or flat (Figure 2). The average of Lj was 3.74 mm (Max, 9.30 mm; Min, 0.00 mm). The average of P, estimated by dividing the shortest diameter into longest diameter of the apical foramen, was 3.64 (Max, 24.93; Min,

**Table 1.** Lj, DL, Ds, P, and AFS of the specimens ( $n = 20$ )

	Lj (mm)	DL ( $\mu\text{m}$ )	Ds ( $\mu\text{m}$ )	P	AFS
1	9.30	507	393	1.29	Oval
2	5.44	393	329	1.19	Oval
3	2.86	513	301	1.70	Oval
4	2.94	451	317	1.42	Oval
5	3.56	849	336	2.53	Flat
6	3.64	864	493	1.75	Oval
7	1.94	699	256	2.73	Flat
8	2.88	404	348	1.16	Oval
9	6.16	399	337	1.18	Oval
10	0.00	1,861	75	24.93	Flat
11	1.32	780	132	5.91	Flat
12	4.14	1,279	345	3.70	Flat
13	1.82	1,028	500	2.06	Flat
14	3.38	1,48	221	6.69	Flat
15	5.26	451	284	1.59	Oval
16	2.80	908	349	2.60	Flat
17	4.20	607	521	1.16	Oval
18	0.28	525	152	3.46	Flat
19	8.70	391	227	1.72	Oval
20	4.24	1,623	395	4.11	Flat

Lj, the distance between the file tip and merging point of two joining canals; DL, the longest diameter; Ds, the shortest diameter; P, the proportion between DL and Ds; AFS, the apical foramen shape.



**Figure 2.** The apical foramen shape ( $\times 50$ ).

1.16) (Table 2).

The shape of the apical foramen was recognized depending on the P. When the P was smaller than 2.00, the apical foramen shape was close to oval. When the P was larger than 2.00, the apical foramen shape was close to flat. We hypothesized that if Lj is longer, P is close to 1.00. To prove this hypothesis, we calculated a correlation coefficient (Pearson's correlation). Table 3 showed the correlation coefficient of two variables. Since it was a negative figure (- 0.463) and statistically significant ( $p < 0.05$ ), there was inverse correlation between Lj and P. Therefore, the hypothesis was reasonable. Therefore, in condition of the type II root canal system, the longer Lj was, the smaller P became, and the shorter Lj was, the larger P became. Namely, the longer Lj was, the more oval contour of apical foramen became. Likewise, the shorter Lj was, the more flat contour of apical foramen became.

## Discussion

Successful endodontic treatments require the knowledge of the apical foramen shape and size. It is essential to determine the size of apical preparation. The observations of the apical foramen shape in the present study are in disagreement with previous findings. Martos *et al.* found that the most frequent root apex morphology and apical foramen in the maxillary and mandibular teeth was the round shape, and the oval shape was second.<sup>10</sup> But, major findings from these samples included demonstration of oval and flat shape of the apical foramen as same proportion (each 50%). In this study, only Type II root canal systems

**Table 2.** Comparison of the values between Lj and P

	No.	Minimum	Maximum	Mean	SD
Lj (mm)	20	0.00	9.30	3.74	2.39
P	20	1.16	24.93	3.64	5.25

Lj, the distance between the file tip and merging point of two joining canals; P, the proportion between DL and Ds; DL, the longest diameter; Ds, the shortest diameter.

**Table 3.** Statistical analysis of correlation between Lj and P

		P
	Pearson correlation	- 0.463 <sup>†</sup>
Lj	Sig. (2-tailed)	0.040
	No.	20

<sup>†</sup>Correlation is significant at the 0.05 level (2-tailed).

Lj, the distance between the file tip and merging point of two joining canals; P, the proportion between DL and Ds; DL, the longest diameter; Ds, the shortest diameter.

were examined, and we observed the oval and flat apical foramen shape. In this point of view, the mechanical canal enlargement might be insufficient for cleaning the type II root canal systems. Therefore, irrigations with chemical solution such as NaOCl, CHX, and EDTA were also very important for disinfection of the root canal.<sup>17,18</sup>

There is little controversy about the size of the apical preparation, and it is significant when considering the best possible debridement of infected root canals.<sup>19,20</sup> To determine the size of apical preparation in clinical situation, clinicians might use the two-dimensional radiographic image. This procedure reflects the clinical situation. Clinician might measure the distance between file tip and the merged point of joining two canals. Jou *et al.* suggested constant criteria to estimate the apical foramen shape.<sup>21</sup> As it becomes shorter, the flatter the apical foramen become. Therefore, the size of the apical preparation should be considered for mechanical debridement of infected root canals.

Although the present study clearly showed the negative correlation between Lj and P, it had several limitations, which need to be mentioned. The methodology used to calculate the morphology, the different ages of specimens, and the small number of groups investigated could cause slight variation.<sup>22</sup> Some specimens had curved root canals. Thus, it was difficult to measure the length of specimens. In addition, we had used the two-dimensional radiographic image to measure the file length. Unfortunately, the two-dimensional radiographic images did not reveal all anatomic characteristics. The different ages of specimens probably could interfere with the results of the anatomic evaluation. The reason is that the constant remodeling of the root apex occurred through cementum apposition and resorption.<sup>23</sup> There are few articles about the length of merged canal in type II root canal system. In this study, the average of Lj was 3.74 mm (Max, 9.30 mm; Min, 0.00 mm). Park *et al.* mentioned the length of merged canal in first molar mesiobuccal root of the maxilla, but the data is a little different from the findings of this study.<sup>24</sup> This difference may be caused by the type of teeth.

In this study, oval and flat apical foramen shapes were observed. It was difficult to measure the diameter of apical foramen in these types. And it was impossible to remove the debris with only mechanical instrumentation. Therefore, it needs to be considered that use of endodontic instruments do not touch the certain surface of the root canal system. Also, a better method of cleansing and disinfecting the root canal should be researched. The observations made here will provide a more precise understanding of the type II root canal system. In the next study, we need to classify the teeth according to a type. Correlation between the file length (Lj) and the proportion of diameter in each type of the teeth needs to be investigated in the future.

## Conclusions

There was an inverse correlation between Lj and P. As the distance between the file tip and merging point of two joining canals gets longer, the apical foramen becomes more oval shaped. Likewise, as it gets shorter, the apical foramen becomes more flat shaped. Therefore, clinician should consider the shape and size of apical foramen according to the length of merged canal during root canal instrumentation in type II root canal system.

Conflict of Interest: No potential conflict of interest relevant to this article was reported.

## References

- Baratto Filho F, Zaitter S, Haragushiku GA, de Campos EA, Abuabara A, Correr GM. Analysis of the internal anatomy of maxillary first molars by using different methods. *J Endod* 2009;35:337-342.
- Olson DG, Roberts S, Joyce AP, Collins DE, McPherson JC 3rd. Unevenness of the apical constriction in human maxillary central incisors. *J Endod* 2008;34:157-159.
- Hassanien EE, Hashem A, Chalfin H. Histomorphometric study of the root apex of mandibular premolar teeth: an attempt to correlate working length measured with electronic and radiograph methods to various anatomic positions in the apical portion of the canal. *J Endod* 2008;34:408-412.
- Vertucci FJ. Root canal anatomy of the human permanent teeth. *Oral Surg Oral Med Oral Pathol* 1984; 58:589-599.
- Olson AK, Goerig AC, Cavataio RE, Luciano J. The ability of the radiograph to determine the location of the apical foramen. *Int Endod J* 1991;24:28-35.
- Jafarzadeh H, Wu YN. The C-shaped root canal configuration: a review. *J Endod* 2007;33:517-523.
- Grande NM, Plotino G, Pecci R, Bedini R, Pameijer CH, Somma F. Micro-computerized tomographic analysis of radicular and canal morphology of premolars with long oval canals. *Oral Surg Oral Med Oral Pathol Oral Radiol Endod* 2008;106:70-76.
- Wu MK, Barkis D, Roris A, Wesselink PR. Does the first file to bind correspond to the diameter of the canal in the apical region? *Int Endod J* 2002;35:264-267.
- Wu MK, R'oris A, Barkis D, Wesselink PR. Prevalence and extent of long oval canals in the apical third. *Oral Surg Oral Med Oral Pathol Oral Radiol Endod* 2000;89:739-743.
- Martos J, Lubian C, Silveira LF, Suita de Castro LA, Ferrer Luque CM. Morphologic analysis of the root apex in human teeth. *J Endod* 2010;36:664-667.
- Wu MK, Wesselink PR. A primary observation on the preparation and obturation of oval canals. *Int Endod J*

- 2001;34:137-141.
12. Weiger R, Bartha T, Kalwitzki M, Löst C. A clinical method to determine the optimal apical preparation size. Part I. *Oral Surg Oral Med Oral Pathol Oral Radiol Endod* 2006;102:686-691.
  13. Jung IY, Seo MA, Fouad AF, Spångberg LS, Lee SJ, Kim HJ, Kum KY. Apical anatomy in mesial and mesiobuccal roots of permanent first molars. *J Endod* 2005;31:364-368.
  14. Weine FS. *Endodontic Therapy*. 5th ed. St Louis: Mosby; 1996. p243.
  15. Vertucci F, Seelig A, Gillis R. Root canal morphology of the human maxillary second premolar. *Oral Surg Oral Med Oral Pathol* 1974;38:456-464.
  16. Jeong EJ, Lee DK, Baek SY, Hwang HK. A comparison of master apical file size according to instrumentation in type II root canal. *J Korean Acad Conserv Dent* 2008; 33:435-442.
  17. Shin JS, Cho YB. Removal patterns of smear layer according to application temperature and time of EDTA. *J Korean Acad Conserv Dent* 2002;27:535-542.
  18. Lee JK, Park SH, Choi GW. Time-dependent effects of EDTA application on removal of smear layer in the root canal system. *J Korean Acad Conserv Dent* 2006;31:169-178.
  19. Senia ES. Canal diameter: the forgotten dimension. *Dent Today* 2001;20:58-62.
  20. Peters OA. Current challenges and concepts in the preparation of root canal systems: a review. *J Endod* 2004;30:559-567.
  21. Jou YT, Karabucak B, Levin J, Liu D. Endodontic working width: current concepts and techniques. *Dent Clin North Am* 2004;48:323-335.
  22. Blasković-Subat V, Marčić B, Sutalo J. Asymmetry of the root canal foramen. *Int Endod J* 1992;25:158-164.
  23. Oyama K, Motoyoshi M, Hirabayashi M, Hosoi K, Shimizu N. Effects of root morphology on stress distribution at the root apex. *Eur J Orthod* 2007;29:113-117.
  24. Park JW, Lee JK, Ha BH, Choi JH, Perinpanayagam H. Three-dimensional analysis of maxillary first molar mesiobuccal root canal configuration and curvature using micro-computed tomography. *Oral Surg Oral Med Oral Pathol Oral Radiol Endod* 2009;108:437-442.