

Angiographic embolization for hemorrhage control after dental implantation

Hee-Don Hwang¹, Jin-Wook Kim¹, Yong-Sun Kim², Dong-Hun Kang², Tae-Geon Kwon¹

¹Department of Oral and Maxillofacial Surgery, School of Dentistry, Kyungpook National University,

²Department of Diagnostic Radiology, School of Medicine, Kyungpook National University, Daegu, Korea

Abstract (J Korean Assoc Oral Maxillofac Surg 2013;39:27-30)

Dental implantation in the mandibular anterior region is considered a safe and reliable surgical procedure. On the other hand, several articles have reported that inadvertent hemorrhage of the sublingual artery can result in life-threatening airway obstruction. Surgical ligation under intubation or tracheostomy is the most widely used approach for controlling mouth floor bleeding in this highly vascular region. Nonetheless, surgically exploring the bleeding focus is difficult because of anatomical distortion followed by widespread edema and swelling. Since swelling of the mouth floor advances quickly, timely management is essential for favorable postoperative outcome. This paper reports a case of immediate hemorrhage control with angiographic embolization to perform rapid hemostasis before the ongoing swelling causes airway obstruction. Less invasive, angiographic embolization can prevent neurovascular damage during a surgical exploration of injured vascular structures on the mouth floor.

Key words: Angiography, Embolization, Sublingual artery, Implant, Hemorrhage

[paper submitted 2012. 3. 29 / revised 2012. 5. 22 / accepted 2012. 5. 25]

I. Introduction

Excessive hemorrhage in the floor of the mouth is a rare but potentially life-threatening complication of implant surgery because of possible airway interference. Since the lingual aspect of the mandibular anterior region is highly vascularized, this region can be injured through surgical damage to the lingual periosteum. Such will eventually lead to massive bleeding in the sublingual area or submental space, which in turn will result in massive swelling and hematoma formation within the first few hours of the injury. Life-threatening complication can occur when the hematoma critically affects airway patency. If the bleeding cannot be controlled by bimanual pressure on the lingual surface of the mandible, the main focus of bleeding should be identified by a surgical approach^{1,2}.

According to a review of 18 previously published cases of excessive mouth floor bleeding related to implant placement, 89% utilized intubation or tracheostomy during hemorrhage control³. When profuse bleeding occurs, the anatomical structure is usually distorted, and determining the precise point of bleeding is difficult. Therefore, establishing airway patency during a surgical examination would be necessary because hematoma formation can increase continuously until the end of bleeding control.

Before the advancement of severe hematoma formation that can obstruct the airway, rapid and immediate bleeding control can reduce the ongoing risk of airway obstruction. Therefore, angiographic embolization to perform rapid hemostasis before the ongoing swelling causes airway obstruction was considered in this case report. As far as we know, this is the first case of angiographic embolization of bleeding of floor of mouth in relation to implant placement.

Tae-Geon Kwon

Department of Oral and Maxillofacial Surgery, School of Dentistry, Kyungpook National University, 2175 Dalgubeol-daero, Jung-gu, Daegu 700-705, Korea
TEL: +82-53-600-7574 FAX: +82-53-426-5365
E-mail: kwondk@knu.ac.kr

© This is an open-access article distributed under the terms of the Creative Commons Attribution Non-Commercial License (<http://creativecommons.org/licenses/by-nc/3.0/>), which permits unrestricted non-commercial use, distribution, and reproduction in any medium, provided the original work is properly cited.

Copyright © 2013 The Korean Association of Oral and Maxillofacial Surgeons. All rights reserved.

II. Case Report

A 53-year-old man was transferred to our emergency clinic due to severe swelling and bleeding in the floor of the mouth during the placement of anterior mandibular implants. The patient had mild hypertension and controlled diabetes but

neither took anticoagulant agents nor had bleeding disorders. A local dental clinician extracted the mandibular left central and right lateral incisors that were connected with a bridge. Two implants were supposed to be placed into the extraction site. After a crestal incision on the mandibular anterior area, the lingual gingiva was reflected subperiosteally. When drilling was performed on the right lateral incisor extraction socket, the dentist felt that the drill had pierced through the lingual cortex of the anterior mandible. Although pressure had been applied to the bleeding area on the mouth floor immediately, the hemorrhage continued; the hematoma began to build up inside the floor of the patient's mouth, and the tongue started to be elevated gradually. The dentist transferred the patient

immediately to the hospital emergency room, which took one hour. The vital signs were stable, and sublingual packing was applied until the initiation of treatment.

Enhanced computerized tomogram (CT) was performed to analyze the bleeding focus.(Fig. 1) The results showed that the sublingual artery had been ruptured, discharging the hematoma surrounding it. Direct visualization and tying of the causative vessel were difficult under local anesthesia. Surgical access and ligation with general anesthesia were first considered. On the other hand, angiographic embolization was performed to achieve rapid hemostasis before the ongoing swelling results in airway obstruction. One and a half hours after the patient's arrival at our hospital,

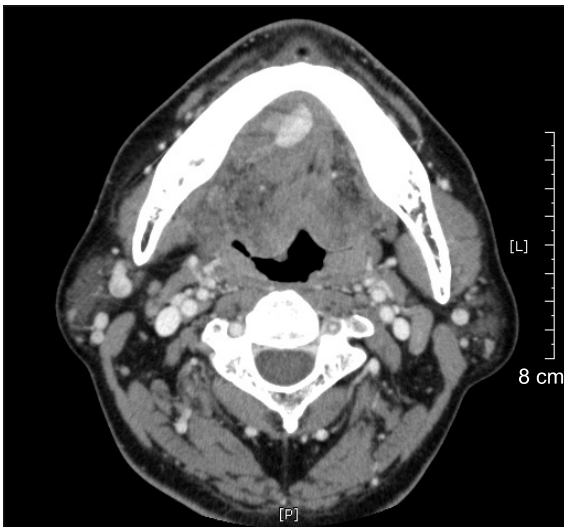


Fig. 1. Axial computed tomography image showing hemorrhage on the mandibular anterior lingual side.
Hee-Don Hwang et al: Angiographic embolization for hemorrhage control after dental implantation. J Korean Assoc Oral Maxillofac Surg 2013

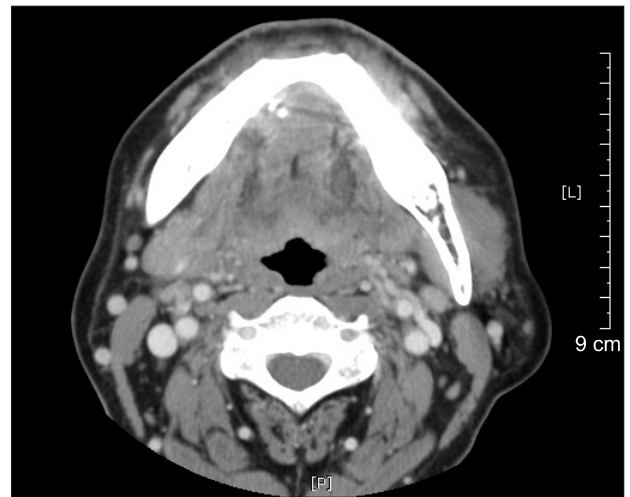


Fig. 3. Postoperative image showing successful bleeding control and no further bleeding.
Hee-Don Hwang et al: Angiographic embolization for hemorrhage control after dental implantation. J Korean Assoc Oral Maxillofac Surg 2013

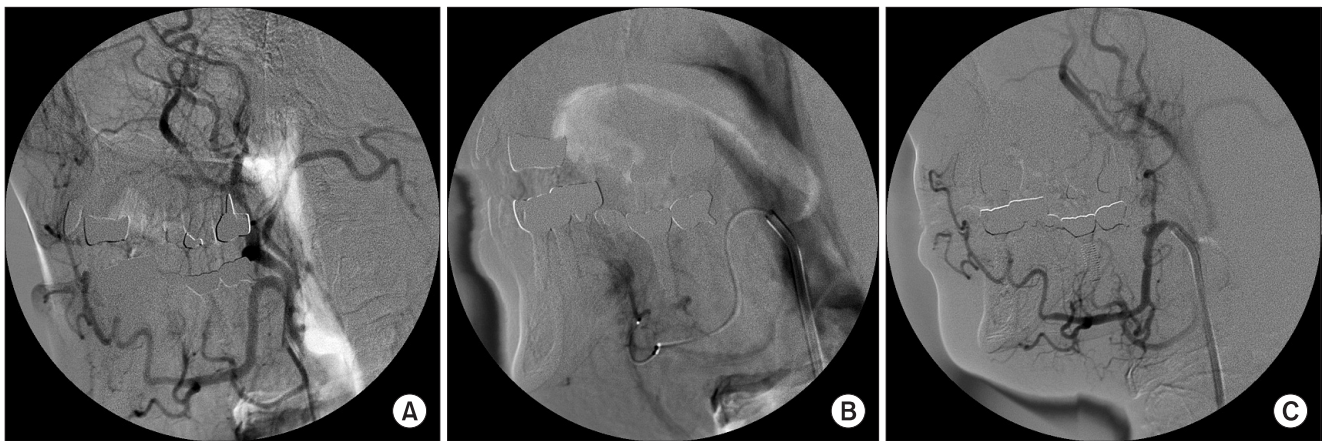


Fig. 2. The ruptured sublingual artery was observed by catheterization (A, B) and embolization performed using thrombogenic agent (glue) on the sublingual artery (C).
Hee-Don Hwang et al: Angiographic embolization for hemorrhage control after dental implantation. J Korean Assoc Oral Maxillofac Surg 2013

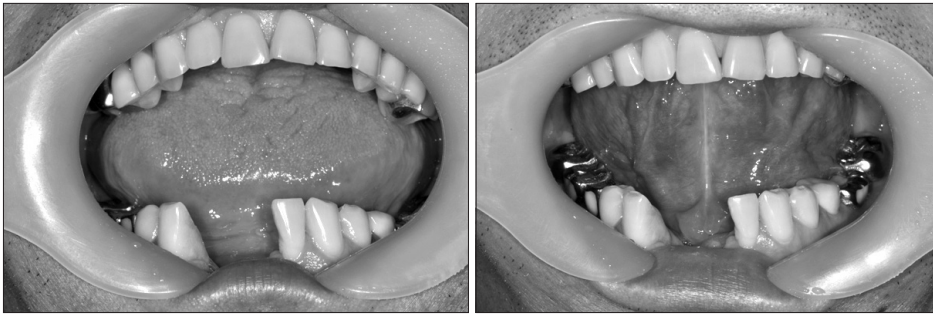

Fig. 4. Intraoral photograph of post-operative condition 1 week after embolization.

Hee-Don Hwang et al: Angiographic embolization for hemorrhage control after dental implantation. *J Korean Assoc Oral Maxillofac Surg* 2013

angiography was performed by interventional radiologists. After catheterization via the femoral artery, the ruptured sublingual artery was identified, and embolization was performed with thrombogenic agent (glue) on the injured artery. Hemostasis was confirmed radiographically and clinically. (Fig. 2) The next day, the patient was discharged without further complications. (Fig. 3) The patient's swelling and pain had almost subsided, and the healing process was uneventful during the 1st week of postoperative follow-up. (Fig. 4)

III. Discussion

Severe bleeding and large-sized hematoma in the floor of the mouth are normally related to the anatomical position of the sublingual artery, a branch of the lingual or submental artery that vascularizes the anterior mandible⁴. The mucosal branches of the sublingual artery run near the lateral incisor and supply vascularity to the mouth floor and gingival mucosa of the anterior mandible⁵. Vascular compromise due to surgical damage to the lingual periosteum is, in most cases, caused by unwanted perforation in the lingual cortical plate³. If adequate hemostasis had not been achieved in the sublingual area, the space between the lingual muscles and loose tissues of the bottom of the mouth are vulnerable to the spread of hemorrhage. Such hemorrhage causes rapid swelling and airway obstruction, which may require intubation or emergency tracheotomy.

To control hemorrhage, applying bimanual pressure to the floor of the mouth and lingual surface of the mandible should be the first procedure. Hemostatic packing agents should also be utilized. Some reports showed that compression from pooling blood and pressure from adjacent muscles and soft tissue caused self-limiting, tamponaded bleeding⁶. Nevertheless, if the bleeding fails to tamponade and turns into a dissecting hematoma, the main source of bleeding must be

identified through a surgical process. The vessels that cause such problems should be tied or clipped. Therefore, a surgical approach to controlling bleeding was considered a regular, initiative procedure. In addition to the aforesaid vascular structures, the submandibular ganglion, the lingual nerve, and the hypoglossal nerve lie around the lingual cortex of the mandible. Note, however, that this can be a very complicated task particularly in cases wherein the patient wakes up because of the distortion of anatomy occurring secondary to widespread edema, swelling, and vessel withdrawal⁷.

Some authors recommend external ligation if the bleeding cannot be controlled by a direct approach⁴. Other authors suggest that a direct exploration of the injured vessel is not always effective⁸. Ligation or compression of the wound was mainly reported, and there had been no report on endovascular embolization for bleeding in the mouth floor.

In this case, embolization of the damaged vessels using angiography was considered first. Endovascular intervention is used widely for vascular malformation in the head and neck area⁹. Angiographic embolization ensures shorter operative time and less blood loss. It is also less traumatic and non-invasive compared to other surgical approaches, because an already swollen bleeding site is difficult to access surgically and surgical dissection in traumatized operative fields may aggravate the hemorrhage. Furthermore, the treatment effect can be checked immediately through angiography after embolization, which can shorten the hospitalization period. This procedure is also cost-effective.

When the ligation of the injured vessels can be performed immediately, it is the best treatment option for bleeding in the mouth floor in relation to a surgical procedure. If the hemorrhage progresses, however, there is a fundamental limitation in the surgical exploration of the bleeding focus given the progressive aggravation of airway patency. Our case report showed that endovascular treatment for bleeding in the floor of the mouth is a fast, reliable method that can

be utilized as an alternative to the surgical exploration of hemorrhage under intubation or tracheostomy.

References

1. Darriba MA, Mendonça-Caridad JJ. Profuse bleeding and life-threatening airway obstruction after placement of mandibular dental implants. *J Oral Maxillofac Surg* 1997;55:1328-30.
2. Kalpidis CD, Konstantinidis AB. Critical hemorrhage in the floor of the mouth during implant placement in the first mandibular premolar position: a case report. *Implant Dent* 2005;14:117-24.
3. Dubois L, de Lange J, Baas E, Van Ingen J. Excessive bleeding in the floor of the mouth after endosseous implant placement: a report of two cases. *Int J Oral Maxillofac Surg* 2010;39:412-5.
4. Loukas M, Kinsella CR Jr, Kapos T, Tubbs RS, Ramachandra S. Anatomical variation in arterial supply of the mandible with special regard to implant placement. *Int J Oral Maxillofac Surg* 2008;37:367-71.
5. Bavitz JB, Harn SD, Homze EJ. Arterial supply to the floor of the mouth and lingual gingiva. *Oral Surg Oral Med Oral Pathol* 1994;77:232-5.
6. Goldstein BH. Acute dissecting hematoma: a complication of oral and maxillofacial surgery. *J Oral Surg* 1981;39:40-3.
7. Woo BM, Al-Bustani S, Ueeck BA. Floor of mouth haemorrhage and life-threatening airway obstruction during immediate implant placement in the anterior mandible. *Int J Oral Maxillofac Surg* 2006;35:961-4.
8. Niamtu J 3rd. Near-fatal airway obstruction after routine implant placement. *Oral Surg Oral Med Oral Pathol Oral Radiol Endod* 2001;92:597-600.
9. Bynoe RP, Kerwin AJ, Parker HH 3rd, Nottingham JM, Bell RM, Yost MJ, et al. Maxillofacial injuries and life-threatening hemorrhage: treatment with transcatheter arterial embolization. *J Trauma* 2003;55:74-9.