

A Case of Bilateral Giant Bullae in Young Adult

Ju-Hee Park, M.D.^{1,2}, Junghyun Kim, M.D.^{1,2}, Jung-Kyu Lee, M.D.^{1,2}, Soo Jung Kim, M.D.^{1,2}, Ae-Ra Lee, M.D.^{1,2}, Hyeon Jong Moon, M.D.² and Deog Kyeom Kim, M.D., Ph.D.³

¹Division of Pulmonary and Critical Care Medicine, Department of Internal Medicine and Lung Institute, Seoul National University College of Medicine, ²Department of Thoracic Surgery, ³Division of Pulmonary and Critical Care Medicine, Department of Internal Medicine, Seoul Metropolitan Government Seoul National University Boramae Medical Center, Seoul National University College of Medicine, Seoul, Korea

Giant bullae are large bullae occupying at least one-third of the hemithorax and surgical bullectomy is the treatment of choice. We report a case with symptomatic giant bullae which were resected successfully. A 35-year-old man presented with bilateral giant bullae that occupied almost the entire left hemithorax and a third of the right hemithorax. He was a current smoker with a 30 pack-year history and he presented with dyspnea on exertion. An elective surgical bullectomy was performed with video-assisted thoracoscopic surgery. The patient recovered without any adverse events and stayed well for 1 month after surgery.

Keywords: Blister; Pulmonary Emphysema

Introduction

Giant bullae are defined as large bullae occupying at least one third of the hemithorax¹. As the bullae do not take part in gas exchange and occupy space, they lead to impairment of ventilation and cause worsening dyspnea. In patients with a giant bulla, surgical bullectomy is the treatment of choice². In 1937, Burke¹ described first case of "vanishing lungs" in a 35-year-old man who experienced progressive dyspnea, re-

spiratory failure, and radiographic and pathologic findings of giant bullae, which occupied two-thirds of both hemithoraces. Since these description, scattered reports have been described in young male smokers³. We present a case of giant bullae occupying almost the entire left hemithorax and a third of right hemithorax in young male smoker who underwent surgical bullectomy.

Case Report

A 35-year-old man was referred to our clinic for an abnormal radiographic finding detected in screening chest X-ray. He was a current smoker with 30 pack-year and suffered from dyspnea on exertion (New York Heart Association functional class II). His chest radiography showed bilateral giant bullae occupying almost the entire left hemithorax and a third of right thorax (Figure 1A). The remaining part of the left lung was small and was compressed to the mediastinum. Pulmonary function tests revealed the following: forced vital capacity (FVC), 2.54 L (51% of predicted); forced expiratory volume in one second (FEV1), 1.57 L (40% of predicted); FEV1/FVC ratio, 0.63; diffusion capacity of the lung for carbon monoxide (DL_{CO}), 17.4 mL/mm Hg/min (73% of predicted), and DL_{CO}/alveolar volume (V_A), 5.13 [mL/mm Hg/min]/L (114% of pre-

Address for correspondence: Deog Kyeom Kim, M.D., Ph.D.

Department of Internal Medicine, Seoul Metropolitan Government Seoul National University Boramae Medical Center, 20 Boramae-ro 5-gil, Dongjak-gu, Seoul 156-707, Korea

Phone: 82-2-870-2228, **Fax:** 82-2-831-0714

E-mail: kimdkmd@snu.ac.kr

Received: Jul. 20, 2013

Revised: Aug. 23, 2013

Accepted: Aug. 26, 2013

©It is identical to the Creative Commons Attribution Non-Commercial License (<http://creativecommons.org/licenses/by-nc/3.0/>).

Copyright © 2013

The Korean Academy of Tuberculosis and Respiratory Diseases.

All rights reserved.

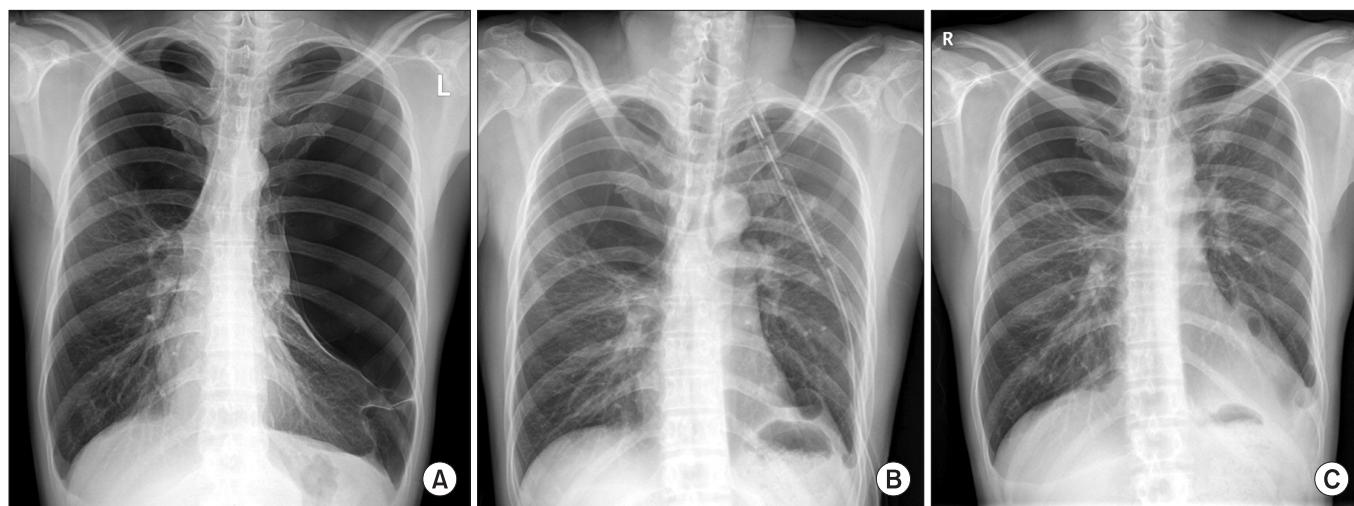


Figure 1. Representative chest radiographies. (A) Bilateral giant bullae occupying almost the entire left hemithorax and a third of the right thorax; preoperative period. (B) Postoperative period. (C) Follow-up 1 month after surgery.

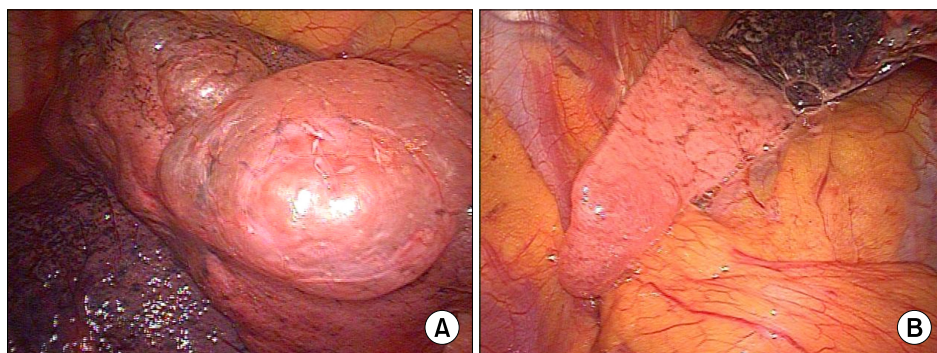


Figure 2. Intraoperative findings. (A) Giant bulla at the left upper lobe apex. (B) Atelectasis left lower lobe.

dicted). According to chest radiograph, giant bullae occupying nearly the entire left hemithorax with compressive atelectasis to the left lung, with the risk of impending pneumothorax. Considering limitation of his exercise capacity, elective surgical bullectomy by video-assisted thoracoscopic surgery (VATS) was performed. A left-sided, three-port technique was used to gain success to the thoracic cavity. About 28-cm-sized giant bulla originating from the apex of the left upper lobe was identified. In the surgical field, multiple bullae were detected simultaneously appeared at basal segment of the left lower lobe and the left lower lobe presented with complete atelectasis (Figure 2). Wedge resections were performed for an giant bulla at left upper lobe apex and bullae in left lower lobe basal segment using endoscopic stapling devices (Endo GIA 60). After surgical removal of bullae, one chest-tube was inserted and the collapsed left lung was re-expanded (Figure 1B). The patient was completely recovered without any event and was discharged. He remained well at the time of 1 month after surgery (Figure 1C).

Discussion

Giant bullae often occur in association with emphysema. It is difficult to estimate the natural history of these bullae accurately, but their enlargement causes worsening symptoms and mechanical disturbance of ventilation⁴. Although spontaneous regression of a bulla is occasionally observed along with the resolution of airway pathology such as an infection, mucus plugging or tumor⁵, giant bulla without complications is generally characterized by gradual enlargement over time. In patients with giant bullae, bullectomy is a rather safe technique that improves the early and late clinical and functional conditions².

Giant bullous emphysema appears to be a distinct clinical syndrome. The disease usually afflicts young male smokers and is characterized by large bullae in the upper lobes of the lungs⁶. In 1937, Burke¹ described first case of “vanishing lungs”. Since these descriptions, scattered reports have been described in young male smokers and this entity has been referred to as the vanishing lung syndrome, type 1 bullous disease, or pri-

mary bullous disease of the lung^{3,7}. Roberts et al.⁶ established the radiologic criteria for the syndromes as the presence of giant bullae in one or both upper lobes, occupying at least one third of the hemithorax and compressing surrounding normal lung parenchyma.

Its major complication is pneumothorax, which classically involves a history of acute deterioration in respiratory function associated with chest pain and also mimicking pneumothorax⁸. In this case, surgical bullectomy is the treatment of choice to allow the compressed lung to re-expand with a subsequent improvement of symptoms and lung function. The main factors of determine the postoperative outcome are the size of the bulla and the condition of the underlying lung. Almost normal DL_{CO}/V_A in this patients indicated that the remaining lungs seems not emphysematous and good prognostic marker for surgery.

We report a case of giant bullae, which has been removed with surgical resection. The patient was diagnosed to have a giant emphysematous bulla in the left lung on chest radiography. As far as we know, this case was the first report of giant bullae in young smoker in Korea. As shown in this report, a bullectomy via VATS could be a good option for treatment of giant bullae.

References

1. Burke RM. Vanishing lungs: a case report of bullous emphysema. *Radiology* 1937;28:367-71.
2. Palla A, Desideri M, Rossi G, Bardi G, Mazzantini D, Mussi A, et al. Elective surgery for giant bullous emphysema: a 5-year clinical and functional follow-up. *Chest* 2005;128:2043-50.
3. Stern EJ, Webb WR, Weinacker A, Muller NL. Idiopathic giant bullous emphysema (vanishing lung syndrome): imaging findings in nine patients. *AJR Am J Roentgenol* 1994;162:279-82.
4. Kayawake H, Chen F, Date H. Surgical resection of a giant emphysematous bulla occupying the entire hemithorax. *Eur J Cardiothorac Surg* 2013;43:e136-8.
5. Bradshaw DA, Murray KM, Amundson DE. Spontaneous regression of a giant pulmonary bulla. *Thorax* 1996;51:549-50.
6. Roberts L, Putman CE, Chen JT, Goodman LR, Ravin CE. Vanishing lung syndrome: upper lobe bullous pneumopathy. *Rev Interam Radiol* 1987;12:249-55.
7. Sharma N, Justaniah AM, Kanne JP, Gurney JW, Mohammed TL. Vanishing lung syndrome (giant bullous emphysema): CT findings in 7 patients and a literature review. *J Thorac Imaging* 2009;24:227-30.
8. Waseem M, Jones J, Brutus S, Muniyak J, Kapoor R, Gernsheimer J. Giant bulla mimicking pneumothorax. *J Emerg Med* 2005;29:155-8.