

# Extremely Increased Serum Carbohydrate Antigen 19-9 Levels Caused by New or Resistant Infections to Previous Antibiotics in Chronic Lung Diseases

Ji Young Shin, M.D.<sup>1</sup>, Su Jin Yoo, M.D.<sup>2</sup>, Bo Mi Park, M.D.<sup>2</sup>, Sung Su Jung, M.D.<sup>2</sup>, Ju Ock Kim, M.D.<sup>2</sup> and Jeong Eun Lee, M.D.<sup>2</sup>

<sup>1</sup>Department of Internal Medicine, Daejeon Veterans Hospital, Daejeon, <sup>2</sup>Department of Internal Medicine, Chungnam National University College of Medicine, Daejeon, Korea

In this paper, we describe 72-year-old female patient without evidence of malignant disease presented with significantly elevated serum carbohydrate antigen (CA) 19-9 levels by respiratory infections. She was diagnosed with respiratory infections due to *Mycobacterium avium* complex and *Pseudomonas aeruginosa*. The serum CA 19-9 levels remarkably increased (1,453–5,300 U/mL; reference range, <37 U/mL) by respiratory infection and abruptly decreased (357–534 U/mL) whenever infection was controlled by specific treatments. This case suggests that serum CA 19-9 levels may be used as a diagnostic marker to indicate new or resistant infections to previous antibiotics in chronic lung diseases without significant changes in chest X-ray findings.

**Keywords:** CA19-9 Antigen; Infection; Lung Neoplasms

## Introduction

Carbohydrate antigen (CA) 19-9 is a glycosphingolipid of the Lewis blood group that is a useful marker for epithelial-type gastrointestinal cancers<sup>1</sup>. In addition, moderately increased serum CA 19-9 levels can be found in 15–36% of patients with benign conditions such as pancreatic, liver, biliary

diseases, and benign hydronephrosis.

Recently, several reports have described elevated serum CA 19-9 levels in patients with non-malignant respiratory diseases. However, this case is exceptional to observe extremely high serum CA 19-9 levels (>5,000 U/mL) in benign lung disease patients without significant changes in chest X-ray finding. Furthermore, this case suggests that the serum CA 19-9 levels have potential utility as a diagnostic marker for new or resistant infection to previous antibiotics in chronic lung disease.

## Case Report

In May 2010, a 72-year-old female came to Chungnam National University Hospital for cough and sputum. She had been diagnosed with bronchiectasis 6 years before. Chest auscultation revealed a moderate inspiratory crackle sound in both lower lung fields. Her blood examination showed a hemoglobin level of 11.2 g/dL, white blood cell count of  $7.9 \times 10^3$ /mL, and platelet count of  $427 \times 10^3$ / $\mu$ L and C-reactive protein of 4.3 mg/dL. Electrolytes, measures of renal function, and liver enzymes were within normal limits. On that occasion,

**Address for correspondence: Jeong Eun Lee, M.D.**

Department of Internal Medicine, Chungnam National University Hospital, 282 Munhwa-ro, Jung-gu, Daejeon 301-721, Korea

**Phone:** 82-42-280-8035, **Fax:** 82-42-257-5753

**E-mail:** vov-x@hanmail.net

**Received:** Feb. 26, 2013

**Revised:** May 14, 2013

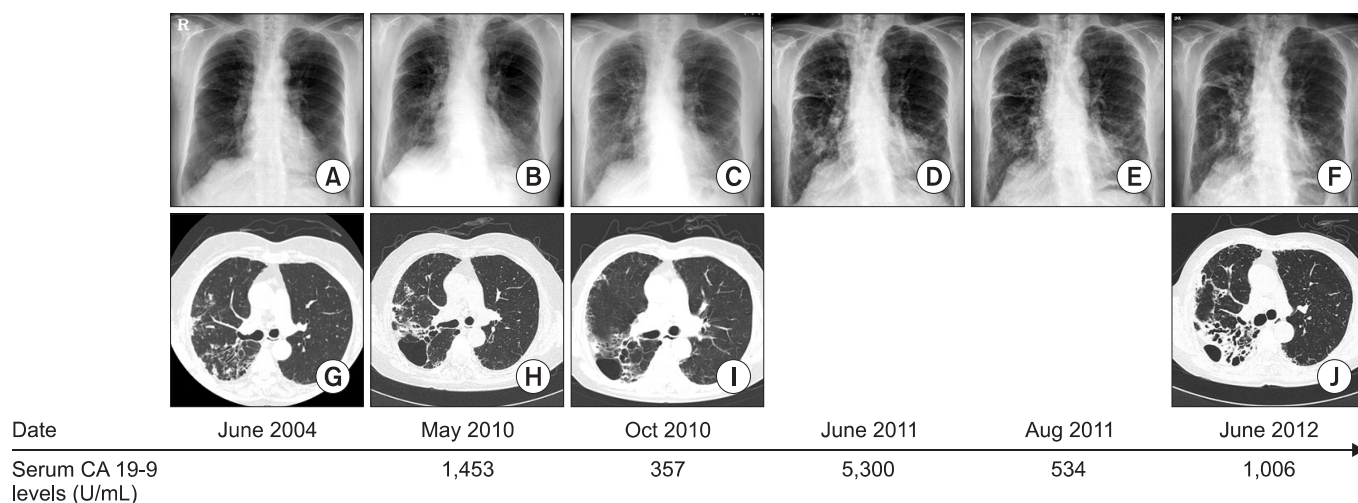
**Accepted:** Jun. 11, 2013

©It is identical to the Creative Commons Attribution Non-Commercial License (<http://creativecommons.org/licenses/by-nc/3.0/>).

Copyright © 2013

The Korean Academy of Tuberculosis and Respiratory Diseases.

All rights reserved.

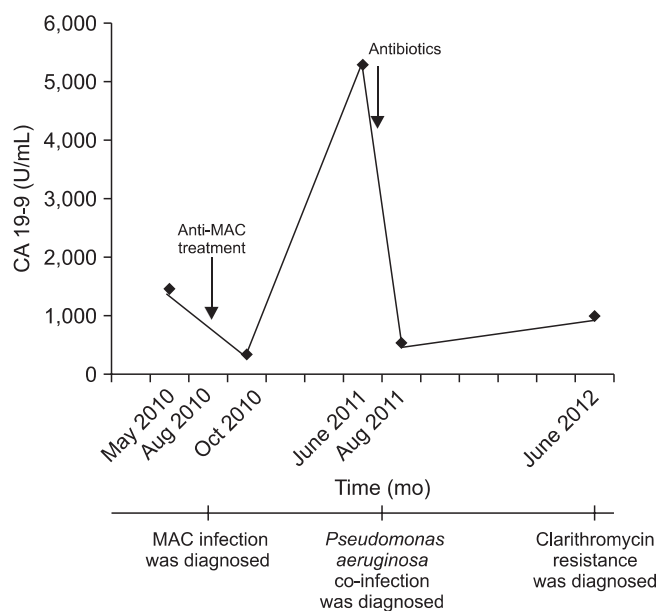


**Figure 1.** Summary from the initial visit to the recent follow-up. (A–F) Chest radiograph showed no significant interval changes. (G–J) Chest computed tomography (CT) findings. (H) In May 2010, Chest CT revealed nodularities on both lower lung fields. (I) In October 2010, chest CT revealed decreased nodularities. (J) In June 2012, chest CT revealed aggravated bilateral nodularities. CA 19-9, carbohydrate antigen 19-9.

increased serum levels of CA 19-9 were noted (range, 1,453 U/mL; reference range, <37 U/mL). An abdominal computed tomography (CT) scan, esophagogastroduodenoscopy and colonoscopy were performed and showed no abnormal findings. Compared to 6 years before, chest radiography revealed subtle increased interstitial densities and CT revealed aggravated bronchial dilatation surrounded by small nodules on both lung fields (Figure 1). With bronchoscopy, moderate amount of mucinous sputum was found and *Mycobacterium intracellulare* was identified in bronchoscopic washing. In August 2010, anti-*Mycobacterium avium* complex (MAC) treatment was initiated with clarithromycin (1 g/day), rifampicin (450 mg/day), ethambutol (800 mg/day). Anti-MAC treatment was continued and her symptoms including cough and sputum were gradually improved. In October 2010, the serum CA 19-9 levels decreased to 357 U/mL (Figure 2) and the chest CT revealed decreased nodularities (Figure 1).

In June 2011, she was re-admitted for increased cough and sputum without any other respiratory symptom including fever or dyspnea. The simple chest radiograph showed mild increased opacities at especially right lower lobe (Figure 1). Laboratory tests determined that the serum CA 19-9 levels increased to 5,300 U/mL (Figure 2). Large amount of sputum was drained from right upper lobe in bronchoscopy. The sputum CA 19-9 levels were 148 U/mL and sputum cultures from bronchialveolar lavage fluid (BALF) were positive for *Pseudomonas aeruginosa*. After 2 weeks of antibiotic treatment with an anti-pseudomonal agent, her clinical symptoms were improved and she was discharged. In August 2011, the serum CA 19-9 levels decreased to 534 U/mL (Figure 2).

In June 2012, she was re-admitted for increased sputum unaccompanied significant chest radiographic changes, and



**Figure 2.** Serum carbohydrate antigen 19-9 (CA 19-9) levels (U/mL). MAC, *Mycobacterium avium* complex.

the CT scan revealed aggravated bilateral nodularities (Figure 1). At that time, the serum CA 19-9 levels were 1,006 U/mL (Figure 2), an acid-fast bacteria stain of the sputum was positive, and polymerase chain reaction for *M. tuberculosis* was negative. Clarithromycin resistance was confirmed by drug susceptibility test and she was transferred to another hospital.

## Discussion

We report the observation of markedly increased serum CA 19-9 levels in bronchiectasis patient presenting with MAC infection and bacterial infection. With resolution of the infection, the serum CA 19-9 levels decreased significantly.

The mechanisms increasing serum CA 19-9 levels in non-malignant disease are not clear, but there are a few possible explanations. Yokoyama et al.<sup>2</sup> confirmed elevated levels of CA 19-9 in bronchial epithelium-derived serum and BALF by immunohistochemical analysis. CA 19-9 is selectively expressed in regenerating epithelial cells in patients with idiopathic interstitial pneumonia and diffuse panbronchiolitis (DPB), regardless of the etiology. Most of the bronchial mucus obtained during general anesthesia from patients without pulmonary diseases contains high levels of CA 19-9<sup>3</sup>. Thus, destruction of normal lung tissue could lead elevated serum CA 19-9 levels.

A few investigators have reported elevated serum CA 19-9 levels in patients with non-malignant respiratory diseases, such as idiopathic interstitial pneumonia and DPB, bronchiectasis, collagen disease-associated pulmonary fibrosis and tuberculosis, without malignant disease in any sites<sup>4,5</sup>. Kim et al.<sup>6</sup> reported that the prevalence of pulmonary radiographic abnormalities was higher in participants with increased serum CA 19-9 levels compared to those with normal serum CA 19-9 levels (57.1% vs. 26.9%,  $p=0.001$ ) and sequelae of pulmonary tuberculosis were the most frequent abnormal findings. The serum CA 19-9 levels in increased group were  $78\pm 107$  U/mL. Yamazaki et al.<sup>7</sup> reported about markers indicating deterioration of pulmonary *Mycobacterium avium-intracellulare* infection. The serum CA 19-9 levels of the deteriorated group ( $96.1\pm 12.1$  U/mL) were higher than those of the not-deteriorated group ( $19.2\pm 31.8$  IU/mL). Watanabe et al.<sup>8</sup> reported the serum CA 19-9 levels were higher in the MAC group than in the tuberculosis group ( $72.3\pm 35.8$  U/mL vs.  $24.3\pm 3.8$  U/mL,  $p=0.013$ ).

However, a very high serum CA 19-9 levels ( $>1,000$  U/mL) as shown in this case have rarely been observed in patients with nonmalignant diseases. Kodama et al.<sup>9</sup> reported that the serum CA 19-9 levels were elevated ( $>37$  U/mL) in 42 of the 231 patients (18.2%) with nonmalignant respiratory diseases. The 50th, 75th, 90th, and 95th percentile serum CA 19-9 levels were 16, 29, 73, and 136 U/mL, respectively. Mirizzi's syndrome and acute cholangitis are the usual definitive diagnoses of patients with these extreme values<sup>10,11</sup>.

In this case, serum CA 19-9 levels were increased repeatedly due to combined infection caused by MAC and bacterium. Our case indicates that serum CA 19-9 levels can be used as a biomarker for the early detection of exacerbated infections in patients with previously elevated serum CA 19-9 levels. Serial

changes in serum CA 19-9 levels may be clinically useful as a biomarker to detect combined infection or resistant infection to previous antibiotics in patients with underlying chronic lung disease having uncertainty to identify changes in chest radiography.

## References

1. Plebani M, Basso D, Panozzo MP, Fogar P, Del Favero G, Naccarato R. Tumor markers in the diagnosis, monitoring and therapy of pancreatic cancer: state of the art. *Int J Biol Markers* 1995;10:189-99.
2. Yokoyama T, Ikedou Y, Kido F, Tanoue S, Tashiro K, Ninomiya H, et al. A study of sialylated carbohydrate antigen in patients with benign bronchopulmonary disease. *Nihon Kokyuki Gakkai Zasshi* 1998;36:851-6.
3. Matsuoka Y, Endo K, Kawamura Y, Yoshida T, Saga T, Watanabe Y, et al. Normal bronchial mucus contains high levels of cancer-associated antigens, CA125, CA19-9, and carcinoembryonic antigen. *Cancer* 1990;65:506-10.
4. Shimizu Y, Hamada T, Tanaka Y, Sasaki A, Nemoto T. Colocalization of CA19-9 and KL-6 to epithelial cells in dilated bronchioles in a patient with idiopathic pulmonary fibrosis complicated by diffuse alveolar damage. *Respirology* 2002;7:281-4.
5. Mukae H, Hirota M, Kohno S, Komori K, Fukushima K, Hiratani K, et al. Elevation of tumor-associated carbohydrate antigens in patients with diffuse panbronchiolitis. *Am Rev Respir Dis* 1993;148:744-51.
6. Kim HR, Lee CH, Kim YW, Han SK, Shim YS, Yim JJ. Increased CA 19-9 level in patients without malignant disease. *Clin Chem Lab Med* 2009;47:750-4.
7. Yamazaki Y, Kubo K, Takamizawa A, Yamamoto H, Honda T, Sone S. Markers indicating deterioration of pulmonary *Mycobacterium avium-intracellulare* infection. *Am J Respir Crit Care Med* 1999;160:1851-5.
8. Watanabe K, Fujimura M, Kasahara K, Yasui M, Myou S, Watanabe A, et al. Characteristics of pulmonary *Mycobacterium avium-intracellulare* complex (MAC) infection in comparison with those of tuberculosis. *Respir Med* 2003;97:654-9.
9. Kodama T, Satoh H, Ishikawa H, Ohtsuka M. Serum levels of CA19-9 in patients with nonmalignant respiratory diseases. *J Clin Lab Anal* 2007;21:103-6.
10. Sheen-Chen SM, Sun CK, Liu YW, Eng HL, Ko SE, Kuo CH. Extremely elevated CA19-9 in acute cholangitis. *Dig Dis Sci* 2007;52:3140-2.
11. Lin CL, Changchien CS, Chen YS. Mirizzi's syndrome with a high CA19-9 level mimicking cholangiocarcinoma. *Am J Gastroenterol* 1997;92:2309-10.