

## Acute Urinary Retention in a 47-month-old Girl Caused by the Giant Fecaloma

Ji Sook Park, Tae-Jin Park\*, Jung Seok Hwa†, Ji-Hyun Seo, Chan-Hoo Park and Hee-Shang Youn

Departments of Pediatrics, \*General Surgery and †Urology, Gyeongsang Institute of Health Sciences, Gyeongsang National University School of Medicine, Jinju, Korea

We present a case of a 47-month-old female suffering from acute urinary bladder neck obstruction and bilateral hydronephrosis secondary to a fecaloma. Fecaloma is defined as an accumulation of inspissated feces in the colon or rectum giving the appearance of an abdominal mass. A fecaloma can be developed by diverse causes and the causes of the fecaloma in this case were septum reformation after the Duhamel procedure and long-term constipation. Chronic constipation is very common at outpatient clinic. However, acute urinary retention and voiding difficulty caused by fecaloma in the giant Duhamel pouch has never been reported in Korea. We would like to present our case with acute urinary retention due to a fecaloma and suggest that fecaloma might be considered as one of the causes for acute urinary retention, especially in cases with previous Duhamel operation for repair of Hirschsprung disease. (**Pediatr Gastroenterol Hepatol Nutr** 2013; 16: 200 ~ 205)

**Key Words:** Urinary retention, Hirschsprung disease, Fecaloma

### INTRODUCTION

Acute urinary retention is infrequent in children. The most common causes of acute urinary retention of children are neurological process, severe voiding dysfunction, urinary tract infection, adverse drug effects and constipation [1]. Acute urinary retention in constipation is caused by anterior displacement of the bladder base and trigone by the stool-filled rectum, impairing urethrovesical and sacral reflex function [2]. Fecaloma is an accumulation of inspissated

feces in the colon or rectum, giving the appearance of an abdominal tumor which is much harder than a fecal impaction [3]. Herein, we report a 47-month-old girl presented with acute urinary retention caused by a giant fecaloma in the reformed septum after Duhamel procedure for Hirschsprung disease.

### CASE REPORT

Patient: A 47-month-old female

Chief complaints: Voiding difficulty and urinary

Received : August 25, 2013, Revised : September 6, 2013, Accepted : September 15, 2013

**Corresponding author:** Ji-Hyun Seo, Department of Pediatrics, Gyeongsang National University Hospital, 79, Gangnam-ro, Jinju 660-702, Korea. Tel:+82-55-750-8731, Fax: +82-55-752-9339, E-mail: seozee@gnu.ac.kr

Copyright © 2013 by The Korean Society of Pediatric Gastroenterology, Hepatology and Nutrition

This is an open-access article distributed under the terms of the Creative Commons Attribution Non-Commercial License (<http://creativecommons.org/licenses/by-nc/3.0/>) which permits unrestricted non-commercial use, distribution, and reproduction in any medium, provided the original work is properly cited.

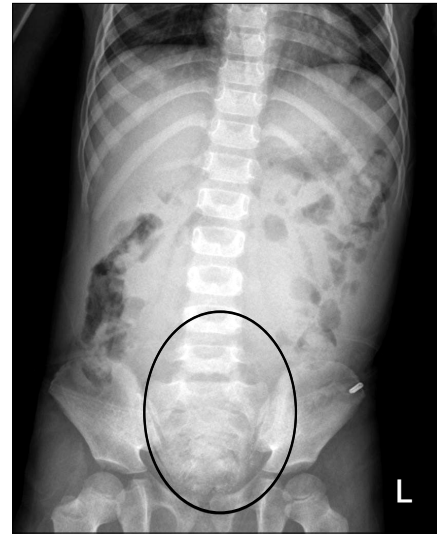incontinence

**Past medical history:** The patient was born full-term with a birth weight of 2.4 kg. At the age of 2 weeks, she was diagnosed with Hirschsprung disease and underwent the Duhamel operation. At that time, a ganglion cell was noted at the proximal sigmoid. After the operation, she was able to evacuate the bowels well until 6 months of age and she stopped visiting the outpatient clinic. She has a history of constipation of over 1 year. Constipation had been managed with oral lactulose and enema using glycerin at a nearby hospital over 1 year when she complained abdominal pain, agitation and holding her stools with 3- or 4-day interval. After enema, sausage-shaped stools were frequently observed. Her mother could not remember the exact characters of stool. There was no abnormal and unusual feeding history or urinary pattern before admission.

**Present illness:** The patient was transferred to our hospital due to acute urinary obstruction. One week ago, diffuse lower abdominal pain developed which was managed at a local clinic with medicine for constipation. However, abdominal pain persisted. One day before admission, abdominal distension and voiding difficulty developed.

**Physical examination:** On initial evaluation the patient had a blood pressure of 110/70 mmHg, a pulse rate of 96 beats/min, a respiratory rate of 24 breaths/min, a body temperature of 36.5°C with a body weight of 14.5 kg (the 50-75 percentile) and a height 99.9 cm (>the 97 percentile). She was irritable because she could not pass urine despite the feeling of micturition. Her abdomen was distended, and focal tenderness was present at the lower quadrant. Auscultation revealed lower than normal bowel sounds. The location of the anal orifice on the perineal area and anal tone were both physiologic. No abnormal dimple or skin lesion on her sacral area was observed and her neurologic examination was physiologic and normal. Fecal materials were palpable on digital rectal examination.

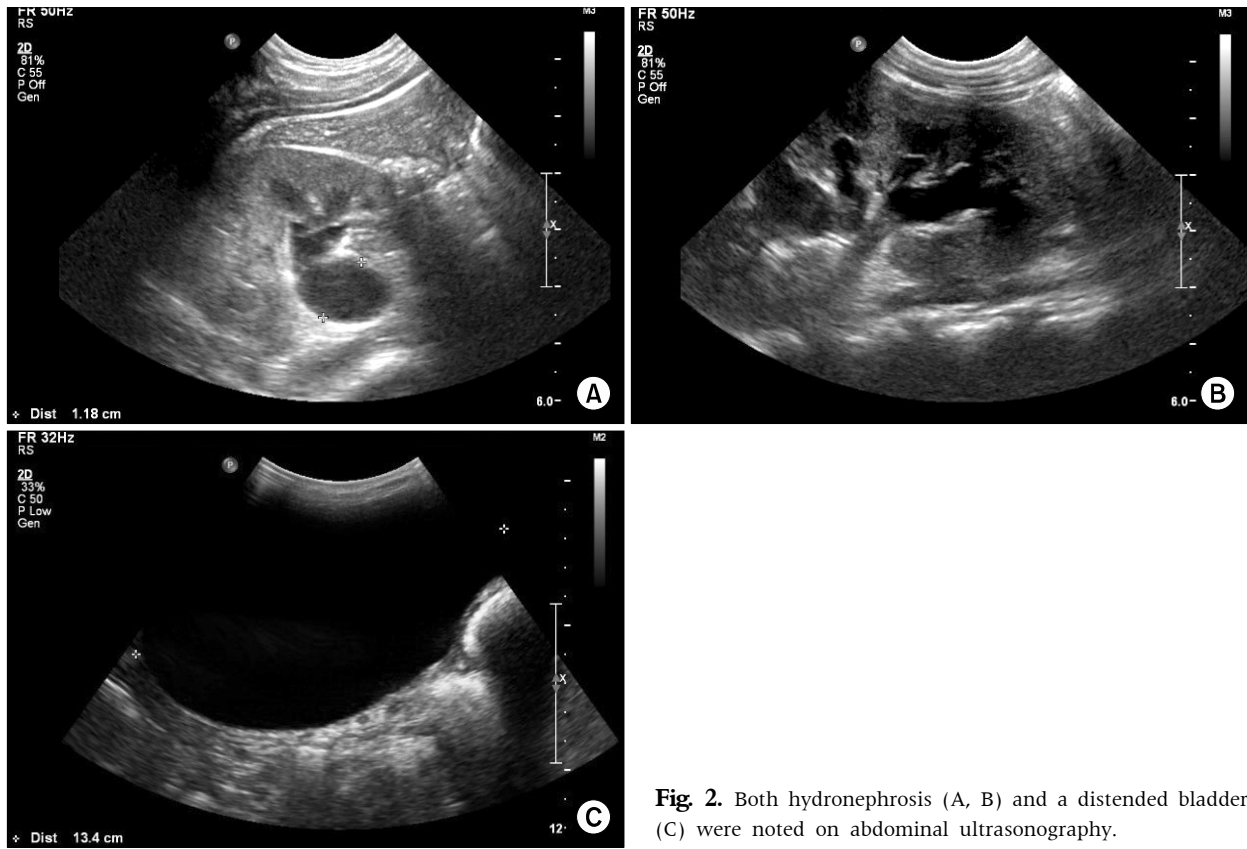
**Radiologic and laboratory findings:** Abundant fecal materials were observed on abdominal X-ray (Fig. 1), and ultrasonography (USG) of the abdomen



**Fig. 1.** Simple abdominal X-ray shows faint rectal gas and a large amount of fecal materials in the distal colon (circle).

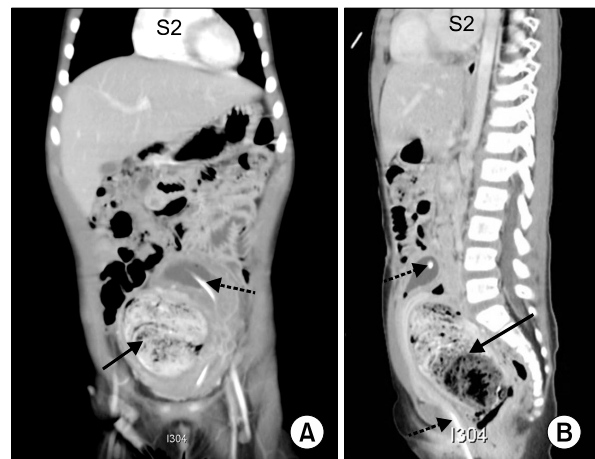
revealed a distended bladder with a thin bladder wall and both hydronephrosis of grade III (Fig. 2). Hematological examinations and blood chemistries were as follows: a hemoglobin level of 13.0 g/dL, a total white cell count of  $5.9 \times 10^9/L$ , a platelet count of  $357 \times 10^9/L$  and granulocyte and lymphocyte levels of 41.5% and 46.1%, respectively; A serum calcium level of 9.7 mg/dL (8.6-10.2), a magnesium level of 1.2 mg/dL (1.5-2.3), a sodium level of 144.1 mmol/L (135-145), a potassium level of 3.6 mmol/L (3.3-5.1) and a chloride level of 104.6 mmol/L (98-110). Her blood urea nitrogen, creatinine, hepatic transaminase and C-reactive protein levels were normal. Urinalysis collected via a catheter was normal. Thyroid function test was not checked. Sigmoidoscopy could not be performed to her because of a large amount of feces in her distal colon despite repeated glycerin enema and digital evacuation.

**Hospital course:** After urinary catheterization, 720 mL of urine was drained and abdominal pain and distension was improved. However, urinary obstruction persisted and urinary catheterization was kept continuously. On day 3 after admission, voiding difficulty persisted despite loose stool passage after repeated glycerine enema. For ruled out the abdominal mass, whole-abdominal computed tomography

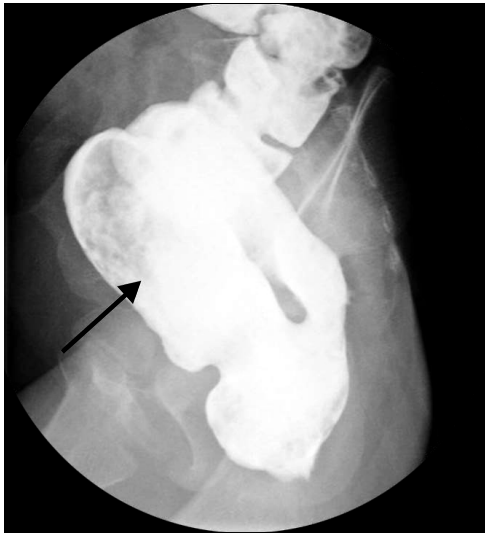

**Fig. 2.** Both hydronephrosis (A, B) and a distended bladder (C) were noted on abdominal ultrasonography.

(CT) was performed and showed a large fecaloma in the sigmoid colon and a displaced bladder (Fig. 3). The coronal image of the CT showed that the distal part of the colon was markedly dilated and contained heterogeneous materials consisting of impacted feces. The markedly dilated distal colon was suspected as Duhamel pouch. The bladder neck was displaced into the upper abdomen because of the large fecaloma-filled pouch. After repeated glycerin enemas and digital evacuations, spontaneous urination was noted on day 5. USG revealed a normal sized bladder and improved both hydronephrosis. However, she could not evacuate bowels sufficiently by herself. We could palpate a membranous tissue in her rectum at the time of digital evacuation. On day 7, a colon study revealed a giant Duhamel pouch filled with fecal materials without a definitive the membranous tissue in her rectum (Fig. 4). We decided to perform an operation because she had a



**Fig. 3.** Coronal (A) and sagittal views (B) of whole abdominal computed tomography show that the distal part of the colon is markedly dilated and contains heterogeneous materials consisting of impacted feces (lined arrows). The markedly dilated distal colon was suspected as Duhamel's pouch. The upward displaced bladder and internal Foley catheter are noted (dotted arrows).



**Fig. 4.** The giant Duhamel pouch with fecal materials (arrow) without stenosis of the anastomotic site was noted on the colon study.

giant Duhamel pouch, an unidentified membranous tissue and to perform a full-thickness rectal biopsy. Two weeks later, operation was done after sufficient evacuation of the feces in her rectum. A septum was noted in Duhamel pouch, which ran transverse direction in her rectum on the operative findings. Post-Duhamel septum revision was performed. Histopathologic findings of the full-thickness rectal biopsies showed a ganglion cell in the rectum. Since the operation, she has been visiting our outpatient clinic regularly. She has been free of defecation and urination difficulties without the need for medicine.

## DISCUSSION

Common complications after repair of Hirschsprung disease are obstruction, fecal incontinence and enterocolitis. The outcome after Swensen, Duhamel and Soave procedures for Hirschsprung disease is similar. However, the Duhamel procedure is known to have less risk of overall complications except the risk of postoperative enterocolitis. Constipation and fecal impactions as obstructive symptoms are common complications of Duhamel operation and mega Duhamel pouch [4] as in this case.

When obstructive symptoms after repair of Hirschsprung disease are present, the possibility of anatomic and functional problems should be considered. In our case, stenosis of the anastomotic site and anus were ruled out by digital rectal examination and colon study. In order to differentiate between acquired and secondary aganglionosis following the pull-through procedure and neuronal intestinal dysplasia, a full-thickness rectal biopsy was performed during operation, which revealed a normal appearing-ganglion cell in her remaining colon. Persistent internal anal sphincter (IAS) dysfunction is another cause of obstructive symptoms after repair of Hirschsprung disease and is related to specific abnormalities in IAS innervations [5]. The patient might have had IAS dysfunction but her obstructive symptoms were improved after post-Duhamel septum revision without myectomy or sphincter-diving procedure. Even though her obstructive symptoms were improved, regular follow-up and anorectal manometry are warranted.

There could be several causes for reoperation after the Duhamel procedure such as bleeding, leakage and stenosis [6,7]. Septum formation after the Duhamel procedure is one of the stenotic causes for reoperation [6,7]. Most patients with fecaloma including our case have a long history of constipation. In our patient, the septum might have aggravated fecaloma formation, causing medicine to be less effective.

Causes of fecaloma have been described in association with Hirschsprung disease [8], Chagas disease [9], both inflammatory and neoplastic disease, and in patients suffering with chronic constipation [3]. Fecaloma was the presenting symptom of Hirschsprung disease in a 5 month-old male in China [8]. Inversely, the megacolon was the result of fecaloma in an older child [10] and an adult [11]. In addition, fecaloma formation is the most common complication after the Duhamel operation [5]. However, no child with Hirschsprung disease has shown clinical urologic problems after rectosigmoidectomy and Duhamel-type pull-through procedure [12]. Constipation accounts for 25% of the visits to the pediatric gastroenterologist [13] and is commonly associated

with an overactive bladder rather than acute urinary retention [8]. Urinary symptoms with constipation are urge incontinence, urinary tract infection, frequency, nocturia, holding maneuvers, and enuresis [14]. Hydronephrosis with a large fecal impaction has been reported [15-19] but acute urinary obstruction is not common in children. In our case, the massively distended Duhamel pouch and rectum filled her pelvic cavity and pressed up against the posterior aspect of the bladder and its neck. Fecaloma and secondary acute urinary retention were due to delayed detection of the septum because of discontinuation of visits to the outpatient clinic soon after the first surgery.

Fecalomas can be extracted using laxatives, enemas and rectal evacuation while others require treatment with colostomy [20]. In our case, fecaloma was not completely resolved by repeated digital evacuation and laxatives because of the rectal septum. Thus, she was required to undergo reoperation.

Remaining rectal septum is one of the causes for the reoperation of Hirschsprung disease. In early detection of the septum, there might be no difficult procedure and no need to suffer from longstanding constipation secondary to the septum, in our case. This present case suggests that regular follow-up for evaluation of complications is important for patient who underwent the Duhamel operation.

Moreover, fecaloma should be considered in the differential diagnosis of patients with acute urinary retention especially in those a long history of constipation or the Duhamel operation.

## REFERENCES

- Gatti JM, Perez-Brayfield M, Kirsch AJ, Smith EA, Massad HC, Broecker BH. Acute urinary retention in children. *J Urol* 2001;165:918-21.
- Kerrigan DD, Lucas MG, Sun WM, Donnelly TC, Read NW. Idiopathic constipation associated with impaired urethrovesical and sacral reflex function. *Br J Surg* 1989;76:748-51.
- Garisto JD, Campillo L, Edwards E, Harbour M, Ermocilla R. Giant fecaloma in a 12-year-old-boy: a case report. *Cases J* 2009;2:127.
- Chatoorgoon K, Pena A, Lawal TA, Levitt M. The problematic Duhamel pouch in Hirschsprung's disease: manifestations and treatment. *Eur J Pediatr Surg* 2011;21:366-9.
- Nurko S. Management of surgical patients. In: Walker WA, Goulet O, Kleinman RE, Sherman PM, Shneider B, Sanderson IR, eds. *Pathophysiology, diagnosis, management*. 4th ed. Ontario: BC Decker Inc., 2004: 2119-26.
- Weber TR, Fortuna RS, Silen ML, Dillon PA. Reoperation for Hirschsprung's disease. *J Pediatr Surg* 1999;34:153-7.
- Langer JC. Repeat pull-through surgery for complicated Hirschsprung's disease: indications, techniques, and results. *J Pediatr Surg* 1999;34:1136-41.
- Wang KR, Huang FY, Chang PY, Chen CC. Congenital megacolon presented as fecaloma and urinary tract infection. Report of one case. *Zhonghua Min Guo Xiao Er Ke Yi Xue Hui Za Zhi* 1989;30:437-41.
- Araki T, Miki C, Yoshiyama S, Toiyama Y, Sakamoto N, Kusunoki M. Total proctocolectomy and ileal J-pouch anal anastomosis for chagasic megacolon with fecaloma: report of a case. *Surg Today* 2006;36:277-9.
- Ribas Y, Bargalló J, Lamas S, Aguilar F. Idiopathic sigmoid megacolon with fecal impaction and giant calcified fecaloma. *Am Surg* 2013;79:E96-7.
- Yucel AF, Akdogan RA, Gucer H. A giant abdominal mass: fecaloma. *Clin Gastroenterol Hepatol* 2012;10:e9-10.
- Boemers TM, Bax NM, Van GJ. The effect of resectosigmoidectomy and Duhamel-type pull-through procedure on lower urinary tract function in children with Hirschsprung's disease. *J Pediatr Surg* 2001;36:453-6.
- Loening-baucke V. Constipation in early childhood: patient characteristics, treatment, and longterm follow up. *Gut* 1993;34:1400-4.
- Veiga ML, Lordêlo P, Farias T, Barroso C, Bonfim J, Barroso U Jr. Constipation in children with isolated overactive bladder. *J Pediatr Urol* 2013. [Epub ahead of print]
- Oestmann A. Hydronephrosis in impacted feces. *Schweiz Med Wochenschr* 1997;127:1925.
- Delaere KP, Braam PF, Debruyne FM. Unilateral hydroureteronephrosis resolved by fecal disimpaction in a patient with neurogenic bladder. *Acta Urol Belg* 1983;51:289-92.
- Knobel B, Rosman P, Gewurtz G. Bilateral hydronephrosis due to fecaloma in an elderly woman. *J Clin Gastroenterol* 2000;30:311-3.
- Yuan R, Zhao GG, Papez S, Cleary JP, Heliotis A. Urethral obstruction and bilateral ureteral hydro-

- nephroses secondary to fecal impaction. *J Clin Gastroenterol* 2000;30:314-6.
19. Paquette EL, Peppas DS. Lower pole ureteral obstruction secondary to fecal impaction in an 8-year-old girl. *Tech Urol* 2001;7:299-301.
20. Kantarci M, Fil F. Education and imaging. Gastrointestinal: fecaloma in a dilated sigmoid colon. *J Gastroenterol Hepatol* 2007;22:955.