

## RESEARCH ARTICLE

# HSP27 is Commonly Expressed in Cervical Intraepithelial Lesions of Brazilian Women

Cristine Dobo, Joao Norberto Stavale, Flavio de Oliveira Lima, Daniel Araki Ribeiro\*, Vitor Arias, Thiago Simao Gomes, Celina Tizuko Fujiyama Oshima

### Abstract

Heat shock proteins are molecular chaperones that may be constitutively present in cells protecting them from various stresses, such as extreme temperature, anoxia or chemical agents. Cervical cancer is the second most prevalent malignancy of women. In this study, we analyzed the expression of Hsp27 by immunohistochemistry in cervical intraepithelial lesions of Brazilian women, along with samples from non neoplastic lesions (NN). Cervical intraepithelial neoplasia I (CIN I), II (CIN II) and III (CIN III)/in situ carcinoma and squamous cell carcinoma (SCC) were included. Immunostaining was observed in 30 (100%) samples of NN, 46 (92%) in CIN I, 50 (100%) in CIN II, 52 (98.11%) in CIN III/CIS, and 46 (98.11%) in SCC. In group NN Hsp27 immunostaining was heterogeneous, more intense in basal and parabasal layers of the epithelium and less or absent in the intermediate and superficial layer. The majority of the samples of CIS and SCC presented strong staining in allepithelial layers. Metaplastic cells, when present, were strongly stained. In this study, Hsp27 protein was found to be commonly expressed in cervical epithelial cells.

**Keywords:** HSP27 - cervical lesion - immunohistochemistry

*Asian Pac J Cancer Prev*, 14 (9), 5007-5010

### Introduction

In Brazil, 4986 women died of carcinoma of the uterine cervix in 2010 ([www.inca.gov.br](http://www.inca.gov.br), 2012). Cervical cancer has a slow progress, from pre-invasive cervical intraepithelial neoplasia (CIN) to invasive phases (Grubisić et al., 2009). It is widely accepted that cervical infections by human papillomavirus (HPV) cause virtually all cervical cancer worldwide (Powell et al., 2013).

Heat shock proteins (HSPs) are molecular chaperones that are evolutionary conserved, are ubiquitous and have multiple functions in cellular homeo-stasis including gene expression regulation, DNA replication, signal transduction, differentiation, apoptosis, and cellular senescence or immortalization. They also protect cells from various stresses such as hypoxia or ischemia, as well as sudden increases in temperature (Arrigo et al., 2013).

Hsp27 belongs to the HSP family, which plays essential functions in cells under physiological conditions and prevents stress-induced cellular damage. It works as a molecular chaperone which supports cells to keep their homeostasis under extrinsic or intrinsic stress conditions, such as heat shock, irradiation, oxidative stress, ER stresses and anticancer chemotherapy (Ma et al., 2013).

Evidence indicates that Hsp27 protein, in addition

to its protective role during heat shock and other forms of environmental and pathophysiological stress, reveals a wide spectrum of functions including regulation of cell growth and differentiation (Adly et al., 2006) and of cytoskeletal dynamics (Hirano et al., 2004), signal transduction and protection against apoptosis induced by different agents (Ma et al., 2013).

HSPs have been recognized for regulating apoptosis and Hsp27 is antiapoptotic by several different mechanisms. This protein could increase the antioxidant defense of cells by increasing glutathione cell content neutralizing the toxic effects of oxidized proteins by its chaperon activity (Uçar et al., 2012). The yours cytoprotective effects has also been attributed to its capacity to bind and stabilize actin polymerization (García-Arguinzonis et al., 2010). The localization of Hsp27 been demonstrated in bovine endothelial cells, in which it probably contributes to the regulation of membrane associated F-actin polymerization (Lavoie et al., 1995).

Hsp27 are abundantly expressed in malignant cells, and have been accused of participating in oncogenesis or chemotherapy resistance (Ma et al., 2013), presumably due to its capacity to disable apoptosis. In breast, gastric and endometrial cancer, the high expression of Hsp27 has been associated with metastasis, poor prognosis and

resistance to chemotherapy or radiation (Ma et al., 2013; Svensson et al., 2013).

Changes in Hsp27 expression observed in the HPV-infected tissues have been suggested that this protein might have a role in virus-host biology (Tozawa-Ono et al., 2012). In the cervix Hsp27 has been suggested as a marker of cell differentiation, and is highly expressed during the process of squamous metaplasia (El-Ghobashy and Herrington, 2009). Moreover, Hsp27 expression seems to protect cells from apoptosis during inflammation (Acunzo et al., 2012). Lo Muzio et al. (2000) found that Hsp27 expression is associated with more aggressive and poorly differentiated oral squamous cell carcinoma. Ono et al. (2009) showed overexpression of Hsp27 not only in squamous cell carcinoma but in various stages of cervical intraepithelial neoplasia, including dysplasia and carcinoma *in situ*.

In this study, we evaluate the expression of Hsp27 in tissue diagnosed as non neoplastic lesion (NN), as cervical Intraepithelial neoplasia I (CIN I=synonymous with productive viral infection), as cervical intraepithelial neoplasia II (CIN II), as cervical Intraepithelial neoplasia III (CIN III=cervical precancer), as *in situ* carcinoma and as squamous cell carcinoma (SCC).

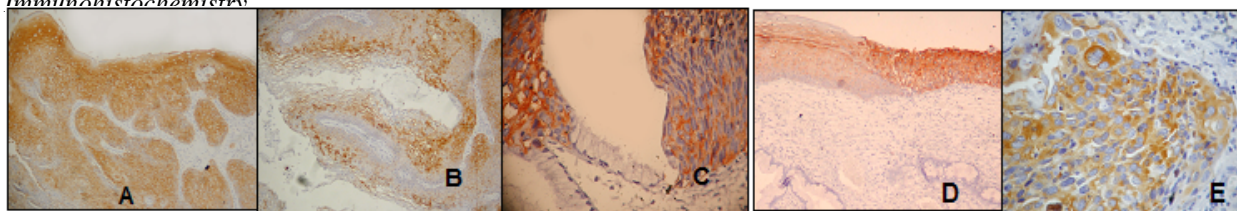
## Materials and Methods

### Tissue specimen and histopathology

The tissues specimens of benign cervical lesions and cervical cancer were obtained by punch biopsy, cone biopsy or radical hysterectomy. Tissues were fixed in formalin and embedded in paraffin according to standard procedures in Departamento de Patologia, Universidade Federal de Sao Paulo/Escola Paulista de Medicina. For each case, all available hematoxylin and eosin stained sections were examined and a representative block was selected after careful screening for quality of fixation and representative pattern of lesions. Ethical approval for this study was granted by the local Ethics Committee (The Resolution no 196 of National Health Council).

The study included samples from 204 patients. Their ages ranged from 18 to 75 years, with a mean of  $43 \pm 12.5$  years. The cervical lesions were diagnosed as non neoplastic lesions (NN) with benign cellular changes (n=30), as cervical Intraepithelial neoplasia I (CIN I=synonymous with productive viral infection) (n=50), as cervical intraepithelial neoplasia II (CIN II) (n=50), as cervical Intraepithelial neoplasia III (CIN III=cervical precancer lesion) (n=31), as carcinoma *in situ* (n=22) and as squamous cell carcinoma (SCC) (n=29).

### Immunohistochemistry



**Figure 1. Representative Immunostaining of Hsp 27.** Note heterogeneous cytoplasmic immunostaining. Immunohistochemical expression of Hsp 27 in non neoplastic lesions (NN), more intense in basal and parabasal layers of the epithelium (A), in CIN I (B), in CIN II (C), in CIN III/isC (D) and in SCC (E). No differences in intensity were observed between the groups

Immunostaining was performed on sections of 3  $\mu$ m mounted on 3-aminopropyltrimethoxy-silane (Sigma-Aldrich, St. Louis, MO, USA) coated slides. Briefly, sections were deparaffinized in xylene, rehydrated through graded ethanols, followed by blocking of endogenous peroxidase activity in 3% hydrogen peroxide for 20 minutes at room temperature. Antibody-binding epitopes were retrieved by pressure-cooking for 2.5 minutes in 10 mM sodium citrate buffer (pH 6.0). Sections were then incubated with mouse monoclonal antibody for Hsp27 (clone: 2B4, dilution 1:40) obtained from Novocastra Laboratories Ltd (Newcastle upon Tyne, UK), overnight at 4°C in humid chamber. After washing twice with phosphate-buffered saline pH 7.4 (PBS), slides were incubated with biotinylated second-stage antibody for 30 minutes, followed by incubation with streptavidin-biotin-peroxidase complex (LSAB, Dako, Carpinteria, California, USA) for further 30 minutes, at room temperature. Staining was carried out using a solution 3-3'-diaminobenzidine tetrahydrochloride (DAB- Dako, Carpinteria, California, USA). Washes with PBS were performed between each step. The Hsp27 was diluted in PBS containing 5% (wt/vol) bovine serum albumin. Nuclei were counterstained with Harris hematoxylin before mounting slides in Entellan (Sigma-Aldrich, St. Louis, MO, USA). Negative and positive controls were included in each batch of immunohistochemistry. Section of skin known to express high levels of Hsp27 was included as positive control, while in negative control the primary antibody was omitted.

Analysis of immunostaining was performed by two investigators. The positive pattern was cytoplasmic and was analyzed according to the criteria of intensity. The intensity of immunostaining was considered as no immunostaining or weak (negative), and moderate or strong (positive). The Dunn test was used for multiple comparisons. The  $p \leq 0.05$  was considered significant.

## Results

As illustrated in Figure 1, predominantly diffuse and heterogeneous cytoplasmic staining for Hsp27 was observed of NN until SCC. Rare nuclear staining was observed. The immunostaining was observed in 30 (100%) samples of NN, 46 (92%) in CIN I, 50 (100%) in CIN II, 52 (98.11%) in CIN III/CIS, and 46 (97.87%) in SCC. The pattern and intensity of immunostaining did not show differences of NN until SCC (Table 1). The results of multiple comparisons of Dunn are showed in the Table 2.

The following were the most salient features. In group NN the Hsp27 immunostaining was heterogeneous, more

**Table 1. Expression of Hsp27 in Cervical Epithelium and SCC: Immunohistochemical Results**

	Hsp27		
	Neg/weak	Moderate	Strong
NN	0	0	30
CINI	4	5	41
CINII	0	6	44
CINIII/CIS	1	5	47
SCC	1	4	42

**Table 2. Results of Multiple Comparisons of Dunn**

Lesion	p
NN X CIN I	0.177
NN X CIN II	0.371
NN X CIN III/CIS	0.129
NN X SCC	0.417
CIN I X CIN II	0.548
CIN I X CIN III/CIS	0.767
CIN I X SCC	0.536
CIN II X CIN III/CIS	0.419
CIN II X SCC	0.958
CIN III/CIS X SCC	0.389

intense in basal and parabasal layers of the epithelium and less or absent in the intermediate and superficial layer. No sample of the group NN showed immunostaining in all layers of the epithelium. The most of the samples of CIS and SCC presented strong stain in the epithelial layers. Metaplastic cells, when present, were strongly stained. Apart from epithelial cells of the groups analyzed, a distinct cytoplasmic immunostaining was observed in the cells of blood vessels, stroma and glands.

## Discussion

The most HSPs are constitutively expressed in eukaryotic cells and participate, mainly through their function as molecular chaperones, in numerous physiological processes, such as three-dimensional folding and intracellular translocation of denatured or newly synthesized proteins, assembly and trafficking of signaling complexes, protein secretion and degradation as well as regulation of growth and differentiation. HSPs are expressed in abnormal levels when correlated with pathological process, such as autoimmune disorders and malignant diseases (Foster et al., 2009).

The Hsp27 is an actin-associated protein, particularly expressed in cells of normal oestrogen target organs (Stice et al., 2012). The response of the normal uterine cervix to estrogenic influence is found heterogeneous in different cervical cell types and in different sites within the same cell layer. This would to explain because the NN lesions showed very heterogeneous Hsp27 expression.

The hormone modulation of Hsp27 in normal and tumor tissues were examined, particularly in breast, endometrium and glandular epithelium. Studies showed that, in squamous cell carcinoma of the cervix, the presence of Hsp27 is independent of the presence of estrogen receptors and progesterone receptors. Usually, these neoplasia is negative for estrogen and progesterone receptors, and no association among Hsp27 and these receptors were observed (Stice et al., 2012). In oral cancers, this protein have been overexpressed in more differentiated tumors (Liu et al., 2011).

The Hsp27 expression is observed in the HPV-infected tissues. The cytoplasm of the cells with koilocytotic changes to show very low Hsp27 content independent on a particular HPV type infection (Stice et al., 2012). However, we observed moderate to strong expression of Hsp27 in the most of samples independent the presence or not of HPV infection. We had a limitation in our study. We

did not have sufficient material for HPV testing (ISH or PCR). Therefore, we believe that virtually all the cervical lesions were infected by high risk HPV.

We also observed a strong Hsp27 immunoreactivity in areas with squamous metaplasia. Such data are in fully in line with others (Tozawa-Ono et al., 2012). In the cervix Hsp27 is a marker of cell differentiation, and is highly expressed during the process of squamous metaplasia (Liu et al., 2011). Romanucci et al. (2005) suggested that Hsp27 should be regarded as a differentiation marker for keratinocytes, both in normal and in neoplastic canine skin.

In this study, Hsp27 expression was strong and homogeneous in the most of CIS and SCC in according with Lambot et al. (2000), which studied human oesophageal squamous cell carcinoma by immunohistochemistry. Hsp27 is abundantly expressed in malignant cells, and have been accused of participating in oncogenesis or chemotherapy resistance (Slotta-Huspenina et al., 2013), presumably due to its capacity to disable apoptosis.

In nasopharyngeal carcinoma, expression of HSPs and p53 showed correlation suggesting a role in the development of carcinogenesis in this cancer (Cheng et al., 2003). Another study showed that induction of Hsp27 expression was wild-type p53-specific and was not due to non-specific effects of cell growth arrest and/or apoptosis (Gao et al., 2000). The nature of p53 and Hsp27 interactions in the regulation of apoptosis and/or cell growth needs to be further defined; however the studies showed evidences that Hsp27 has a role in cell cycle, and maybe to increase the stimuli to cell growth in cooperating with the p53 degradation in HPV lesions.

In stressful condition, Hsp27 can favors p27Kip1 ubiquitination and degradation by the proteasome, and favors progression through the cell cycle (Parcellier et al., 2006). In human epidermal cell carcinoma cell line (A431), immunoblotting analysis demonstrated that Hsp27 associates with actin, the mutant form of p53, hsp70 and hsp90. Immunofluorescence analysis showed a co-localization between hsp27 and p53, and concluded that hsp27 is a part of a complex system of molecular chaperones in epidermal keratinocytes (Kindas-Mugge et al., 2002).

HSPs may exert an antiapoptotic, or pro-apoptotic activity, thus being implicated in the control of cell growth, differentiation, carcinogenesis and biological behaviour of many neoplasms. Due to its apoptosis-inhibitory effect, Hsp27 seems to play an important role in the process of carcinogenesis (Jolly and Morimoto, 2000).

The precise role of increased expression of Hsp27 in tumor cells remains to be determined. This overexpression may indeed reflect a biological stress condition, such as lack of nutrients or hypoxia, experienced by neoplastic cells (Tozawa-Ono et al., 2012). Increased expression of Hsp27 may be associated with an increased cellular activity or cell proliferation rate (Tozawa-Ono et al., 2012). In this respect, the cell cycle related regulation of Hsp27 synthesis in mammalian cells suggests a role for this protein in the control of cell growth; in fact, Hsp27 interacts with several components of the eukaryotic cell cycle and is particularly expressed during the S-phase (Helmbrecht et al., 2000).



In summary, we found increased expression of Hsp27 of NN to SCC, suggesting an activation of the stress response to infection by HPV. The study of Hsp27 in carcinogenesis is beginning, and information on how Hsp27 regulation is subverted in cancer and how its deregulation affects the molecular events involved with cell growth, invasiveness and metastasis will be essential in directing the studies in cancer therapy.

## Acknowledgements

This work was supported by CNPq and CAPES. DAR is a recipient of CNPq fellowship.

## References

- Acunzo J, Katsogiannou M, Rocchi P (2012). Small heat shock proteins HSP27 (HspB1),  $\alpha$ B-crystallin (HspB5) and HSP22 (HspB8) as regulators of cell death. *Int J Biochem Cell Biol*, **44**, 1622-31.
- Adly MA, Assaf HA, Hussein MR (2006). Expression of the heat shock protein-27 in the adult human scalp skin and hair follicle: hair cycle-dependent changes. *J Am Acad Dermatol*, **54**, 811-7.
- Arrigo AP (2013). Human small heat shock proteins: protein interactomes of homo- and hetero-oligomeric complexes: an update. *FEBS Lett*, **587**, 1959-69.
- Cheng L, Liu L, Zhang M, Xiao C, Wu T (2003). Expression of main heat stress proteins and p53 in nasopharyngeal carcinoma. *Lin Chuang Er Bi Yan Hou Ke Za Zhi*, **17**, 458-60.
- Conroy SE, Latchman DS (1996). Do heat shock proteins have a role in breast cancer? *Br J Cancer*, **74**, 717-21.
- El-Ghobashy AA, Herrington CS (2009). Overexpression of heat shock protein 27 in squamous cell carcinoma of the uterine cervix. *Hum Pathol*, **40**, 1668-9.
- Foster CS, Dodson AR, Ambroisine L, et al (2009). Hsp-27 expression at diagnosis predicts poor clinical outcome in prostate cancer independent of ETS-gene rearrangement. *Br J Cancer*, **101**, 1137-44.
- Gao C, Zou Z, Xu L, et al (2000). p53-dependent induction of heat shock protein 27 (HSP27) expression. *Int J Cancer*, **88**, 191-4.
- García-Arguinzonis M, Padró T, Lugano R, Llorente-Cortes V, Badimon L (2010). Low-density lipoproteins induce heat shock protein 27 dephosphorylation, oligomerization, and subcellular relocalization in human vascular smooth muscle cells. *Arterioscler Thromb Vasc Biol*, **30**, 1212-9.
- Garrido C, Ottavi P, Fromentin A, et al (1997). HSP27 as a mediator of confluence-dependent resistance to cell death induced by anticancer drugs. *Cancer Res*, **57**, 2661-7.
- Grubisić G, Klarić P, Jokanović L, et al (2009). Diagnostic approach for precancerous and early invasive cancerous lesions of the uterine cervix. *Coll Antropol*, **33**, 1431-6.
- Helmbrecht K, Zeise E, Reinsing L (2000). Chaperones in cell cycle regulation and mitogenic signal transduction: a review. *Cell Prolif*, **33**, 341-65.
- Hirano S, Sheldon EA, Gilmont RR (2004). HSP27 regulates fibroblast adhesion, motility, and matrix contraction. *Cell Stress Chaperones*, **9**, 29-37.
- Kindas-Mugge I, Rieder C, Frohlich I, Micksche M, Trautinger F (2002). Characterization of proteins associated with heat shock protein hsp27 in the squamous cell carcinoma cell line A431. *Cell Biol Int*, **26**, 109-16.
- Lambot MA, Peny MO, Fayt I, Haot J, Noe Èl (2000). Overexpression of 27-kDa heat shock protein relates to poor histological differentiation in human oesophageal squamous cell carcinoma. *Histopathology*, **36**, 326-30.
- Liu H, Han Y, Mi R, et al (2011). Identification of cervical cancer proteins associated with treatment with paclitaxel and cisplatin in patients. *Int J Gynecol Cancer*, **21**, 59-67.
- Lo Muzio L, Leonardi R, Marigliò MA, et al (2000). HSP 27 as possible prognostic factor in patients with oral squamous cell carcinoma. *Histol Histopathol*, **19**, 119-28.
- Ma W, Teng Y, Hua H, et al (2013). Upregulation of heat shock protein 27 confers resistance to actinomycin D-induced apoptosis in cancer cells. *FEBS J*, **280**, 4612-24.
- Ono A, Kumai T, Koizumi H, et al (2009). Overexpression of heat shock protein 27 in squamous cell carcinoma of the uterine cervix: a proteomic analysis using archival formalin-fixed, paraffin-embedded tissues. *Hum Pathol*, **40**, 41-9.
- Parcellier A, Brunet M, Schmitt E, et al (2006). HSP27 favors ubiquitination and proteasomal degradation of p27Kip1 and helps S-phase re-entry in stressed cells. *FASEB J*, **20**, 1179-81.
- Park KJ, Gaynor RB, Kwak YT (2003). Heat shock protein 27 association with the I kappa B kinase complex regulates tumor necrosis factor alpha-induced NF-kappa B activation. *J Biol Chem*, **278**, 35272-8.
- Powell N, Cuschieri K, Cubie H, et al (2013). Cervical cancers associated with human papillomavirus types 16, 18 and 45 are diagnosed in younger women than cancers associated with other types: a cross-sectional observational study in Wales and Scotland (UK). *J Clin Virol*, [Epub ahead of print].
- Romanucci M, Bongiovanni L, Marruchella G, et al (2005). Heat shock proteins (HSPs) expression in canine intracutaneous cornifying epithelioma and squamous cell carcinoma. *Vet Dermatol*, **16**, 108-16.
- Slotta-Huspenina J, Wolff C, Drecoll E, et al (2013). A specific expression profile of heat-shock proteins and glucose-regulated proteins is associated with response to neoadjuvant chemotherapy in oesophageal adenocarcinomas. *Br J Cancer*, **109**, 370-8.
- Stice JP, Mbai FN, Chen L, Knowlton AA (2012). Rapid activation of nuclear factor  $\kappa$ B by 17 $\beta$ -estradiol and selective estrogen receptor modulators: pathways mediating cellular protection. *Shock*, **38**, 128-36.
- Svensson KJ, Christianson HC, Wittrup A, et al (2013). Exosome uptake depends on ERK1/2-heat shock protein 27 signaling and lipid Raft-mediated endocytosis negatively regulated by caveolin-1. *J Biol Chem*, **288**, 17713-24.
- Tozawa-Ono A, Yoshida A, Yokomachi N, et al (2012). Heat shock protein 27 and p16 immunohistochemistry in cervical intraepithelial neoplasia and squamous cell carcinoma. *Hum Cell*, **25**, 24-8.
- Tozawa-Ono A, Yoshida A, Yokomachi N, et al (2012). Heat shock protein 27 and p16 immunohistochemistry in cervical intraepithelial neoplasia and squamous cell carcinoma. *Hum Cell*, **25**, 24-8.
- Uçar EÖ, Arda N, Aitken A (2012). Extract from mistletoe, *Viscum album* L., reduces Hsp27 and 14-3-3 protein expression and induces apoptosis in C6 rat glioma cells. *Genet Mol Res*, **11**, 2801-13.