

## Case Report

# A Superior Ulnar Collateral Artery Perforator Flap for a Large Defect on the Posterior Upper Arm

Hojin Park, Eul-Sik Yoon

Department of Plastic Surgery, Anam Hospital, Korea University College of Medicine, Seoul, Korea

Received November 20, 2013  
Revised November 23, 2013  
Accepted November 25, 2013

Correspondence to: Eul-Sik Yoon  
Department of Plastic Surgery,  
Korea University Anam Hospital,  
73 Incheon-ro, Seongbuk-gu,  
Seoul 136-705, Korea  
Tel: +82-2-920-5368  
Fax: +82-2-922-7437  
E-mail: yesanam2@korea.ac.kr

A patient underwent reconstruction of skin and soft tissue using V-Y advancement of a superior ulnar collateral artery perforator flap after resection of the scar tissue on the upper arm. Successful flap healing was observed without complications. The medial side of the upper arm is an ideal donor site because of its thin, elastic, and hairless skin, resulting in a well-hidden scar. The elasticity of the medial side of the upper arm allows primary closure after flap elevation. The superior ulnar collateral artery perforator flap is an option for reconstruction of the upper arm.

**Key Words:** Perforator flap, Superior ulnar collateral artery

The development of perforator flaps concept based on knowledge on vascular anatomy of the skin represents a major improvement in reconstructive surgery.<sup>1</sup> Succeeding description about vascular territories and anatomical basics of the main donor sites, the study of hidden donor sites, such as medial upper arm, constitute a new step and an additional refinement.<sup>2</sup>

The proximal ulnar artery has several branches, including perforators that are directly derived from the ulnar artery and anterior/posterior recurrent arteries. There are only a few reports of flaps that use the anterior or posterior recurrent arteries.<sup>3</sup>

The inner side of the arm was first used to generate distal flaps in 1597 by Tagliacozzi.<sup>4</sup> In 1975, Daniel et al.<sup>5</sup> proposed use of the medial arm skin for a free flap based on the superior ulnar collateral artery. However, its application as a free flap is limited, possibly because of variation in the vascular anatomy of the upper arm and increased use of the forearm and lateral arm flaps.

In the present study, we describe our experience with the use of a superior ulnar collateral artery perforator flap for

reconstruction of the upper arm region after resection of a chronic scar.

## CASE REPORT

A 47-year-old man presented with a chronic scar on the posterior side of his right upper arm resulting from an electric burn sustained during atrial fibrillation ablation 7 years previously. The wound healed by secondary intention. The patient reported pain in the upper arm and expressed aesthetic concerns. The scar measured 8×9 cm in diameter (Fig. 1A).

The patient preferred to save his latissimus dorsi muscle because he was a golf player and did not want to weaken his back muscles. Therefore, we planned a medial arm skin flap to cover the defect instead of a latissimus dorsi myocutaneous flap.

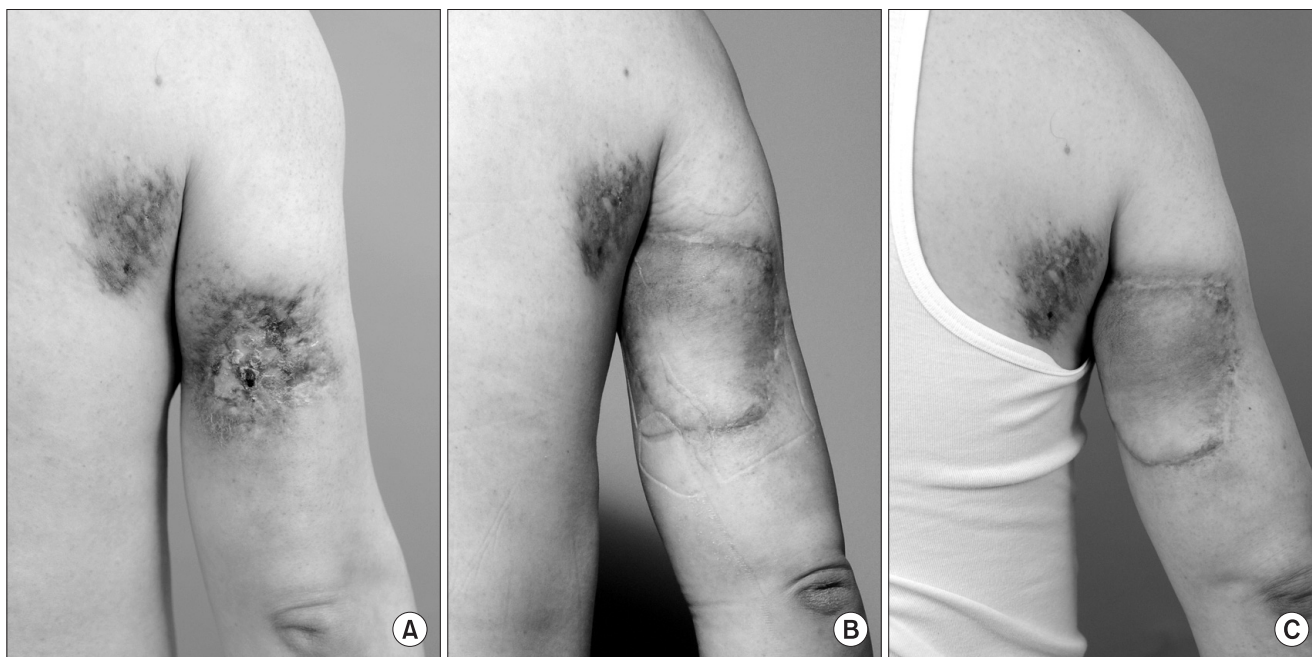
Computed tomography angiography was performed to confirm the location of the perforators of the upper arm. Two perforators arising from the superior ulnar collateral artery were identified (Fig. 2). We used Doppler sonography

in the operating room to locate the perforator vessels before flap design. After resection of the scar tissue, the flap was designed according to the size and shape of the defect.

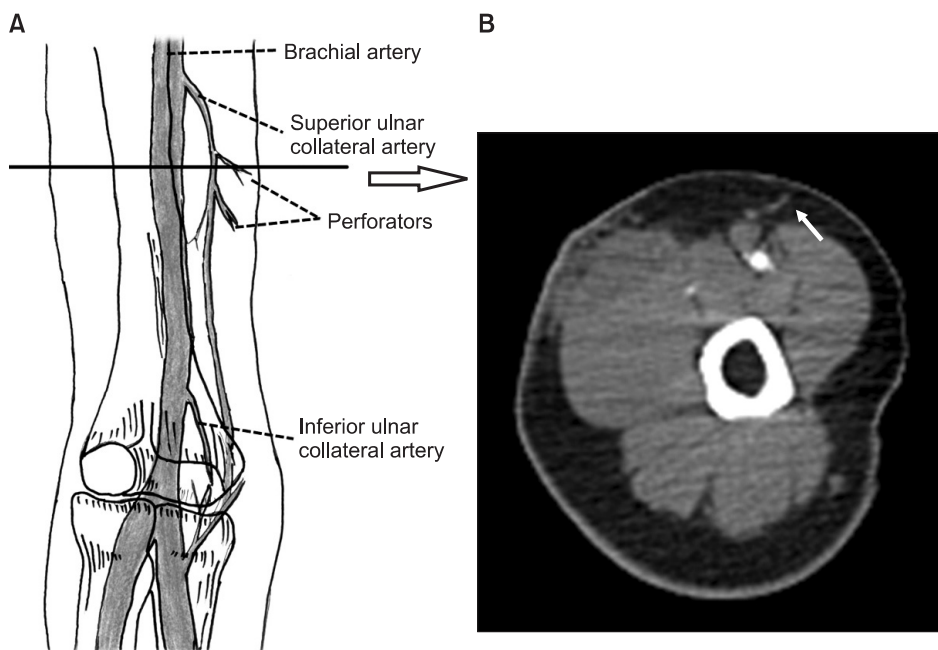
The skin flap was elevated on the two perforators of the superior ulnar collateral artery; the flap measured 8×12 cm in diameter (Fig. 3). After complete elevation of the flap and

vascular pedicles, the flap was advanced in a V-Y pattern from the medial side of the upper arm to the posterior side. The wound at the donor site was closed by direct approximation over a suction drain to minimize the risk of hematoma or seroma.

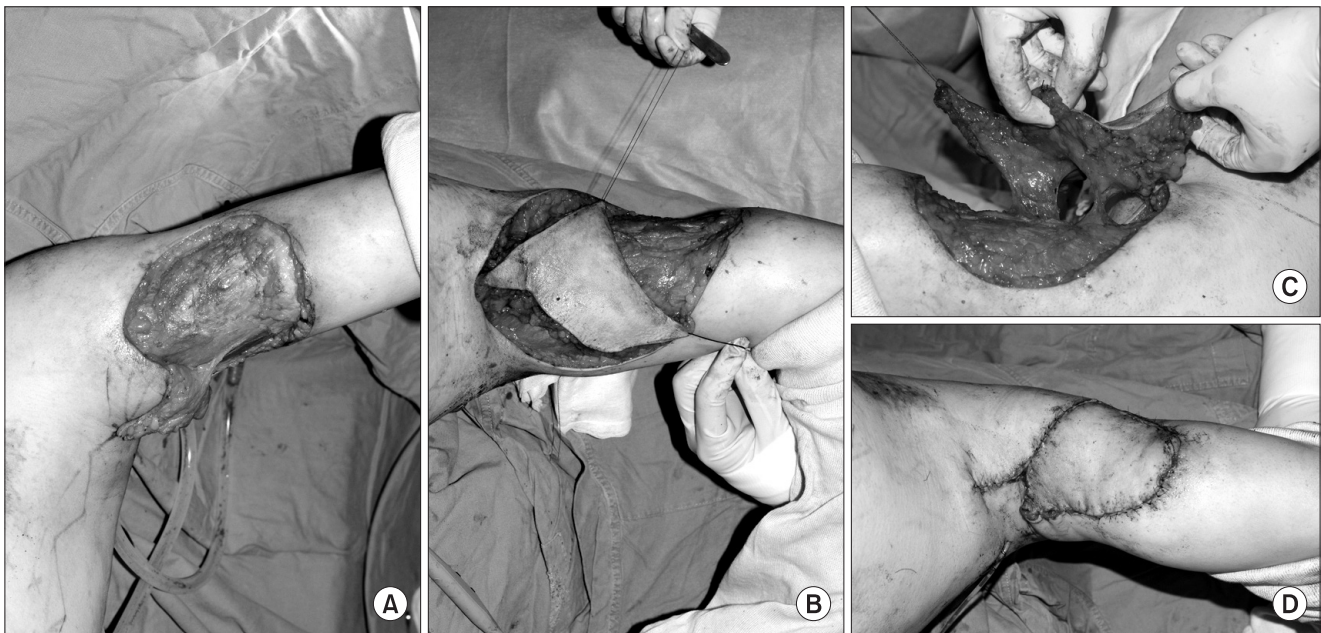
There were no major postoperative complications. The



**Fig. 1.** (A) A 47-year-old male patient with a scar on the posterior side of the right upper arm. The scar measured 8×9 cm in diameter. (B) Results at 2 months and (C) 7 months after reconstruction.



**Fig. 2.** (A) Schematic representation of the running pattern of the ulnar recurrent artery and its perforators. (B) Upper extremity angiogram showing the perforators arising from the superior ulnar collateral artery (arrow).



**Fig. 3.** (A) After scar tissue excision, a flap was designed according to the size of the defect. (B) The flap was advanced from the medial side of the upper arm to the posterior side. (C) The flap was elevated on the two perforators of the superior ulnar collateral artery. (D) View of the upper arm of the patient immediately after surgery.

flap healed uneventfully, and the patient was discharged on postoperative day 6. Morbidity at the donor site was minimal. No hematoma formation or wound dehiscence was observed. The patient expressed satisfaction with the cosmetic and functional results (Fig. 1).

## DISCUSSION

Scars and ulcers in the upper arm can often be corrected using the flap method. In most upper arm burns, replacement of the lost tissue is required to achieve permanent and satisfactory results. Skin grafts are effective for covering the defect; however, they are associated with a risk of contracture, which can alter the shape of the upper arm and limit range of motion, in addition to resulting in a patchy appearance. If, bone, tendon, and nerve have been exposed, flap repair becomes the only alternative.

Reconstruction of upper arm defects is often performed using latissimus dorsi myocutaneous flaps; however, donor site morbidity, including weakness, numbness, and back muscle tightness, are common adverse events associated with this procedure.<sup>5</sup> This can be problematic to certain patients such as athletes or golf players.

The medial side of the upper arm is an ideal donor site because of its thin, elastic, and hairless skin that results in a well-hidden scar. The elasticity of the medial side of the upper arm allows primary closure after flap elevation. The donor site scar of the medial arm flap is well hidden during a patient's normal daily activities.

The medial side of the upper arm has been overlooked, perhaps because of a poor understanding of the anatomical variations of the arteries supplying the skin. The upper arm has several perforating arteries in the subfascial plane. Only four fasciocutaneous perforators are constant: one on the medial intermuscular septum and three in the lateral intermuscular septum of the arm.<sup>6</sup>

The vascular network supplying blood to this area is complex. Various reports have described the vascular supply of the skin. Breidenbach et al.<sup>7</sup> showed that the medial arm skin receives its blood supply from the superior ulnar collateral artery (65%), the cutaneous branch of the brachial artery (20%), or both (15%). These authors showed that the superior ulnar collateral artery may arise directly from the brachial artery distal to the deep brachial artery or, rarely, the deep brachial artery itself.<sup>3</sup>

The superior ulnar collateral artery can be used as a source

for the arterial pedicle of the flap. The medial arm flap is a type C fasciocutaneous flap. If it involves the superior ulnar collateral artery, it can be used as a donor site for free microvascular tissue transfer.

In summary, use of a medial arm skin flap is safe and reliable; therefore, it is a potential choice for the repair of defects in the upper arm region. This flap provides a fine texture, ideal thickness, hairless coverage, and a well-hidden donor site scar.

## REFERENCES

1. Sinna R, Qassemyar Q, Pérignon D, Benhaim T, Robbe M. About perforator flaps...20 years later. *Ann Chir Plast Esthet* 2011;56: 128-33.
2. Pérignon D, Havet E, Sinna R. Perforator arteries of the medial upper arm: anatomical basis of a new flap donor site. *Surg Radiol Anat* 2013;35:39-48.
3. Hwang K, Lee WJ, Jung CY, Chung IH. Cutaneous perforators of the upper arm and clinical applications. *J Reconstr Microsurg* 2005;21:463-9.
4. Esther RJ, Lamps L, Schwartz HS. Marjolin ulcers: secondary carcinomas in chronic wounds. *J South Orthop Assoc* 1999;8: 181-7.
5. Daniel RK, Terzis J, Schwarz G. Neurovascular free flaps. A preliminary report. *Plast Reconstr Surg* 1975;56:13-20.
6. Adams WP Jr, Lipschitz AH, Ansari M, Kenkel JM, Rohrich RJ. Functional donor site morbidity following latissimus dorsi muscle flap transfer. *Ann Plast Surg* 2004;53:6-11.
7. Breidenbach WC, Adamson W, Teriz JK. Medial arm flap revisited. *Ann Plast Surg* 1987;18:156-63.