

## Case Report

# Radiologic Findings of Local Effect of Right Adrenal Pheochromocytoma on the Adjacent Liver: A Case Report

Jung Hyo Rhim, MD<sup>1</sup>, Jeong Yeon Cho, MD<sup>1-3</sup>, Seung Hyup Kim, MD<sup>1-3</sup>

<sup>1</sup>Department of Radiology, Seoul National University Hospital

<sup>2</sup>Institute of Radiation Medicine and <sup>3</sup>Kidney Research Institute, Seoul National University Medical Research Center

We report the radiological findings of regional enhancement of the liver adjacent to the right adrenal pheochromocytoma. CT and MRI showed focal strong enhancement of adjacent liver tissue in the arterial phase. However during the delayed phase, the lesion showed iso-attenuation with normal hepatic parenchyma and not delineated. The lesion did not show abnormal signal intensity on neither T1 nor T2 weighted images and indistinguishable from normal parenchyma. The enhancing hepatic lesion was spontaneously regressed on postoperative follow up CT which was taken several months after the adrenalectomy.

**Index words :** Pheochromocytoma · Liver · Computed tomography (CT) · Magnetic resonance imaging (MRI)

## INTRODUCTION

Pheochromocytomas are tumors originated from chromaffin cells. It is well-known that pheochromocytomas synthesize a variety of secretory products and exert intra-adrenal as well as systemic effects(1). Although the dominant products are catecholamines (norepinephrine, epinephrine and dopamine), some neuropeptides and cytokines are also reported as minor products. Despite ample reports on the systemic effects of pheochromocytomas, little is known about their local effects and there is no reports regarding the radiologic findings of the localized effect of pheochromocytomas on adjacent organs. We report a case of right adrenal pheochromocytoma with local effects on the adjacent hepatic tissue.

• Received; June 26, 2012 • Revised; July 28, 2012

• Accepted; July 29, 2012

Corresponding author : Jeong Yeon Cho, M.D., Department of Radiology, Seoul National University Hospital, 101 Daehangno, Jongno-gu, Seoul 110-744, Korea.

Tel. 82-2-2072-3074, Fax. 82-2-743-6385

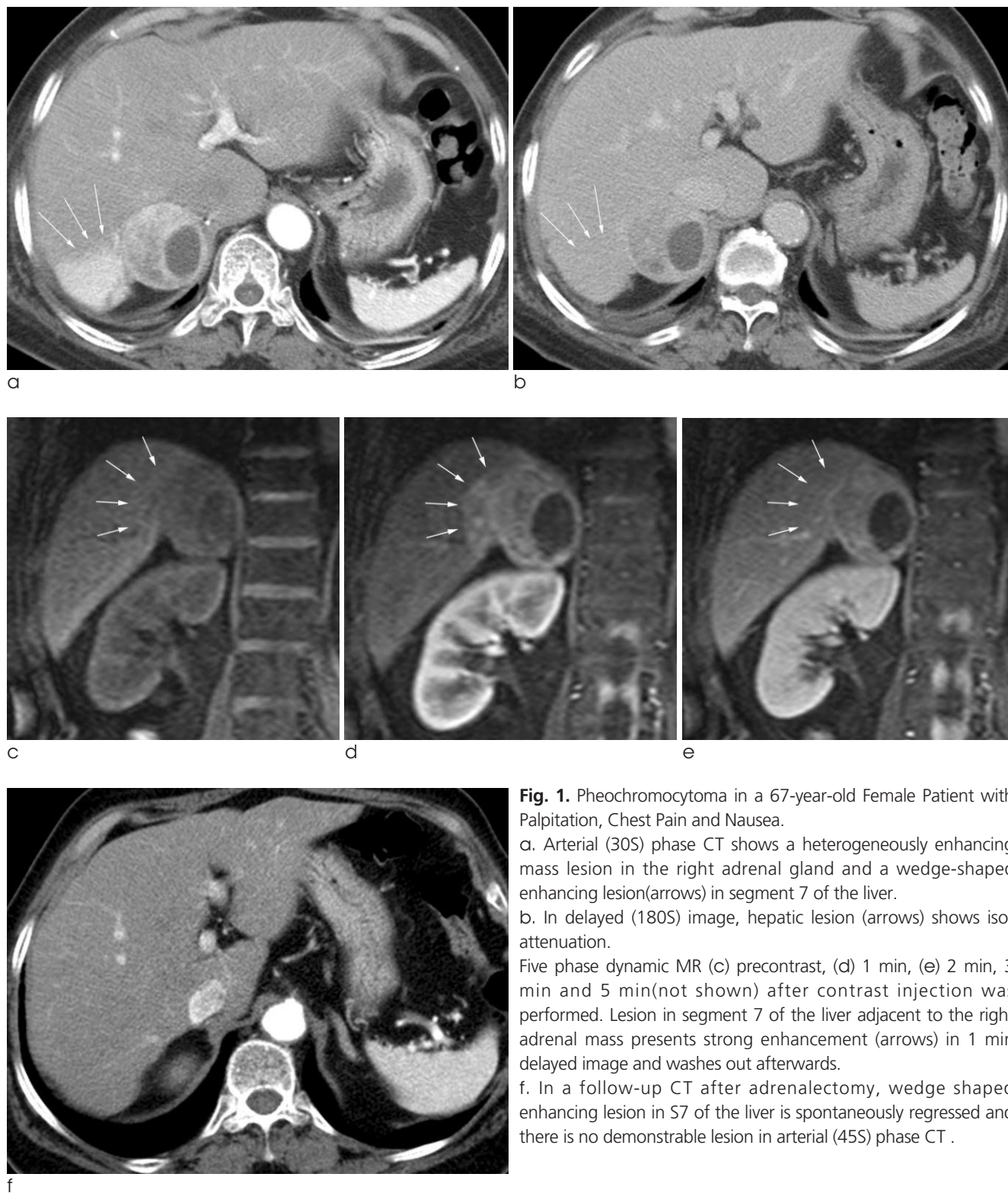
E-mail : radjycho@radiol.snu.ac.kr

## CASE REPORT

A 67-year-old female patient presented with acute renal failure, fever, and proteinuria. She had a 20-year history of hypertension and a 6-year history of diabetes. She complained of palpitations, chest pain, and nausea. A coronary angiography was unremarkable. During the hospital course, her systolic blood pressure was above 200 mmHg several times a day. Her plasma epinephrine and norepinephrine levels were 970 pg/mL and 733 pg/mL, respectively. A 24-hour urine specimen was collected; the VMA, metanephrine, and norepinephrine levels were 51 mcg/mg, 15.2 mcg/day, and 1826.2 mcg/day respectively. Arterial phase contrast-enhanced CT (Fig. 1a) showed a heterogeneously-enhancing mass with central low attenuated area in the right adrenal gland and a wedge-shaped enhancing lesion (arrow) on segment 7 of the liver. On the delayed image (Fig. 1b), not only the adrenal mass, but the adjacent hepatic lesion washed out to show iso-attenuation. Five-phase dynamic MR images were obtained - before injecting contrast (Fig. 1c), and 1 (Fig. 1d), 2 (Fig. 1e), 3, and 5

minutes after contrast injection. The lesion in segment 7 of the liver adjacent to the right adrenal mass had strong enhancement in the 1-min delayed image and washed out afterwards. The enhancing portion was indistinguishable from adjacent normal parenchyma in

precontrast or delayed CT scans and never showed abnormal signal intensity in all MR sequences except for the 1-min delayed image after contrast injection. On surgery, about 5 cm sized mass was noted at right adrenal gland. Right adrenalectomy was performed



**Fig. 1.** Pheochromocytoma in a 67-year-old Female Patient with Palpitation, Chest Pain and Nausea.

a. Arterial (30S) phase CT shows a heterogeneously enhancing mass lesion in the right adrenal gland and a wedge-shaped enhancing lesion(arrows) in segment 7 of the liver.

b. In delayed (180S) image, hepatic lesion (arrows) shows isoattenuation.

Five phase dynamic MR (c) precontrast, (d) 1 min, (e) 2 min, 3 min and 5 min(not shown) after contrast injection was performed. Lesion in segment 7 of the liver adjacent to the right adrenal mass presents strong enhancement (arrows) in 1 min delayed image and washes out afterwards.

f. In a follow-up CT after adrenalectomy, wedge shaped enhancing lesion in S7 of the liver is spontaneously regressed and there is no demonstrable lesion in arterial (45S) phase CT .

and perioperative course was uneventful. A  $4.8 \times 3.9 \times 3.7$  cm sized mass with a  $3 \times 2.2 \times 2.5$  cm sized cystic portion was noted in right adrenal gland. The pathology was confirmed as benign pheochromocytoma with mild nuclear pleomorphism, less than 1 mitosis in 10 high power fields and confined in adrenal gland without capsular invasion. On follow-up CT after adrenalectomy, the wedge-shaped enhancing lesion in segment 7 of the liver had spontaneously regressed (Fig. 1f).

## DISCUSSION

Pheochromocytomas are tumors arising from chromaffin cells that produce and metabolize catecholamines, such as norepinephrine, epinephrine, and less frequently, dopamine. Secreted catecholamines bind to  $\alpha$ - or  $\beta$ -adrenergic receptors and exert various effects. In general, activation of  $\alpha$ -adrenergic receptors is related to vasoconstriction. In contrast, stimulation of  $\beta$ -receptors is related to vasodilation or positive chronotropic and inotropic effects. Therefore, the clinical signs or symptoms of pheochromocytomas can be varied depending on the types of secreted catecholamines and types of receptors stimulated (2). Although catecholamines are well-known products of pheochromocytomas, some neuropeptides and cytokines (substance P, vasointestinal peptide [VIP], corticotrophin-releasing hormone [CRH], adrenocorticotropic hormone [ACTH], interleukin-1 [IL-1], and interleukin-6 [IL-6]) are also reported as minor products (1, 3–5). A number of reports have described the systemic effects of pheochromocytomas; (1, 4, 5) paroxysmal hypertension, headaches, and tachycardia are the most common symptoms. In addition, fever and acute systemic inflammatory symptoms due to IL-6 have been reported, and watery diarrhea, hypokalemia, and achlorhydria have been reported in patients with VIP-secreting pheochromocytomas (1, 4). Some patients with pheochromocytomas also develop Cushing syndrome due to the ACTH secreted from the tumor (5).

In contrast, very little is known regarding the local effects of pheochromocytomas. Indeed, as far as we know, this is the first case report demonstrating the local effect of right adrenal pheochromocytoma on the liver. Although the exact mechanism underlying this

temporary enhancing hepatic lesion remains to be elucidated, one possible explanation might be that secretory products, such as catecholamines or inflammatory cytokines, are responsible for it by inducing localized vasodilation or inflammation in the adjacent liver. Although Chung et al. (6) described the hepatic effect of pheochromocytomas by reporting a case in which intrahepatic cholestasis was associated, IL-1 $\beta$  from the tumor exerted other acute systemic inflammatory symptoms as well (6).

The liver is the second most common site of metastasis for pheochromocytomas. Hepatic metastasis of malignant pheochromocytomas has been reported in up to 30% of patients with malignant pheochromocytomas (7, 8). Because many metastatic tumors present with enhancing nodular lesions, it would be important to distinguish the temporary enhancing hepatic lesions from the metastases. In presenting case, enhancing hepatic lesions were different from metastatic lesions in that there was no significant mass effect. In addition, the lesion was only visualized in early arterial phase image and indistinguishable from normal hepatic parenchyma in all other MR sequences and delayed phase CT image. This lesion seems to be a lesion related with hemodynamic changes rather than a structurally altered true pathologic lesion.

In summary, we have presented a case demonstrating the local effect of pheochromocytoma on the adjacent liver. Contrast-enhanced CT images revealed strong enhancement in the arterial phase and wash out in the delayed phase. On dynamic MR, the hepatic lesions showed peak enhancement on earliest arterial phase image and wash-out thereafter. Adrenalectomy results in the regression of hepatic lesion in several months. Therefore, when the enhancing lesion is identified in the liver adjacent to the right adrenal pheochromocytoma, one should consider the possibility of a local effect of pheochromocytomas on the liver and differentiate it from hepatic metastasis.

## References

1. Kang JM, Lee WJ, Kim WB, et al. Systemic inflammatory syndrome and hepatic inflammatory cell infiltration caused by an interleukin-6 producing pheochromocytoma. *Endocr J* 2005;52:193-198
2. Bravo EL, Gifford RW, Jr. Pheochromocytoma. *Endocrinol Metab Clin North Am* 1993;22:329-341

3. Fonseca V, Bouloux PM. Pheochromocytoma and paraganglioma. *Baillieres Clin Endocrinol Metab* 1993;7:509-544

4. Ikuta S, Yasui C, Kawanaka M, et al. Watery diarrhea, hypokalemia and achlorhydria syndrome due to an adrenal pheochromocytoma. *World J Gastroenterol* 2007;13:4649-4652

5. Nijhoff MF, Dekkers OM, Vleming LJ, Smit JW, Romijn JA, Pereira AM. ACTH-producing pheochromocytoma: clinical considerations and concise review of the literature. *Eur J Intern Med* 2009;20:682-685

6. Chung CH, Wang CH, Tzen CY, Liu CP. Intrahepatic cholestasis as a paraneoplastic syndrome associated with pheochromocytoma. *J Endocrinol Invest* 2005;28:175-179

7. Morikawa T, Suzuki M, Unno M, Endo K, Katayose Y, Matsuno S. Malignant pheochromocytoma with hepatic metastasis diagnosed 10 years after a resection of the primary incidentaloma adrenal lesion: report of a case. *Surg Today* 2001;31:80-84

8. Schlumberger M, Gicquel C, Lumbroso J, et al. Malignant pheochromocytoma: clinical, biological, histologic and therapeutic data in a series of 20 patients with distant metastases. *J Endocrinol Invest* 1992;15:631-642

## 우측 부신에서 발생한 갈색세포종이 인접 간에 미치는 국소적 영향에 관한 영상의학적 소견 : 증례 보고

<sup>1</sup>서울대학교병원 영상의학과

<sup>2</sup>서울대학교 의과대학 의학연구원 방사선의학연구소

<sup>3</sup>서울대학교 의과대학 의학연구원 신장연구소

임정호<sup>1</sup> · 조정연<sup>1-3</sup> · 김승협<sup>1-3</sup>

본 저자들은 우측 부신에서 발생한 갈색세포종과 인접한 간에서 보이는 국소적인 조영 증강의 영상의학적 소견을 보고하고자 한다. 전산화단층촬영과 자기공명영상의 동맥기 영상에서 인접한 간조직에 국소적인 강한 조영증강이 보였다. 그러나 지연기 영상에서 병변은 정상 간조직과 동일한 감쇄를 보여 잘 구분되지 않았다. 또한 병변은 자기공명 T1, T2 강조 영상에서도 비정상적인 신호강도를 보이지 않았으며 정상 조직과 구분되어 보이지 않았다. 이 조영증강되는 간의 병소는 부신절제술을 시행한지 수개월 후 다시 시행한 수술 후 전산화 단층촬영에서는 저절로 소실되어 보이지 않았다.

통신저자 : 조정연, (110-744) 서울시 종로구 대학로 101번지, 서울대학교병원 영상의학과  
 Tel. (02) 2072-3074 Fax. (02) 743-6385 E-mail: radjycho@radiol.snu.ac.kr