

## Original Article

# Pharmacological Functional Magnetic Resonance Imaging of Cloropidol on Motor Task

Yongmin Chang<sup>1-3</sup>

<sup>1</sup>Department of Molecular Medicine, <sup>2</sup>Department of Medical & Biological Engineering, <sup>3</sup>Department of Radiology, Kyungpook National University College of Medicine, Daegu, Korea

**Purpose :** To investigate the pharmacologic modulation of motor task-dependent physiologic responses by antiplatelet agent, clopidogrel, during hand motor tasks in healthy subjects.

**Materials and Methods:** Ten healthy, right-handed subjects underwent three functional magnetic resonance (fMRI) sessions: one before drug administration, one after high dose drug administration and one after reaching drug steady state. For the motor task fMRI, finger flexion-extension movements were performed. Blood oxygenation level dependent (BOLD) contrast was collected for each subject using a 3.0 T VHi (GE Healthcare, Milwaukee, USA) scanner. T2\*-weighted echo planar imaging was used for fMRI acquisition. The fMRI data processing and statistical analyses were carried out using SPM2.

**Results:** Second-level analysis revealed significant increases in the extent of activation in the contralateral motor cortex including primary motor area (M1) after drug administration. The number of activated voxels in motor cortex was 173 without drug administration and the number increased to 1049 for high dose condition and 673 for steady-state condition respectively. However, there was no significant difference in the magnitude of BOLD signal change in terms of peak T value.

**Conclusion:** The current results suggest that cerebral motor activity can be modulated by clopidogrel in healthy subjects and that fMRI is highly sensitive to evidence such changes.

**Index words :** Antiplatelet drug · Functional Magnetic resonance imaging (fMRI) · Motor function

## INTRODUCTION

Many lines of evidence suggest that cerebral activity can be modulated by pharmacologic compound and that fMRI sensitivity is high enough to evidence such changes (1–3). Loubinoux et al. demonstrated that cerebral motor activity can be modulated by fluoxetine, an inhibitor of serotonin reuptake, or fenozolone,

an amphetamine-like drug during hand motor task in healthy subjects (4). The action of both drugs on motor cortices, SMA, and cerebellum suggests a facilitatory or stimulating function of the monoaminergic systems on motor activity. Also, the excitatory effect of both noradrenaline and dopamine on motor behavior demonstrated in animal and clinical studies (5, 6). Pharmacologic modulation of motor activity has potential clinical importance because these drugs may facilitate motor recovery in poststroke patients undergoing motor reorganization. Although pharmacologic modulation of noradrenaline, dopamine, and serotonin on motor behavior was demonstrated in healthy subjects and clinical studies, the effect of antiplatelet compound on motor activity is not discussed.

• Received; June 21, 2012 • Revised; August 3, 2012

• Accepted; August 8, 2012

Corresponding author : Yongmin Chang, Ph.D., Department of Molecular Medicine & Radiology, Kyungpook National University and Hospital, 50, Samduk-Dong 2ga, Chung-gu, Daegu 700-721, Korea.

Tel. 82-53-420-5471, Fax. 82-53-422-2677

E-mail : ychang@knu.ac.kr

An antiplatelet drug is a member of a class of drug that decreases platelet aggregation and inhibits thrombus formation (7, 8). They are effective in the arterial circulation, where anticoagulants have little effect and are widely used in primary and secondary prevention of thrombotic cerebrovascular or cardiovascular disease. Clopidogrel is a potent oral antiplatelet agent often used in the treatment of coronary artery disease, peripheral vascular disease, and cerebrovascular disease (9). The mechanism of action of clopidogrel is irreversible blockade of the adenosine diphosphate (ADP) receptor on platelet cell membranes (10). This receptor is named P2Y<sub>12</sub> and is important in platelet aggregation, the cross-linking of platelets by fibrin. The blockade of this receptor inhibits platelet aggregation by blocking activation of the glycoprotein I<sub>b</sub>/III<sub>a</sub> pathway.

In this study, the pharmacologic modulation of motor task-dependent physiologic responses by antiplatelet agent, clopidogrel, during hand motor tasks were investigated in healthy subjects. Since antiplatelet therapy is often used to improve brain perfusion, antiplatelet agent is potentially expected to be effective for preventing or recovering ischemic diseases such as stroke. Furthermore, the main symptom of stroke is motor weakness. Therefore, the motor task seems to be most relevant fMRI task to investigate pharmacologic modulation by clopidogrel. Effects on cerebral motor activity of high dose and steady state of clopidogrel were assessed separately by fMRI. Drug effects were assessed in three sessions in which the same subjects repeated the same motor task before and after drug administration. Each session is separated at least by 24 hours to avoid habituation effects which may take place in pharmacologic studies.

## MATERIALS AND METHODS

### Subjects

Ten healthy, right-handed subjects (10 males; mean age, 26 ± 5 years; range 24 to 28 years) participated in this study. Since there was no female volunteer, only male subjects were recruited in this study. None of the subjects had a previous history of neurological or cardiac disease or symptoms. After detailed explanation of the study design and potential risks, all subjects gave written informed consent. All study

protocols were approved by the local Internal Review Board.

### Motor Paradigm Design

The subjects were examined with their eyes closed and were secured firmly with the forearm in pronation using an immobilizing frame to minimize body movement effects. For the motor task paradigm, finger flexion-extension movements were performed at a frequency of 1 Hz for stimulation over a repeated cycle of 15 seconds of control and 15 seconds of stimulation. Each task paradigm of alternating control-stimulation (30 seconds) was repeated three times (three blocks). Total acquisition time was 1 minute 30 seconds. For the same subjects, the fMRI session was repeated three times: one (day 0) before drug administration, one (day 1) after high dose drug administration (20 mg/50 kg clopidogrel), and one (day 6) after reaching drug steady state. The fMRI scans were performed at the peak plasma concentrations for high dose session.

### Functional Magnetic resonance imaging

Blood oxygenation level dependent (BOLD) contrast was collected for each subject using a 3.0 T VHi (GE Healthcare, Milwaukee, USA) scanner equipped with a transmit-receive body coil and a commercial eight-element head coil array. T<sub>2</sub>\*-weighted echo planar imaging was used for fMRI acquisition. The following acquisition parameters were used in the fMRI protocol: echo time (TE) = 40 ms, repetition time (TR) = 2000 ms, field of view (FOV) = 22 cm, acquisition matrix = 64 × 64. Using a midsagittal scout image, 24 contiguous axial slices with 4 mm thickness were placed along the anterior-posterior commissure (AC-PC) plane covering the entire brain. The first three acquisitions were discarded due to T<sub>1</sub>-saturation effects. 3-D T<sub>1</sub>-weighted anatomical scan was obtained for structural reference.

### Image Analysis

The image processing and statistical analyses were carried out using MATLAB v. 7.2 (The Mathworks Inc., Natick, MA) and SPM2 (SPM; Wellcome Department of Imaging Neuroscience, London, UK; online at <http://www.fil.ion.ucl.ac.uk>) (11). The functional images were corrected for sequential slice timing, and all images were realigned to the first image to correct

for head movement between scans. The realigned images were then mean-adjusted by proportional scaling and spatially normalized into standard stereotactic space to fit a Montreal Neurological Institute template based on the standard stereotaxic coordinate system (12, 13). For group analysis, the contrast images from the analysis of the individual subjects were analyzed by one-sample *t*-tests, thereby generating a random-effects model, allowing inference to the general population. A statistical threshold was assessed based on the spatial extent of the contiguous activity ( $p < 0.05$  with correction for multiple comparisons with 16-contiguous voxel size). Clusters of fewer than 16 voxels were ignored. Finally, the resulting activation maps were created and displayed by projections onto the anatomically standardized mean T1 image of all subjects to identify the anatomical correlates of the activity.

## RESULTS

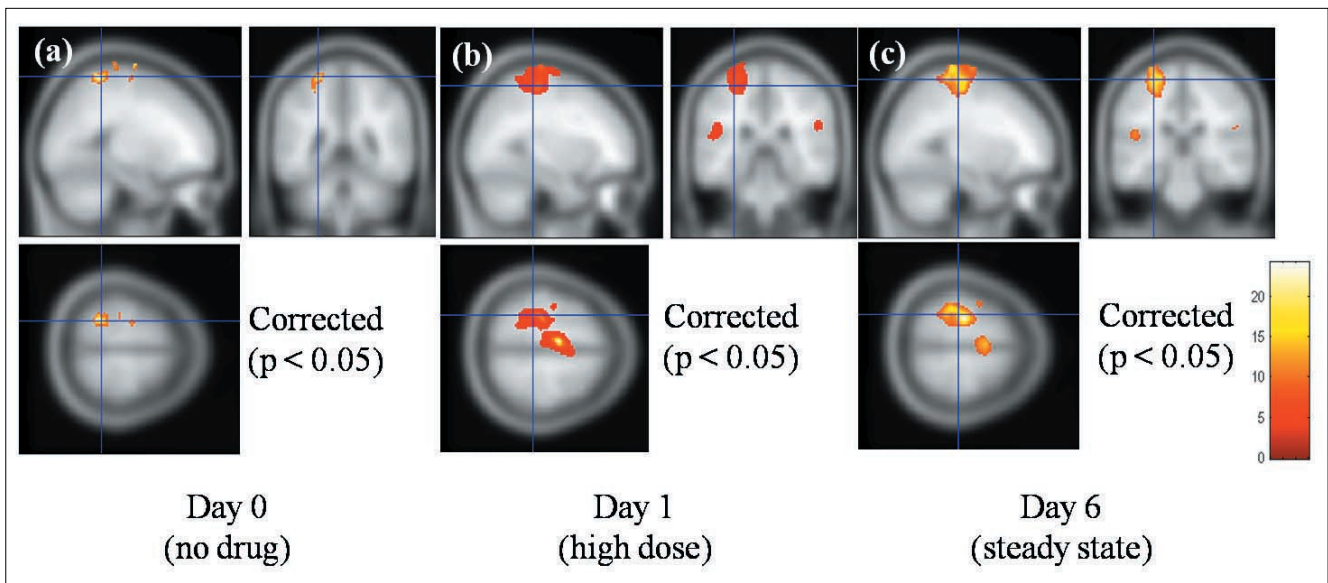
Compared to the base-line activity without drug administration, the second-level analysis, which corrected for multiple comparisons ( $p < 0.05$ ), for right hand motor task revealed significant increases in the extent of activation in the contralateral motor cortex including primary motor area (M1) after drug administration (Fig. 1). The number of activated voxels

in motor cortex (precentral and postcentral gyrus) was 173 without drug administration and the number increased as 1049 for high dose condition and 673 for steady-state condition respectively. However, there was no significant difference in the magnitude of BOLD signal change in terms of peak T value.

Whole-brain, voxel-by-voxel analyses revealed one additional motor-related region that was activated during drug sessions (day 1 and 6) with the administration of clopidogrel. This region was located in the supplementary motor area (SMA). In addition, the other areas, which showed significant activation after clopidogrel administration, were cerebellum, superior temporal gyrus, and middle frontal gyrus (Table 1). Comparison between steady-state (day 6) and high dose condition (day 1) showed that the activations of motor cortex and SMA were more extended in high dose condition. It was also noticed that cerebellum activity was more significant both in extent (activated voxels = 1486) and magnitude (peak T = 17.45) in high dose condition.

## DISCUSSION

In the present study, the effects of clopidogrel during motor task were investigated. The findings indicate that pharmacologically induced motor activity produced a regionally specific alteration in the pattern



**Fig. 1.** Brain activation maps by right motor task before and after Clopidogrel administration. Left side of the figure corresponds to the left hemisphere.

**Table 1. Significant Regional Brain Activity in no Drug (Day 0), High Dose (Day 1), and Steady-state (Day 6) Condition**

State	Region	Cluster size	Coordinates(mm)			Peak T
			x	y	z	
Day 0	Postcentral Gyrus	133	-18	-52	70	11.41
	Superior Frontal Gyrus	20	-20	-12	72	12.89
	Precentral Gyrus	40	-22	-12	76	9.63
Day 1	Medial Frontal Gyrus	595	-6	-8	58	24.19
	Precentral Gyrus	579	-26	-28	74	11.86
	Postcentral Gyrus	470	-24	-38	64	11.81
	Middle Frontal Gyrus	108	-14	-12	62	6.88
	Cerebellum	1486	4	-70	-16	17.45
	Superior Temporal Gyrus	240	-46	6	-4	9.30
	Insula	401	36	8	6	8.82
	Postcentral Gyrus	335	60	-20	30	6.64
	Day 6	Precentral Gyrus	673	-32	-34	66
	Middle Frontal Gyrus	342	-22	-10	74	9.53
	Superior Temporal Gyrus	158	-56	4	0	10.37
	Medial Frontal Gyrus	279	-10	-12	56	8.64
	Supramarginal Gyrus	39	52	-30	24	8.15
	Cerebellum	280	18	-54	-28	8.46

of fMRI activation during high dose (day 1) and steady-state (day 6) sessions. An increase in both the extent and magnitude of activation was observed primarily in the motor cortex and SMA. To exclude the possibility that the observed pharmacological modulation on motor activity is within false positive error (type I), group analysis with multiple comparison correction was introduced. In fMRI studies, data analysis is usually done voxel-wise with all statistical tests conducted separately and simultaneously. Although these voxel-by-voxel tests increase the precision of the conclusions in terms of cluster size, a family of statistical tests suffer at least type I error (false positive), which is greater than that of an error on an individual test (14, 15). Therefore, it was adapted a policy that the observed neural activation is not by chance but really related to the pharmacological effect of clopidogrel even though there is a chance to miss some voxels with true activation (false negative).

Although there were previous neuroimaging studies that have shown regional alterations in activation

associated with pharmacologic manipulation (16, 17), the current findings are the first demonstration of the cerebral pattern induced by an action of antiplatelet drug such as clopidogrel on motor activity. Clopidogrel induced an enhanced activation of primary motor and SMA at the concentrations used in this study by suggesting the pharmacological role in motor control. Moreover, in this study, it was not observed statistically significant difference in magnitude and extent of activation between high dose (day 1) and steady-state (day 6) sessions. The enhanced motor performance and efficiency of information processing in simple motor task has been demonstrated after the administration of fluvoxamine, the inhibitor of serotonin reuptake (18).

For the interpretation of pharmacologic modulation of clopidogrel on motor activity, there seem to be two possibilities. One possibility depends on the global increase in the cerebral perfusion. Tokumaru et al demonstrated a marked improvement in brain perfusion after treatment with an antiplatelet agent (8). In their study, using brain single photon emission

computed tomography (SPECT), they observed that antiphospholipid antibody syndrome patients subsequently recovered from repeated transient ischemic attack after antiplatelet (aspirin) therapy with remarkable improvement of cerebral perfusion. Based on their observation, motor stimuli should evoke greater activation in motor-related brain areas than other brain area because neurons in motor-related areas received relatively large amount of blood supply compared to neurons in other areas. In this study, any pharmacologic effect on activation in other cortical or subcortical areas was not observed suggesting that drug effect is responsible for motor task-dependent BOLD response. A second possibility may arise from the antiplatelet effect of clopidogrel on BOLD mechanism. The blockade of P2Y<sub>12</sub> receptor on platelet membrane by clopidogrel inhibits platelet aggregation and thus can change dephasing effect of water molecule inside blood vessel. The change of water diffusion by inhibition of platelet aggregation can modulate the degree of dephasing of water molecules. Since BOLD signal is sensitive to the change of dephasing (19, 20), the antiplatelet effect of clopidogrel therefore modulates the extent and the magnitude of BOLD signal. However, on this explanation, further study is necessary to investigate whether global change in the water diffusion produced not only an increase in baseline BOLD signal but also an additive increase of BOLD response.

Finally, it is necessary to address limitation of this study. The current study did not include placebo session. In pharmacological study, the placebo session might have an importance because it presumably reflects psychological effect on the fMRI activation. That is, without placebo session, it is difficult to rule out that the observed BOLD activation is not from psychological effect.

In conclusion, the current study demonstrated, for the first time, that cerebral motor activity can be modulated by clopidogrel in healthy subjects and that fMRI is highly sensitive to evidence such changes. These results showed that clopidogrel induced profound changes in the primary motor cortex and SMA.

#### Acknowledgements:

This work was supported by the Ministry of Health & Welfare, KOREA (A092106).

#### References

1. Kimberg D, Aguirre G, Lease J, D'Esposito M. Cortical effects of bromocriptine, a D-2 dopamine receptor agonist, in human subjects, revealed by fMRI. *Hum Brain Mapp* 2001;12:246-257
2. Honey G, Bullmore E, Soni W, Varatheesan M, Williams S, Sharma T. Differences in frontal cortical activation by a working memory task after substitution of risperidone for typical antipsychotic drugs in patients with schizophrenia. *Proc Natl Acad Sci USA* 1999;96:13432-13437
3. Braus D, Ende G, Weber-Fahr W, et al. Antipsychotic drug effects on motor activation measured by functional magnetic resonance imaging in schizophrenic patients. *Schizophr Res* 1999;39:19-29
4. Loubinoux I, Boulanouar K, Ranjeva J-P, et al. Cerebral functional magnetic resonance imaging activation modulated by a single dose of the monoamine neurotransmission enhancers fluoxetine and fenozolone during hand motor tasks. *J Cereb Blood Flow Metab* 1999;19:1365-1375
5. Goldstein L, Coviello A, Miller G, Davis J. Norepinephrine depletion impairs motor recovery following sensorimotor cortex injury in the rat. *Restor Neurol Neurosci* 1991;3:41-47
6. Goldstein L. Common drugs may influence motor recovery after stroke. *Neurology* 1995;45:865-871
7. Gubitz G, Sandercock P, Counsell C. Antiplatelet therapy for acute ischemic stroke. In: *The Cochrane Library*, Issue 1, 2000. Oxford
8. Tokumaru S, Yoshikai T, Uchino A, Matsui M, Kuroda Y, Kudo S. Technetium-99m-ECD SPECT in antiphospholipid antibody syndrome: a drastic improvement in brain perfusion by antiplatelet therapy. *Eur Radiol* 2001;11:2611-2615
9. Chan F, Ching J, Hung L, et al. Clopidogrel versus aspirin and esomeprazole to prevent recurrent ulcer bleeding. *New Engl J Med* 2005;352:238-244
10. Herbert JM, Savi P. P2Y<sub>12</sub>, a new platelet ADP receptor, target of clopidogrel. *Semin Vasc Med* 2003;3:113-122
11. Friston K, Holmes A, Worsley K, Poline J, Frith C, Frackowiak R. Statistical parametric maps in functional imaging: a general linear approach. *Hum Brain Mapp* 1995;2:189-210
12. Evans A, Collins D, Mills S, Brown E, Kelly R, Peters T. 3D statistical neuroanatomical models from 305 MRI volumes. *Proc. IEEE-Nucl. Sci. Symp. Med. Imaging* 1993;1813-1817
13. Talairach J, Tournoux P. *Co-Planar Stereotaxic Atlas of the Human Brain*. Thieme, 1988, New York
14. Hochberg Y, Tamhane A. *Multiple comparisons procedures*. Wiley, 1987, New York
15. Worsley K, Marrett S, Neelin P, Vandal A, Friston K, Evans A. A unified statistical approach for determining significant voxels in images of cerebral activation. *Hum Brain Mapp* 1996;4:58-73
16. Mintzer M, Griffiths R.R. Acute dose-effects of scopolamine on false recognition. *Psychopharmacology* 2001;153:425-433
17. Bozzali M, MacPherson SE, Dolan RJ, Shallice T. Left prefrontal cortex control of novel occurrences during recollection: a psychopharmacological study using scopolamine and event-related fMRI. *Neuroimage* 2006;33:286-295
18. Hasbroucq T, Rihet P, Blin O, Possamai C. Serotonin and human information processing: fluvoxamine can improve reaction time performance. *Neurosci Lett* 1997;229:204-208
19. Weisskoff R, Zuo C, Boxerman J, Rosen B. Microscopic susceptibility variation and transverse relaxation: theory and experi-



## 운동과제에 대한 클로피도그렐의 약리적 뇌자기공명영상

<sup>1</sup>경북대학교 의학전문대학원 분자의학교실

<sup>2</sup>경북대학교 대학원 의용생체공학과

<sup>3</sup>경북대학교병원 영상의학과

장 용 민<sup>1-3</sup>

**목적:** 정상인에서 항혈소판제제인 클로피도그렐이 손운동기능 과제를 수행하는 동안 운동기능의 생리학적 반응에 대한 약리적 조절효과를 알아보려고 하였다.

**대상과 방법:** 10명의 오른손잡이 정상인을 대상으로 클로피도그렐 사용전, 최대 복용량 복용후, 정상상태 유지시로 세번에 걸쳐 뇌기능 자기공명영상 데이터를 획득하였다. 운동과제로는 주먹을 쥐었다 폄다하는 운동을 시행하였고 3.0 테슬라 자기공명영상기기에서 혈액산소의존성(BOLD) 대조도를 획득하였으며 이를 위하여 T2\* 강조 EPI 영상 기법을 사용하였다. 뇌기능 자기공명영상 데이터의 영상전처리 및 통계분석은 SPM2를 사용하였다.

**결과:** 이차수준 분석에서 주운동영역을 포함하는 편측 감각운동중추의 활성화가 나타났다. 클로피도그렐 사용전의 활성화 화소수는 173, 최대 복용량 복용후 활성화 화소수는 1049, 정상상태 유지시 활성화 화소수는 673 이었다. 최대 T값을 기준으로 측정된 BOLD 신호의 강도변화는 관찰되지 않았다.

**결론:** 본 연구결과는 클로피도그렐에 의해 대뇌 운동 활성이 조절된다는 사실과 또한 뇌기능 자기공명영상이 이러한 변화를 감지할수 있을만큼 높은 민감성을 가진다는 사실을 제안하고 있다.

통신저자 : 장용민, (700-721) 대구광역시 중구 삼덕동2가 50, 경북대학교병원 분자의학교실 및 영상의학과  
Tel. (053) 420-5471 Fax. (053) 422-2677 E-mail: ychang@knu.ac.kr