

Case Report

Syringo-Subarachnoid-Peritoneal Shunt Using T-Tube for Treatment of Post-Traumatic Syringomyelia

Seon-Hwan Kim, M.D., Ph.D.,¹ Seung-Won Choi, M.D., Ph.D.,^{1,2} Jin-Young Youm, M.D., Ph.D.,¹ Hyon-Jo Kwon, M.D.¹

Department of Neurosurgery,¹ School of Medicine, Brain Research Institute,² Chungnam National University, Daejeon, Korea

Various surgical procedures for the treatment of post-traumatic syringomyelia have been introduced recently, but most surgical strategies have been unreliable. We introduce the concept and technique of a new shunting procedure, syringo-subarachnoid-peritoneal shunt. A 54-year-old patient presented to our hospital with a progressive impairment of motion and position sense on the right side. Sixteen years before this admission, he had been treated by decompressive laminectomy for a burst fracture of L1. On his recent admission, magnetic resonance (MR) imaging studies of the whole spine revealed the presence of a huge syrinx extending from the medulla to the L1 vertebral level. We performed a syringo-subarachnoid-peritoneal shunt, including insertion of a T-tube into the syrinx, subarachnoid space and peritoneal cavity. Clinical manifestations and radiological findings improved after the operation. The syringo-subarachnoid-peritoneal shunt has several advantages. First, fluid can communicate freely between the syrinx, the subarachnoid space, and the peritoneal cavity. Secondly, we can prevent shunt catheter from migrating because dural anchoring of the T-tube is easy. Finally, we can perform shunt revision easily, because only one arm of the T-tube is inserted into the intraspinal syrinx cavity. We think that this procedure is the most beneficial method among the various shunting procedures.

Key Words : Syringomyelia · Spinal cord injury · Shunt.

INTRODUCTION

Syringomyelia is a disease that produces fluid-containing cavities in the parenchyma of the spinal cord. Syringomyelias are mainly divided into hindbrain-related and nonhindbrain-related forms. Chiari type I malformation with a herniation of the cerebellar tonsil through the foramen magnum is the most frequent form, and post-traumatic syringomyelia is the most common nonhindbrain-related form of this condition.

Various surgical procedures for the treatment of post-traumatic syringomyelia have been introduced recently. Depending on the cause and type of syringomyelia, the procedures chosen to correct this condition include posterior fossa decompression, spinal subarachnoid space reconstruction, bisecting the filum terminale, spinal cord transection, myelotomy, and various cerebrospinal fluid (CSF) diversion procedures, such as lumbo-peritoneal, syringe-pleural, syringe-subarachnoidal, and syringe-peritoneal shunting^{4,7,14}. However, most surgical strategies have been unreliable, especially in cases of shunt procedures.

We introduce the concept and technique of a new shunting

procedure : syringo-subarachnoid-peritoneal shunt.

CASE REPORT

A 54-year-old patient presented to our hospital with a 5-day history of progressive impairment of motion and position sense on the right side. Sixteen years before this admission, he had been treated by a decompressive laminectomy against a burst fracture of L1, and has suffered from incomplete paraplegia. Five days before his recent admission, he was in a minor traffic accident. Afterwards, an impairment of his motion and position sense developed on the right lower extremity which has gradually aggravated to the right upper extremity.

His neurological examinations revealed impairment of all sensory functions including motion and position sense on his right side, and a newly developed motor weakness of the right upper extremity (Grade IV). He complained of paresthesia on his whole right side. MR images of the whole spine revealed the presence of a huge syrinx extending from the medulla to the L1 level (Fig. 1). No evidence of hindbrain herniation or hydro-

• Received : August 1, 2011 • Revised : April 25, 2012 • Accepted : June 12, 2012

• Address for reprints : Seung-Won Choi, M.D., Ph.D.

Department of Neurosurgery, School of Medicine, Chungnam National University, 282 Munhwa-ro, Jung-gu, Daejeon 301-721, Korea

Tel : +82-42-280-7361, Fax : +82-42-280-7363, E-mail : swchoi@cnu.ac.kr

• This is an Open Access article distributed under the terms of the Creative Commons Attribution Non-Commercial License (<http://creativecommons.org/licenses/by-nc/3.0>) which permits unrestricted non-commercial use, distribution, and reproduction in any medium, provided the original work is properly cited.

cephalus was revealed.

We performed the syringo-subarachnoid-peritoneal shunting procedure with T-tube (CSF-Lumboperitoneal Shunt, T-tube; Medtronic Neurosurgery, Goleta, CA, USA). The patient was placed in a prone position. We choose T9 vertebral level for the myelotomy site, because it was the widest portion of syrinx, the thinnest portion of the spinal cord and the least potential site for a new neurological deficit. After the T9 laminectomy, incision of dura and arachnoid membrane, we made a small myelotomy at the dorsal root entry zone. The T-tube arms which have many side holes, are cut to the desired length and one arm is inserted into the syrinx (rostral direction), the other arm into subarachnoid space (caudal direction) (Fig. 2). After a tight suture of the dura, fascia and skin, we passed the distal tip through subcutaneous space, and connected to the reservoir in the subcutaneous pocket at a costovertebral angle. After positioning the patient in a supine position, we inserted a peritoneal catheter into the peritoneal cavity using the standard technique.

On his neurological examination 6 months after the operation, motor power of the right upper extremity was normalized, and sensory function, including proprioceptive sense, was markedly improved except for the right fingers. Several magnetic resonance (MR) images performed during two years after surgery have shown a considerable reduction in the size of the syringomyelic cavity (Fig. 3).

DISCUSSION

The goal of surgery for syringomyelia should be to reverse any anatomical abnormality that is presumed to have caused the syrinx. The hydrodynamic theory, based on Gardner⁶⁾ and Williams⁸⁾, states that CSF pressure gradients between the cranium and the spine in patients with hindbrain herniation allow for the development of a syrinx as CSF is drawn into the more yielding areas of the spinal cord. Therefore, the procedure of choice in this hindbrain-related syringomyelia is posterior fossa exploration for hindbrain decompression.

After trauma, spinal injury produces numerous abnormalities, such as subarachnoid adhesions, spinal deformity or stenosis that could disturb CSF flow and contribute to syrinx enlargement. The presence of uncorrected kyphosis and stenosis correlate with syrinx formation and symptom severity^{8,10-12)}, and subarachnoid adhesion results in obstruction of CSF pathways⁵⁾. Therefore, subarachnoid space reconstruction from correction of causative deformity, decompression of the spinal cord, or adhesiolysis of subarachnoid scarring and duroplasty should be considered preferentially to diversion of CSF flow^{1,4,14)}.

Shunt operations were widely used in the 1970s and 1980s with encouraging early results, although long-term effectiveness has been questioned recently. Various cerebrospinal fluid diversion procedures, such as syringe-subarachnoid, theco-peritoneal, syringe-pleural, and syringe-peritoneal shunting have been introduced recently, but most have been unreliable and

have limitations^{2,3,9,13,15,16)}. Sgouros and Williams observed that a large proportion of patients with syringe-pleural shunts needed subsequent surgery within one year. They also observed a high number of postoperative neurological complications¹³⁾, Batzdorf

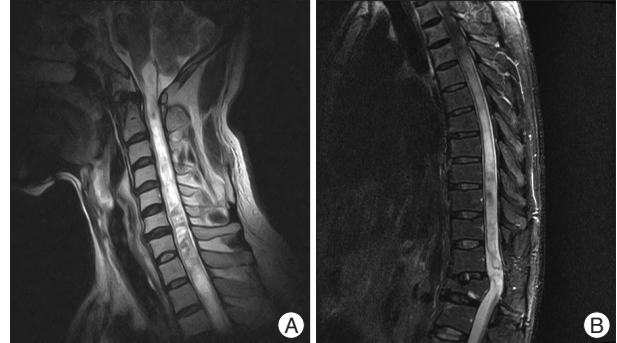


Fig. 1. Magnetic resonance images of the cervical (A) and thoracic spine (B) reveal the presence of a huge syrinx extending from the medulla to the L1 level.

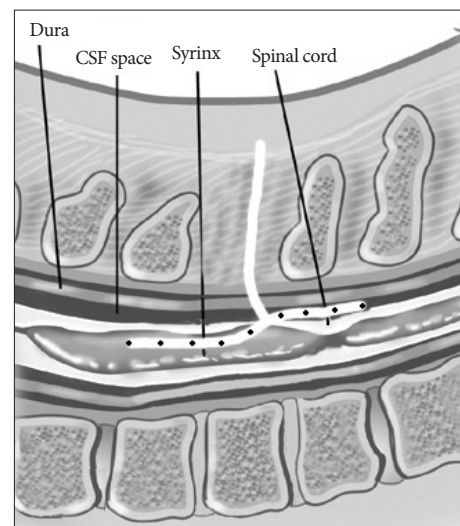


Fig. 2. Schematic diagram showing the technique of syringo-subarachnoid-peritoneal shunt. The T-tube arms which have many side holes, are cut to the desired length and one arm is inserted into the syrinx (rostral direction), the other arm into subarachnoid space (caudal direction). CSF : cerebrospinal fluid.

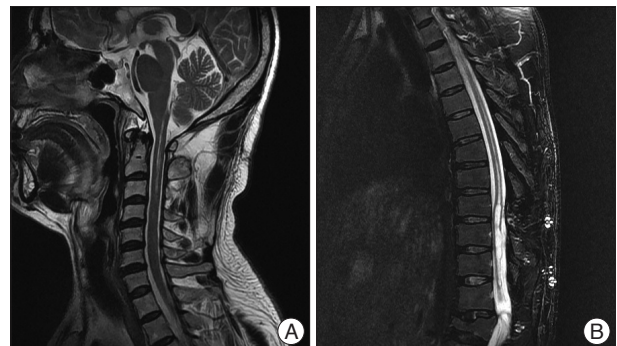

Fig. 3. Postoperative magnetic resonance images of cervical (A) and thoracic (B) at 27 months after the surgery show considerable reduction in the size of the syringomyelic cavity.

reported a higher rate of shunt failure (approximately 50%) and poor long-term outcome from his various shunting procedures including syringe-peritoneal shunt, syringo-pleural shunt, subarachnoid shunt and lumbo-peritoneal shunt³). Most recently, Aghakhani et al.¹⁾ reported a considerable number of recurrences (73%), and aggravation of symptoms (40%) after the shunting procedure, for a mean follow-up of 86 months.

The main cause of the high recurrence rate and poor outcome after shunting procedure is shunt obstruction^{1,3)}. It is probably most often the result of the collapse of the syrinx cavity around a shunt tip. Batzdorf identified proximal obstruction as the most common source of shunt malfunction, and demonstrated ingrowth of glial tissue into the perforations of the tube as the cause of shunt failure³⁾. We tried to overcome the proximal obstruction by using a T-tube having many side holes on its two arms. Some authors used the T-tube in the past, but their techniques had some limitations^{2,9,17)}. One is the fact that the rotational forces of the T-tube can damage the spinal cord. The other limitation is the difficulty in removing the T-tube without cord injury, when there are complications such as obstruction, infection or cord compression. However, in our new shunting procedure, we inserted just one arm of the T-tube into the syrinx cavity and located the other arm outside the cord, in the subarachnoid space. Therefore, we can not only protect the cord from tube rotation, but also remove the tube easily.

The linear catheter used in various shunting procedures also has some limitations. Another main cause of shunt malfunction is shunt dislocation, frequently occurring in syringostomy or syringosubarachnoidal shunt using the linear catheter. However, using T-tube has another advantage : we can easily anchor the tube to the dura, and thus prevent migration resulting in shunt malfunction (Fig. 2).

The greatest advantage of our method is that there are free connections between the three spaces : syrinx, subarachnoid space, and the peritoneal cavity. CSF can flow from syrinx to subarachnoid space and peritoneal space or from subarachnoidal space to peritoneal cavity according to the pressure gradient. Our shunt system can theoretically operate as syringe-subarachnoidal shunt, syringe-peritoneal shunt and theco-peritoneal shunt.

Currently, subarachnoid space reconstruction by combining arachnolysis and duroplasty appears to be one best treatment in posttraumatic syringomyelia. Shunt placement may be elected when other causative treatments have failed, when adhesiolysis is impossible due to extensive adhesion, or when combined with subarachnoid space reconstruction. If it is needed, we recommend the syringo-subarachnoid-peritoneal shunt operation.

CONCLUSION

The syringo-subarachnoid-peritoneal shunt using T-tube has many advantages and makes up for the defects of other shunts. First, fluid can communicate freely between the syrinx, the sub-

arachnoid space, and the peritoneal cavity according to the pressure gradient. Secondly, we can prevent the shunt catheter from migrating because dural anchoring of the T-tube is easy and solid. Finally, we can perform shunt revision easily because only one arm of the T-tube is inserted into the intraspinal syrinx cavity. The treatment of choice is subarachnoid space reconstruction and augmentation in posttraumatic syringomyelia, but, when a shunt is needed, we think that this procedure is the most beneficial method among the various shunting procedures.

• Acknowledgements

This study was financially supported by research fund of Chungnam National University in 2010.

References

- Aghakhani N, Baussart B, David P, Lacroix C, Benoudiba F, Tadie M, et al. : Surgical treatment of posttraumatic syringomyelia. *Neurosurgery* 66 : 1120-1127; discussion 1127, 2010
- Barbaro NM, Wilson CB, Gutin PH, Edwards MS : Surgical treatment of syringomyelia. Favorable results with syringoperitoneal shunting. *J Neurosurg* 61 : 531-538, 1984
- Batzdorf U, Klekamp J, Johnson JP : A critical appraisal of syrinx cavity shunting procedures. *J Neurosurg* 89 : 382-388, 1998
- Brodholt AR, Stoodley MA : Post-traumatic syringomyelia : a review. *J Clin Neurosci* 10 : 401-408, 2003
- Cho KH, Iwasaki Y, Imamura H, Hida K, Abe H : Experimental model of posttraumatic syringomyelia : the role of adhesive arachnoiditis in syrinx formation. *J Neurosurg* 80 : 133-139, 1994
- Gardner WJ : Hydrodynamic factors in Dandy-Walker and Arnold-Chiari malformations. *Childs Brain* 3 : 200-212, 1977
- Goel A, Desai K : Surgery for syringomyelia : an analysis based on 163 surgical cases. *Acta Neurochir (Wien)* 142 : 293-301; discussion 301-302, 2000
- Lee TT, Alameda GJ, Camilo E, Green BA : Surgical treatment of post-traumatic myelopathy associated with syringomyelia. *Spine (Phila Pa 1976)* 26 : S119-S127, 2001
- Lund-Johansen M, Wester K : Syringomyelia treated with a nonvalved syringoperitoneal shunt : a follow-up study. *Neurosurgery* 41 : 858-864; discussion 864-865, 1997
- Perrouin-Verbe B, Lenne-Aurier K, Robert R, Auffray-Calvier E, Richard I, Mauduyt de la Grève I, et al. : Post-traumatic syringomyelia and post-traumatic spinal canal stenosis : a direct relationship : review of 75 patients with a spinal cord injury. *Spinal Cord* 36 : 137-143, 1998
- Schaller B, Minderhann T, Gratzl O : Treatment of syringomyelia after posttraumatic paraparesis or tetraparesis. *J Spinal Disord* 12 : 485-488, 1999
- Schurich B, Wichmann W, Rossier AB : Post-traumatic syringomyelia (cystic myelopathy) : a prospective study of 449 patients with spinal cord injury. *J Neurol Neurosurg Psychiatry* 60 : 61-67, 1996
- Sgouros S, Williams B : A critical appraisal of drainage in syringomyelia. *J Neurosurg* 82 : 1-10, 1995
- Sgouros S, Williams B : Management and outcome of posttraumatic syringomyelia. *J Neurosurg* 85 : 197-205, 1996
- Vassilouthis J, Papandreou A, Agagnostaras S : Theco-peritoneal shunt for post-traumatic syringomyelia. *J Neurol Neurosurg Psychiatry* 57 : 755-756, 1994
- Vengsarkar US, Panchal VG, Tripathi PD, Patkar SV, Agarwal A, Doshi PK, et al. : Percutaneous theco-peritoneal shunt for syringomyelia. Report of three cases. *J Neurosurg* 74 : 827-831, 1991
- Wester K, Pedersen PH, Kråkenes J : Spinal cord damage caused by ro-

tation of a T-drain in a patient with syringoperitoneal shunt. *Surg Neurol* 31 : 224-227, 1989

18. Williams B : Cerebrospinal fluid pressure-gradients in spina bifida cys-

tica, with special reference to the Arnold-Chiari malformation and aqueductal stenosis. *Dev Med Child Neurol Suppl* : 138-150, 1975