

## Correlation of panoramic radiographs and cone beam computed tomography in the assessment of a superimposed relationship between the mandibular canal and impacted third molars

Yun-Hoa Jung, Kyung-Soo Nah, Bong-Hae Cho

Department of Oral and Maxillofacial Radiology, College of Dentistry, Pusan National University, Yangsan, Korea

### ABSTRACT

**Purpose:** This study evaluated the association between cone beam computed tomography (CBCT) and panoramic radiographs in the assessment of a superimposed relationship between the mandibular canal and impacted third molars.

**Materials and Methods:** The study samples consisted of 175 impacted third molars from 131 patients who showed a superimposed relationship between the mandibular canal and third molars on panoramic radiographs and were referred for the examination of the mandibular canal with CBCT. Panoramic images were evaluated for the darkening of the root and the interruption of the mandibular canal wall. CBCT images were used to assess the buccolingual position of the mandibular canal relative to the third molar, the proximity of the roots to the canal, and lingual cortical bone loss. The association of the panoramic and CBCT findings was examined using a Chi-square test and Fisher's exact test.

**Results:** Panoramic radiographic signs were statistically associated with CBCT findings ( $P < 0.01$ ). In cases of darkening roots, lingual cortical bone loss or buccally positioned canals were more frequent. In cases in which the mandibular canal wall was interrupted on panoramic radiographs, contact or lingually positioned canals were more frequent.

**Conclusion:** The results of this study suggest that contact between the mandibular third molar and canal and a lingually positioned canal could be more frequently observed in cases of the interruption of the white line of the mandibular canal and that there could be more lingual cortical loss in cases of darkening roots. (*Imaging Sci Dent* 2012; 42 : 121-7)

**KEY WORDS:** Mandibular Nerve; Molar, Third; Radiography, Panoramic; Cone-Beam Computed Tomography

### Introduction

The surgical extraction of third molars is one of the most common procedures in dentoalveolar surgery, and several complications can occur postoperatively. It has been found that an impacted third molar is the main cause of permanent inferior alveolar nerve sensory deficiency, outweigh-

ing both implants and orthognathic surgery as etiologic factors.<sup>1</sup> A preoperative evaluation of the exact relationship between the roots of the mandibular third molar and the inferior alveolar nerve (IAN) would help in predicting, and possibly avoiding sensory impairment.<sup>2</sup> It has been shown that when a close relationship between the third molar and the mandibular canal is observed radiographically, the risk of IAN injury is higher than otherwise.<sup>3</sup>

The panoramic radiograph is a useful screening tool for assessing the anatomical relationship between the third molars and the IAN.<sup>4</sup> Although panoramic radiography is one of the most effective and widely used dental radiographic tools for evaluating the risk of nerve damage, the

\*This work was supported for 2 years by Pusan National University Research Grant. Received January 28, 2012; Revised February 20, 2012; Accepted March 4, 2012  
Correspondence to : Prof. Bong-Hae Cho  
Department of Oral and Maxillofacial Radiology, Pusan National University Dental Hospital, Beomeo-ri, Mulgeum-eup, Yangsan-si, Gyeongsangnam-do 626-787, Korea  
Tel) 82-55-360-5261, Fax) 82-55-360-5029, E-mail) bhjo@pusan.ac.kr

absence of the cortical bone of the mandibular canal may not be clearly evident with this method, and it is impossible to determine whether its course is buccal or lingual to the roots or between the roots.<sup>5,6</sup> Therefore, many studies have suggested risk factors for the close relationship between the tooth and the mandibular canal or IAN injury based on the findings from panoramic images.<sup>2,7,8</sup> Radiographic signs such as the darkening of the roots, the interruption of the white lines of the canal, the diversion of the canal, and the narrowing of the canal are associated with neurosensory disturbances or with a close relationship between the lower third molar and the mandibular canal.<sup>4,7</sup>

The darkening of the root has been previously described as an increased radiolucency due to the impingement of the canal on the third molar.<sup>7,9</sup> It has been pointed out that the darkening of the third molar root is one of the strongest signs of IAN exposure or paresthesia.<sup>10,11</sup> In contrast, it has been shown that the darkening of the root can even present as the evidence of thinning of the lingual cortical plate without root grooves.<sup>12</sup> The interruption of the cortical line of the canal on panoramic radiograph was related to the absence of cortical bone on computed tomography (CT) image.<sup>13</sup> It has been reported that the absence of the cortical bone of the canal was closely related to the exposure of IAN.<sup>14</sup>

However, various results in previous studies have been acquired in assessment of panoramic radiographic signs since the studies had included various relationships between the mandibular canal and root such as touching, partially overlapping, or superimposed canals. In cases of a superimposed relationship of the third molar and the mandibular canal, the absence of panoramic radiographic signs did not necessarily signify a separate relationship between the third molar and the inferior alveolar canal (IAC).<sup>15</sup> The prediction that can be made based on a close relationship

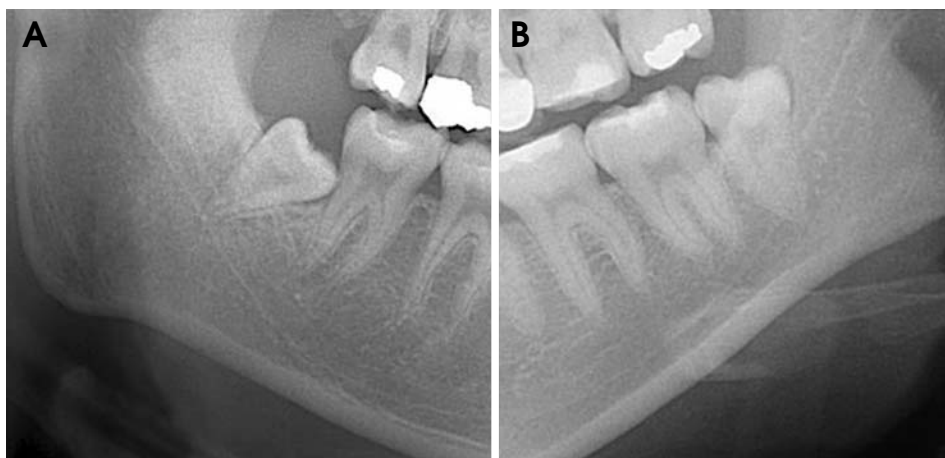
between the third molars and mandibular canal in a superimposed canal using panoramic radiographs has not been determined yet. Therefore, the present study was designed to reveal the predictive findings about the relationships between the third molars and mandibular canal when a superimposed relationship was observed on panoramic radiographs.

The aim of the present study was to evaluate the association between CBCT and panoramic radiographs in the assessment of a superimposed relationship of the mandibular canal and impacted third molars.

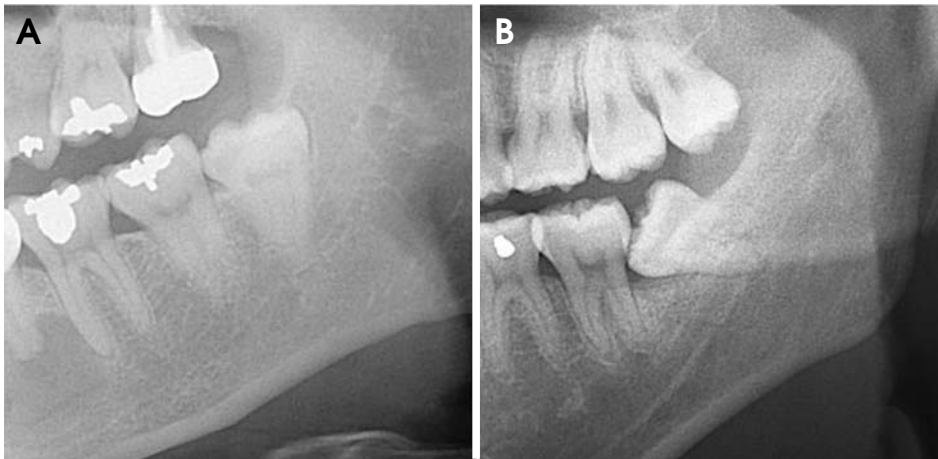
## Materials and Methods

Panoramic radiographs were randomly chosen from patients who visited Pusan National University Hospital between 2010 and 2011 for the extraction of lower third molars. The study samples consisted of 175 impacted third molars from 131 patients who showed a superimposed relationship of the mandibular canal and third molars on panoramic radiographs and were referred for the examination of the mandibular canal with CBCT in preparation for third molar extraction. The root tips of the subjects were superimposed with the mandibular canal and one of the root tips reached over the inferior cortical line of the canal. The patients comprised 57 males and 74 females and had a mean age of 29.3 years, ranging from 19 to 57 years. Subjects with displacement of the third molars due to pathology, such as cysts or tumors, were excluded from the study. Panoramic radiographs that did not allow a clear interpretation of the relationship of the third molar to the inferior alveolar canal were also excluded.

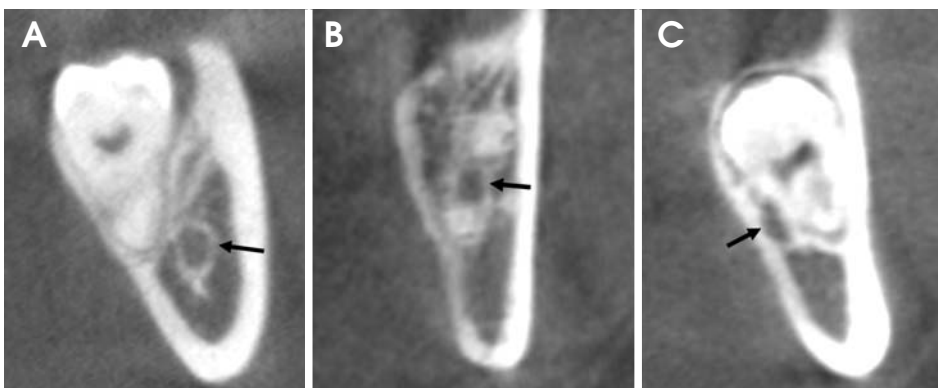
All of the panoramic radiographs were taken with a Proline XC (Planmeca Co., Helsinki, Finland). CBCT scans were acquired with a PaX-Zenith 3D (Vatech Co., Hwa-



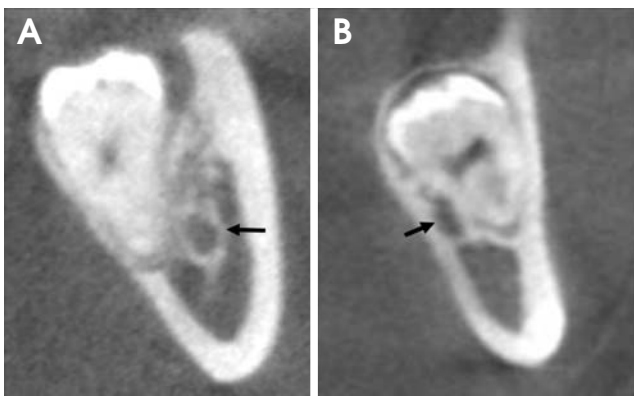
**Fig. 1.** A. Darkening of the root is actually the increased radiolucency of the root of the third molar where the mandibular canal crosses it on the panoramic radiograph. B. No darkening of the root is seen.



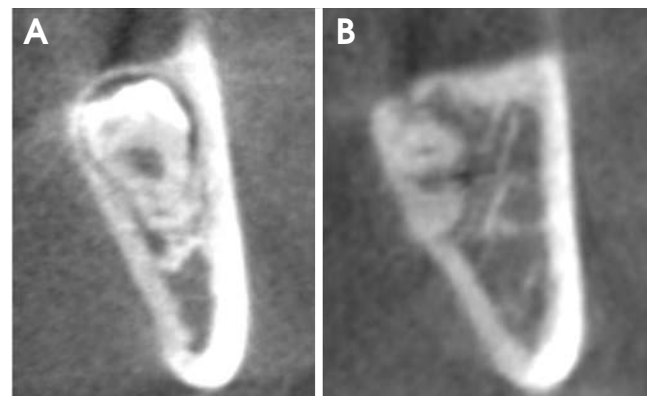
**Fig. 2.** A. Interruption of the mandibular canal wall appears at the border of the mandibular canal where it crosses the third molar on the panoramic radiograph. B. No interruption of the canal wall is seen.



**Fig. 3.** The position of the mandibular canal (black arrow) relative to the third molar root is classified as buccal (A), interradicular (B), or lingual (C).



**Fig. 4.** The proximity of the roots to the mandibular canal (black arrow) is classified as separate (A) or contact with canal (B).



**Fig. 5.** The lingual cortical bone loss was scored as complete lingual plate (A) or perforated lingual plate (B).

seong, Korea). The scanning parameters were 110 kVp, 24 seconds, 5.7 mA, voxel size 0.2 mm, and a field of view 16 cm × 14 cm. The CBCT data were reconstructed using Ez3D2009 CBCT software (Vatech Co., Hwaseong, Korea).

We examined two panoramic radiographic signs: the darkening of the root and the interruption of the mandibular canal wall.<sup>7</sup> The darkening of the root was actually the

increased radiolucency of the root of the third molar where the mandibular canal crossed it (Fig. 1). The interruption of the mandibular canal wall was the interruption of the radiopaque lines, which represented the border of the mandibular canal where it crossed the third molar (Fig. 2). The diversion and narrowing of the canal were not evaluated since they were rarely observed in a superimposed rela-

**Table 1.** The relationship between panoramic radiographic signs and the anatomic location of the canal relative to the third molar on CBCT images

		Lingual		Interradicular		Buccal		Total (N)
		N	%	N	%	N	%	
Darkening	Interruption	33	50.0	5	7.6	28	42.4*	66
	No interruption	6	10.2	1	1.7	52	88.1	59
No darkening	Interruption	28	87.5	0	0.0	4	12.5	32
	No interruption	7	38.9	0	0.0	11	61.1	18
Total		74	42.3	6	3.4	95	54.3	175

\*Fisher’s exact test,  $P < 0.01$

tionship between the third molar and the mandibular canal.

The CBCT images were evaluated in all three dimensions to assess the buccolingual position of the mandibular canal relative to the third molar, the proximity of the roots to the canal, and the lingual cortical bone loss. The position of the mandibular canal relative to the third molar root was classified as buccal, lingual, or interradicular (Fig. 3). The proximity of the roots to the canal was categorized into “separate” or “contact”: The “separate” indicates that bone tissue existed between the mandibular canal and the third molar and the “contact” indicates that no bone tissue existed between the mandibular canal and the third molar (Fig. 4). The lingual cortical bone loss was scored as “complete lingual plate” or “perforated lingual plate” (Fig. 5). The panoramic and CBCT images were evaluated independently to assess the relationship between the mandibular canal and the third molar by two oral and maxillofacial radiologists. The panoramic and CBCT images were reviewed twice by one of two oral and maxillofacial radiologists one month apart. The other oral and maxillofacial radiologist rated the panoramic and CBCT images independently once. When disagreement existed between the assessments of the two observers, a consensus was reached by discussion.

### Statistical analysis

Intraobserver and interobserver agreement were evaluated using kappa statistics. The kappa (k) values were calculated for interobserver agreement. Intraobserver agreement was high for the panoramic images and CBCT results, showing a k value of 0.782 for darkening, 0.871 for interruption, 0.978 for the buccolingual position of the canal, 0.929 for proximity, and 0.923 for lingual cortical loss. Interobserver reliability was also high: 0.716 for darkening, 0.835 for interruption, 0.956 for the buccolingual position of the canal, 0.906 for proximity, and 0.911 for lingual cortical loss.

We compared panoramic radiographic signs with the

**Table 2.** The relationship between panoramic radiographic signs and the proximity of the roots to the canal on CBCT

		Separate to canal		Contact with canal		Total (N)
		N	%	N	%	
Darkening	Interruption	18	27.3	48	72.7*	66
	No interruption	43	72.9	16	27.1	59
No darkening	Interruption	3	9.4	29	90.6	32
	No interruption	9	50.0	9	50.0	18
Total		73	41.7	102	58.3	175

\* $\chi^2$  test,  $P < 0.01$

relationship between the mandibular canal and impacted third molars using CBCT images. The association of panoramic and CBCT findings was analyzed using a Chi-square test and Fisher’s exact test. All of the analyses were carried out with PASW Statistics 18.0 (SPSS Inc., Chicago, IL, USA).

## Results

The panoramic radiographic signs were statistically associated with the buccolingual position of the mandibular canal relative to the third molar roots on CBCT ( $P < 0.01$ ). The buccally positioned canals were more frequent in cases of darkening and no interruption. A high percentage of cases of interruption and no darkening showed lingually positioned canals (Table 1).

The relationships between the panoramic radiographic signs and the proximity of the roots to the canal are shown in Table 2 ( $P < 0.01$ ). Contact with canal was more frequently observed when the interruption of the mandibular canal was seen on the panoramic radiographs. Separate to canals were more frequent in cases of darkening without interruption. Seventy-three cases (71.6%) of the contact with canals were lingually positioned relative to the mandibular third molar, and seventy-two cases (98.6%) of the

**Table 3.** The relationship between the buccolingual position and the proximity of the canal

	Separate to canal		Contact with canal		Total (N)
	N	%	N	%	
Lingual	1	1.4	73	71.6*	74
Interradicular	0	0.0	6	5.9	6
Buccal	72	98.6	23	22.5	95
Total	73	100.0	102	100.0	175

\*Fisher's exact test,  $P < 0.01$ **Table 4.** The relationship between panoramic radiographic signs and lingual cortical bone loss on CBCT

		Complete lingual cortex		Perforated lingual cortex		Total (N)
		N	%	N	%	
		Darkening	Interruption	20	30.3	
	No interruption	5	8.5	54	91.5	59
No darkening	Interruption	24	75.0	8	25.0	32
	No interruption	7	38.9	11	61.1	18
	Total	56	32.0	119	68.0	175

\* $\chi^2$  test,  $P < 0.01$ **Table 5.** The relationship between the buccolingual position of the mandibular canal and lingual cortical loss

	Complete lingual cortex		Perforated lingual cortex		Total (N)
	N	%	N	%	
Lingual	47	63.5	27	36.5*	74
Interradicular	1	16.7	5	83.3	6
Buccal	8	8.4	87	91.6	95
Total	56	32.0	119	68.0	175

\*Fisher's exact test,  $P < 0.01$ 

separate to canals were buccally positioned (Table 3,  $P < 0.01$ ).

Perforation of the lingual cortex was more frequently observed in the cases of darkening without the interruption of the cortical line. Complete lingual cortices were more frequently found in the cases with interruption and without darkening (Table 4,  $P < 0.01$ ). Lingual cortical loss was more frequent in buccally positioned canals than in lingually positioned canals (Table 5,  $P < 0.01$ ).

## Discussion

We examined the relationship between panoramic radiographic signs and CBCT findings in predicting the anatom-

ical position of deeply impacted third molars and canals on panoramic radiographs. The knowledge of the exact location of the IAN bundle is a very important factor since this information provides knowledge about regions where safe and quick removal of bone should be possible and danger zones where special care must be used.<sup>16</sup>

The IAN was more frequently exposed during third molar removal when the mandibular canal was positioned lingually to the third molar root rather than buccally.<sup>17</sup> When a surgeon knows that the IAN is positioned lingually, such injury can be prevented, for example, by luxating the crown in a lingual direction, thereby rotating the roots in the opposite direction from the mandibular canal.<sup>18</sup> In our study, lingually positioned canals were more frequently observed in cases with the interruption of the mandibular canal, and contact with canals were more frequent in cases of lingually positioned canals than in cases of buccally positioned canals.

It has been reported that the interruption of the mandibular canal wall was correlated with nerve exposure.<sup>19</sup> The results of the present study were consistent with those of previous studies in which the possibility of contact between the mandibular canal and the dental root was enhanced when the superior white line of the canal was invisible on panoramic radiographs.<sup>20</sup> In our results, contact with canals were more frequent in cases with interruption, and separate to canals were more frequent in cases without interruption.

Many studies analyzing panoramic imaging features have reported that the darkening of the third molar root where the mandibular canal was superimposed was strongly suggestive of an intimate relationship between the root and nerve, or nerve injury following third molar extraction.<sup>7,21-25</sup> Öhman et al<sup>26</sup> stated that a dark band on panoramic radiograph was an important indicator of the grooving of the tooth by the canal. Our results were not in agreement with their study. Instead, our results were in accordance with the report by Tantanapornkul et al<sup>12</sup> who mentioned that the darkening of the root reflected cortical thinning or perforation of the lingual cortical plate rather than the grooving of the tooth. In our results, 100 (80%) of 125 darkening cases showed lingual cortical loss. Mandibular lingual cortical bone loss around the root of the mandibular third molar may arise as a result of third molar development in association with mandibular growth.<sup>27</sup> It should be noted that the displacement of a tooth or root into the subperiosteal space through lingual cortical bone loss can occur during third molar removal.<sup>28</sup>

Our study showed that in cases of the darkening of roots without the interruption of the canals, there were more buc-

cally positioned and separate to canals, and lingual cortical loss. Also, in cases of the interruption of the canals without the darkening of the roots, lingually positioned and contact with canals and complete lingual cortices were more frequently observed.

In conclusion, the close and lingually positioned canals to the mandibular third molar could be more frequently observed in cases of the interruption of the white line of the mandibular canal, and there could be more lingual cortical perforation in cases of the darkening of the roots.

## References

1. Libersa P, Savignat M, Tonnel A. Neurosensory disturbances of the inferior alveolar nerve: a retrospective study of complaints in a 10-year period. *J Oral Maxillofac Surg* 2007; 65 : 1486-9.
2. Flygare L, Ohman A. Preoperative imaging procedures for lower wisdom teeth removal. *Clin Oral Investig* 2008; 12 : 291-302.
3. Jerjes W, Upile T, Shah P, Nhembe F, Gudka D, Kafas P, et al. Risk factors associated with injury to the inferior alveolar and lingual nerves following third molar surgery-revisited. *Oral Surg Oral Med Oral Pathol Oral Radiol Endod* 2010; 109 : 335-45.
4. Blaeser BF, August MA, Donoff RB, Kaban LB, Dodson TB. Panoramic radiographic risk factors for inferior alveolar nerve injury after third molar extraction. *J Oral Maxillofac Surg* 2003; 61 : 417-21.
5. Park W, Choi JW, Kim JY, Kim BC, Kim HJ, Lee SH. Cortical integrity of the inferior alveolar canal as a predictor of paresthesia after third-molar extraction. *J Am Dent Assoc* 2010; 141 : 271-8.
6. Suomalainen A, Ventä I, Mattila M, Turtola L, Vehmas T, Peltola JS. Reliability of CBCT and other radiographic methods in preoperative evaluation of lower third molars. *Oral Surg Oral Med Oral Pathol Oral Radiol Endod* 2010; 109 : 276-84.
7. Atieh MA. Diagnostic accuracy of panoramic radiography in determining relationship between inferior alveolar nerve and mandibular third molar. *J Oral Maxillofac Surg* 2010; 68 : 74-82.
8. Rood JP, Shehab BA. The radiological prediction of inferior alveolar nerve injury during third molar surgery. *Br J Oral Maxillofac Surg* 1990; 28 : 20-5.
9. Bundy MJ, Cavola CF, Dodson TB. Panoramic radiographic findings as predictors of mandibular nerve exposure following third molar extraction: digital versus conventional radiographic techniques. *Oral Surg Oral Med Oral Pathol Oral Radiol Endod* 2009; 107 : e36-40.
10. Gomes AC, Vasconcelos BC, Silva ED, Caldas Ade F Jr, Pita Neto IC. Sensitivity and specificity of pantomography to predict inferior alveolar nerve damage during extraction of impacted lower third molars. *J Oral Maxillofac Surg* 2008; 66 : 256-9.
11. Szalma J, Lempel E, Jeges S, Szabó G, Olasz L. The prognostic value of panoramic radiography of inferior alveolar nerve damage after mandibular third molar removal: retrospective study of 400 cases. *Oral Surg Oral Med Oral Pathol Oral Radiol Endod* 2010; 109 : 294-302.
12. Tantanapornkul W, Okochi K, Bhakdinaronk A, Ohbayashi N, Kurabayashi T. Correlation of darkening of impacted mandibular third molar root on digital panoramic images with cone beam computed tomography findings. *Dentomaxillofac Radiol* 2009; 38 : 11-6.
13. Palma-Carrió C, García-Mira B, Larrazabal-Morón C, Peñarocha-Diago M. Radiographic signs associated with inferior alveolar nerve damage following lower third molar extraction. *Med Oral Patol Oral Cir Bucal* 2010; 15 : e886-90.
14. Maegawa H, Sano K, Kitagawa Y, Ogasawara T, Miyauchi K, Sekine J, et al. Preoperative assessment of the relationship between the mandibular third molar and the mandibular canal by axial computed tomography with coronal and sagittal reconstruction. *Oral Surg Oral Med Oral Pathol Oral Radiol Endod* 2003; 96 : 639-46.
15. Nakamori K, Fujiwara K, Miyazaki A, Tomihara K, Tsuji M, Nakai M, et al. Clinical assessment of the relationship between the third molar and the inferior alveolar canal using panoramic images and computed tomography. *J Oral Maxillofac Surg* 2008; 66 : 2308-13.
16. Eyrich G, Seifert B, Matthews F, Matthiessen U, Heusser CK, Kruse AL, et al. 3-Dimensional imaging for lower third molars: is there an implication for surgical removal? *J Oral Maxillofac Surg* 2011; 69 : 1867-72.
17. Jhamb A, Dolas RS, Pandilwar PK, Mohanty S. Comparative efficacy of spiral computed tomography and orthopantomography in preoperative detection of relation of inferior alveolar neurovascular bundle to the impacted mandibular third molar. *J Oral Maxillofac Surg* 2009; 67 : 58-66.
18. Ghaemini H, Meijer GJ, Soehardi A, Borstlap WA, Mulder J, Vlijmen OJ, et al. The use of cone beam CT for the removal of wisdom teeth changes the surgical approach compared with panoramic radiography: a pilot study. *Int J Oral Maxillofac Surg* 2011; 40 : 834-9.
19. Tantanapornkul W, Okouchi K, Fujiwara Y, Yamashiro M, Maruoka Y, Ohbayashi N, et al. A comparative study of cone-beam computed tomography and conventional panoramic radiography in assessing the topographic relationship between the mandibular canal and impacted third molars. *Oral Surg Oral Med Oral Pathol Oral Radiol Endod* 2007; 103 : 253-9.
20. Nakagawa Y, Ishii H, Nomura Y, Watanabe NY, Hoshiba D, Kobayashi K, et al. Third molar position: reliability of panoramic radiography. *J Oral Maxillofac Surg* 2007; 65 : 1303-8.
21. Valmaseda-Castellón E, Berini-Aytés L, Gay-Escoda C. Inferior alveolar nerve damage after lower third molar surgical extraction: a prospective study of 1117 surgical extractions. *Oral Surg Oral Med Oral Pathol Oral Radiol Endod* 2001; 92 : 377-83.
22. Bell GW. Use of dental panoramic tomographs to predict the relation between mandibular third molar teeth and the inferior alveolar nerve. Radiological and surgical findings, and clinical outcome. *Br J Oral Maxillofac Surg* 2004; 42 : 21-7.
23. Monaco G, Montevecchi M, Bonetti GA, Gatto MR, Checchi L. Reliability of panoramic radiography in evaluating the topographic relationship between the mandibular canal and impact-

- ed third molars. *J Am Dent Assoc* 2004; 135 : 312-8.
24. Sedaghatfar M, August MA, Dodson TB. Panoramic radiographic findings as predictors of inferior alveolar nerve exposure following third molar extraction. *J Oral Maxillofac Surg* 2005; 63 : 3-7.
25. de Melo Albert DG, Gomes AC, do Egito Vasconcelos BC, de Oliveira e Silva ED, Holanda GZ. Comparison of orthopantomographs and conventional tomography images for assessing the relationship between impacted lower third molars and the mandibular canal. *J Oral Maxillofac Surg* 2006; 64 : 1030-7.
26. Öhman A, Kivijärvi K, Blombäck U, Flygare L. Pre-operative radiographic evaluation of lower third molars with computed tomography. *Dentomaxillofac Radiol* 2006; 35 : 30-5.
27. Yamaoka M, Furusawa K, Yamamoto M, Tanaka H, Horiguchi F, Nagano S. Radiographic study of bone loss of mandibular lingual cortical plate accompanied by third molar development. *Oral Surg Oral Med Oral Pathol Oral Radiol Endod* 1995; 80 : 650-4.
28. Akadiri OA, Obiechina AE. Assessment of difficulty in third molar surgery-a systematic review. *J Oral Maxillofac Surg* 2009; 67 : 771-4.