

A Study on Comparison of Cardiac Ejection Fraction Values Measured in Myocardium SPECT and Cine MRI

Jung-Seok Han¹, Kyung-Rae Dong^{2,3}, Yong-Soon Park², Woon-Kwan Chung^{3*},
Jae-Hwan Cho⁴, and Young-Kuk Cho^{5,6}

¹Department of Nuclear Medicine, Asan Medical Center, Seoul 138-736, Korea

²Department of Radiological Technology, Gwangju Health College University, Gwangju 506-701, Korea

³Department of Nuclear Engineering, Chosun University, Gwangju 501-759, Korea

⁴Department of International Radiological Science, Hallym University of Graduate Studies, Seoul 135-841, Korea

⁵Department of Clinical Laboratory Science, Seoyeong University, Gwangju 500-742, Korea

⁶Department of Biology, College of Bio-industry Science, Suncheon National University, Suncheon 540-950, Korea

(Received 7 July 2012, Received in final form 11 September 2012, Accepted 12 September 2012)

This study examined the correlation between MR cine and myocardium Single-photon emission computed tomography (SPECT) by comparing the measured cardiac ejection fractions. The usefulness of cardiac MRI was also evaluated. Ten patients (8 men, 2 women and average age of 58.6 years), who underwent a myocardium SPECT scan and cardiac cine MRI scan among patients who visited the hospital for the chief complaint of cardiac disorder from June 1, 2010 to February 10, 2011, were enrolled in this study. The cardiac ejection fraction was calculated from the images obtained in both scans. The data was used to examine the correlation. The regression equation the cardiac ejection fraction values of the 10 patients obtained in myocardium SPECT and MRI cine was $Y = 1.12X - 8.91$ ($R^2 = 0.78$, significance of $F = 0.001639$, and confidence level of 95%). The results were significant when the cardiac ejection fraction obtained from MRI cine was compared with that obtained from myocardium SPECT. Overall, a cardiac examination using MRI enables an investigation of not only the ejection fraction but also the ED and ES volumes, stroke volume, wall thickness, and wall thickening in a higher spatial resolution despite the examination being conducted once. This examination is believed to be very useful for diagnosing patients with cardiac disease.

Keywords : MR, cine, myocardium, SPECT, ED, ES

1. Introduction

Many methods can be used to examine the structure and function of the heart. The cardiac ejection fraction is used to investigate the dynamic function of the myocardium, particularly the left ventricular muscle [1]. This is because measurements of the cardiac ejection fraction are believed to be more reliable for evaluating the function of the left ventricular muscle than measurements of the cardiac output and left ventricular end-diastolic pressure. The cardiac ejection fraction of the left ventricle is quite helpful in making a decision as to whether an operation should be performed for patients with a range of cardiovascular diseases (heart valve disease or coronary artery disease) and to determine the prognosis of patients

with cardiac disorders. Methods to measure the cardiac ejection fraction include the use of cardiovascular ultrasound, angiocardiology, and radioactive isotope [2]. These methods have their own characteristics as well as strong and weak points. Currently, a radioactive isotope method is used as the golden standard to measure the cardiac ejection fraction [3, 4]. Radioisotope ventriculography to evaluate the heart function traditionally includes a gated cardiac blood pool scan and first-pass scan. Recently, gated myocardial perfusion SPECT has been used mainly because it enables a simultaneous evaluation of the perfusion and ventricular function [5].

Owing to the development of pulse sequence and software, a MR scan for the heart region has been used frequently as an alternative to the radioactive isotope method. Cardiac MRI does not require geometric premise, compared to cardiovascular ultrasound, without a restriction of the sonic window. The cardiac MRI provides high

*Corresponding author: Tel: +82-62-230-7166

Fax: +82-62-232-9218, e-mail: wkchung@chosun.ac.kr

resolution with high accuracy and reproducibility, which is useful for patients with cardiac disorder [6, 7]. In addition, cardiac MRI provides accurate information for an evaluation of the systolic function of the right ventricle and has been used widely to evaluate the volume and function of the right ventricle in a follow-up examination after surgery. Consequently, cardiac MRI is recognized as standard examination not only to obtain excellent anatomical image but also to evaluate the systolic cardiac function.

Against this backdrop, cardiac cine MRI was used to calculate the cardiac ejection fraction. The calculated value was then compared with the cardiac ejection fraction obtained using an isotope to determine the correlation between the two examination methods and evaluate the usefulness of cardiac cine MRI.

2. Experiment Materials and Method

2.1. Patients

This study enrolled 10 patients who underwent both myocardium SPECT and cardiac MRI within 6 hours among patients who visited the hospital for the chief complaint of cardiac disorders from June 1, 2010 to February 10, 2011. The 10 patients included 8 men and 2 women with a mean age of 62.1 years (range: 40-76 years).

2.2. Measurement Method

2.2.1. Measurement of Cardiac Ejection Fraction in Myocardium SPECT

An Elscint Varicam gamma camera (GE, US) was used in the examination method employing radioactive isotopes. Myocardium SPECT scan was conducted under rest and stress. For the scan in the rest stage, a fat meal was provided 20-30 minutes after an intravenous injection of 99mTc-sestamibi 8-10mCi. The scan was conducted 30-40 minutes later. The scan in the stress stage was conducted 3-4 hours after the scan in the rest stage. 99mTc-sestamibi was injected 4 minutes after an intravenous injection of adenosine. A fat meal was provided 20-30 minutes after the injection. The scan was conducted 20-30 minutes later. The mean myocardium thickness was 10 mm, whereas the thickness was approximately 16 mm at the end of the systolic period. In general, since the resolution of the SPECT camera is approximately 10 mm, a partial volume effect is conspicuous at a thickness of up to 20 mm. As the heart contracts, the myocardial wall becomes thick, which overcomes the partial volume effect. Consequently, the fraction rate increases, showing bright areas in the image. This is used to evaluate the contraction capability. Based on the evaluation, it is possible to mea-

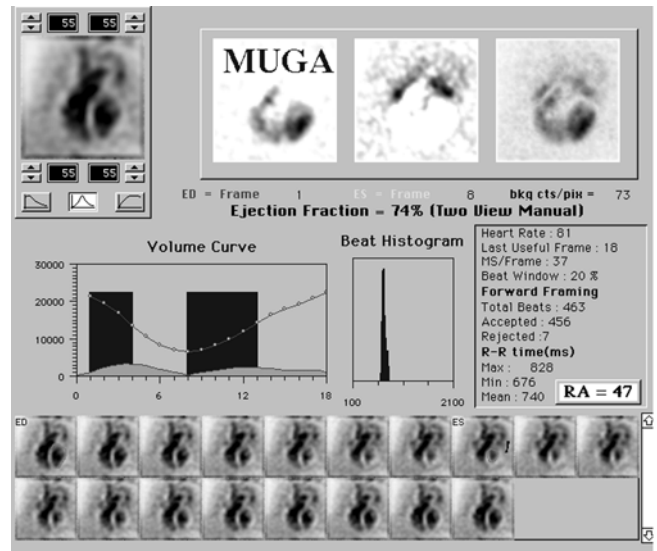


Fig. 1. EF Measurement in SPECT.

sure the volumes at the end of the diastolic period and at the end of systolic period, and calculate the cardiac ejection fraction (Fig. 1).

2.2.2. Measurement of Cardiac Ejection Fraction in MRI Cine (B-TFE)

1.5T superconducting MRI equipment (Gyrosan Intera, Phillips Medical system, Best, the Netherlands) was used along with a Synergy cardiac coil for a MRI scan. In addition, B-TFE (Balanced-turbo field echo) was used for the pulse sequence (flip angle = 50°, Repetition time (TR) = 3.1 ms and Echo time (TE) = 1.54 ms). The slice thickness was 10 mm with no spacing between the slices. In addition, the matrix size was 256 × 256. A four chamber view and long axis view were used as a localizer to obtain a cine image of a 10 slice short axis view with the entirety of the left ventricle included. The image was sent to a workstation (Easy Vision) before drawing the endo-cardium and epi-cardium in the MR cardiac analysis program. The following equation was used to calculate the left ventricular ejection fraction (EF) (Fig. 2).

$$EF = \frac{A - B}{A} \times 100 \quad (1)$$

(EF: left ventricular ejection fraction, A: volume of the left ventricle in the diastolic period, and B: volume of the left ventricle in the systolic period)

2.2.3. Data Analysis

SPSS 16.0 (SPSS win 16.0, Chicago, USA) was used to conduct a paired t-test to compare the cardiac ejection fractions obtained in the myocardium SPECT scan and

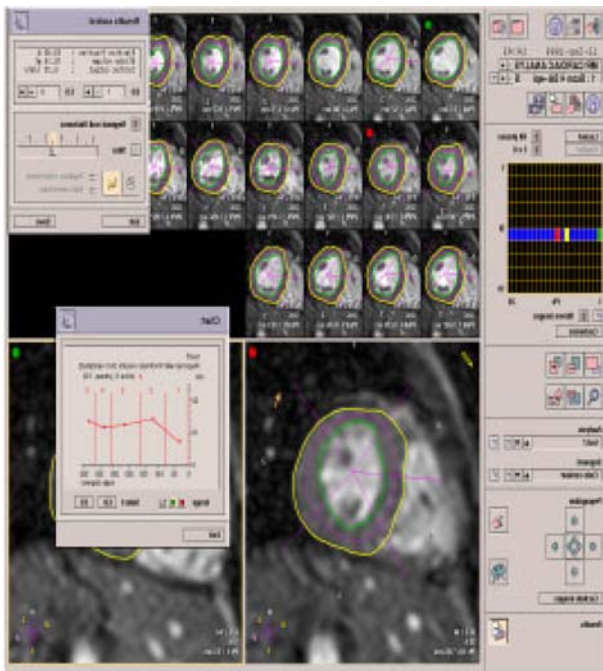


Fig. 2. (Color online) EF Measurement in MRI.

MR cine scan using an isotope. Regression analysis was performed to examine the correlation.

3. Results

Table 1 lists the cardiac ejection fractions obtained from the 10 patients who underwent both the myocardium SPECT and MRI cine scans. The mean cardiac ejection fractions in the myocardium SPECT scan was $37.4 \pm 11.8\%$, ranging from 19% to 55%. The mean cardiac ejection fractions in the MRI scan was $40.72 \pm 10.06\%$, ranging from 24% to 56.34%. The differences were not statistically significant ($p > 0.05$). Consequently, there is

Table 1. Difference in the EF Values in MRI and SPECT

Patient	EF in MRI	EF in SPECT	Difference in EF	P
1	36.3%	34%	2.3%	0.125
2	35.2%	30%	5.2%	
3	29.7%	19%	10.7%	
4	38.1%	37%	1.1%	
5	37.1%	26%	11.1%	
6	54.5%	52%	2.5%	
7	56.3%	45%	11.3%	
8	46.5%	46%	0.5%	
9	49.3%	58%	8.7%	
10	24%	27%	3%	

Average $37.4 \pm 11.8\%$ $40.72 \pm 10.06\%$

Note: The interaction effect was determined using a paried t test model.

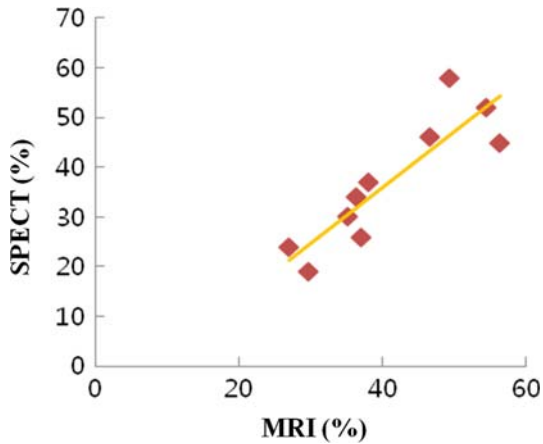


Fig. 3. (Color online) Graph of Regression Analysis of the EF Values in MRI and SPECT.

no difference between a myocardium SPECT scan and a MRI cine scan. The regression equation was $Y = 1.12X - 8.91$ ($R^2 = 0.78$, significance of $F = 0.001639$, and confidence level of 95%). Therefore, a myocardium SPECT scan has a relationship with a MRI cine scan (Fig. 3).

4. Discussion

Measurements of the left ventricular function are very important for patients with cardiovascular disorders. Methods to measure the function include angiocardigraphy, cardiovascular ultrasonography, radioisotope angiography and MRI [8-11].

According to the studies conducted thus far, cardiovascular ultrasonography, radioisotope angiography and angiocardigraphy showed similar accuracy. On the other hand, measurements of the cardiac ejection fraction based on M-mode cardiovascular ultrasonography were conducted assuming that the ventricle moves in the shape of an elliptical sphere with a 2:1 ratio of the major axis to the minor axis of the left ventricle. Therefore, if the movement of the ventricle is not in the shape of an elliptical sphere, it is likely that such a method will not ensure accurate measurements of the cardiac ejection fraction. On the other hand, two-dimensional ultrasonography has a weak point that it takes a longer time than M-mode ultrasonography [12, 13].

Schiller [14] and Folland [15] *et al.* reported a correlation among the cardiac ejection fractions of angiocardigraphy, radioisotope angiography and cardiovascular ultrasonography. In 1984, Longmore *et al.* [16] reported that the measurement by angiocardigraphy was higher than that in MRI. In 1986, Kaul *et al.* [17] reported that two-dimensional echocardiography had a strong correla-

tion with MRI. Buckwalter *et al.* [18] reported that angiocardiology measured using a right anterior oblique (RAO) view underestimated the ventricular volumes by 28% and 26% at the end of the diastolic and systolic period, respectively, compared to the results from MRI. Dilworth *et al.* [19] reported that MRI underestimated the left end-diastolic ventricular volume by 10%, compared to angiocardiology but the difference was not statistically significant.

Despite such a correlation, angiocardiology is the most accurate method for measuring the size of the left ventricle. On the other hand, the patient takes the burden of risk for angiocardiology, and it is expensive and difficult to take scan repeatedly.

Compared to radioisotope angiography, two-dimensional ultrasonography is free of exposure to ionizing radiation and can be conducted repeatedly several times. Nevertheless, a well trained operator is needed. Radioisotope angiography can lead to exposure to ionizing radiation but has the strong point that it ensures a precise measurement of the left ventricular function in a non-invasive manner [13]. On the other hand, due to the recent development of a MR pulse sequence and software, a cardiac examination that uses MRI enables an investigation of the ejection fraction and ED and ES volumes, stroke volume, wall thickness and wall thickening in a higher spatial resolution. Therefore, cine MRI is very useful for diagnosing patients with cardiac disease.

5. Conclusions

According to the study, the cardiac ejection fraction measured in the MRI scan was $40.72 \pm 10.06\%$, which was slightly higher than the $37.4 \pm 11.8\%$ measured by myocardium SPECT. On the other hand, the measurement values from the two methods showed a significance correlation (correlation coefficient of $R^2 = 0.78$, significance of $F = 0.001639$, and confidence level of 95%). The confidence level should increase further if the time delay in both methods is considered. In addition, a cardiac examination using MRI enables an investigation of not only the ejection fraction but also the ED and ES volumes, stroke volume, wall thickness and wall thickening with a higher spatial resolution, even though the examination is conducted once. MRI is very useful for evaluating the ventricular function before and after surgery in addition to obtaining anatomical information of patients who do not provide good quality images in cardiovascular ultrasono-

graphy or who have difficulties in undergoing angiocardiology.

References

- [1] F. Grothues, G. C. Smith, J. C. Moon, N. G. Bellenger, P. Collins, H. U. Klein, and D. J. Pennell, *Am. J. Cardiol.* **90**, 29 (2002).
- [2] J. R. Mark and T. F. Slaughter, *Cardiovascular Monitoring*, Churchill Livingstone, New York (2005).
- [3] C. S. Koh, *Korean J. Nucl. Med.* **20**, 1 (1986).
- [4] A. Ferro, M. Savatore, and A. Guocoio, *J. Nucl. Cardiol.* **8**, 669 (2001).
- [5] M. L. Bartlett, G. Srinivassan, W. C. Barker, A. N. Kit-siou, V. Dilsizian, and S. L. Bacharach, *J. Nucl. Med.* **37**, 1795 (1996).
- [6] M. M. Naik, G. A. Diamond, A. Soffer, and R. J. Siegel, *J. Am. Coll. Cardiol.* **25**, 937 (1995).
- [7] N. G. Bellenger, M. I. Burgess, S. G. Ray, A. Lahiri, A. J. Coats, J. G. Cleland, and D. J. Pennell, *Eur. Heart J.* **21**, 1387 (2000).
- [8] G. J. Dehmer, S. E. Lewis, L. D. Hillis, D. Twieg, M. Falkoff, R. W. Parkey, and J. T. Willerson, *Am. J. Cardiol.* **45**, 293 (1980).
- [9] R. Slutsky, J. Karliner, D. Ricci, R. Keiser, M. Pfisterer, D. Gorton, K. Peterson, and W. Ashburn, *Circulation* **60**, 556 (1979).
- [10] E. P. Gordon, I. Schnittger, P. J. Fitzgerald, P. Williams, and R. L. Popp, *J. Am. Coll. Cardiol.* **2**, 506 (1983).
- [11] U. Sechtem, P. W. Pflugfelder, R. G. Gould, M. M. Cassidy, and C. B. Hoggins, *Radiology* **163**, 697 (1987).
- [12] G. M. Pohost and R. C. Canby, *Circulation* **75**, 88 (1987).
- [13] D. J. Skorton and S. M. Collins, *Am. J. Cardiac Imaging* **2**, 3 (1988).
- [14] N. B. Schiller, H. Acquatella, T. A. Ports, D. Drew, J. Goerke, H. Ringertz, N. H. Silverman, B. Brundage, E. H. Botvinick, R. Boswell, and E. Carlsson, *Circulation* **60**, 547 (1979).
- [15] E. D. Folland, A. F. Parisi, P. F. Moynihan, D. R. Jones, C. L. Feldman, and D. E. Tow, *Circulation* **60**, 760 (1979).
- [16] D. B. Longmore, S. R. Underwood, G. N. Hounsfield, C. Bland, P. A. Poole-Wilson, D. Denison, R. H. Klipstein, D. N. Firmin, M. Watanabe, K. Fox, R. S. O. Rees, A. M. Mcneilly, and E. D. Burman, *Lancet* **325**, 1360 (1985).
- [17] S. Kaul, G. L. Wismer, T. J. Brady, D. L. Johnston, A. E. Weyman, R. D. Okada, and R. E. Dinsmore, *Am. J. Roentgenol.* **146**, 75 (1986).
- [18] K. A. Buckwalter, A. M. Aisen, L. R. Dilworth, G. B. Mancini, and A. J. Buda, *Am. J. Roentgenol.* **147**, 33 (1986).
- [19] L. R. Dilworth, A. M. Aisen, G. B. Mancini, and I. Lande, A. J. Buda, *Am. Heart J.* **113**, 24 (1987).