

RESEARCH COMMUNICATION

Relationship Between PTEN and Livin Expression and Malignancy of Renal Cell Carcinomas

Tao Cheng, Jian-Guo Zhang*, Yuan-He Cheng, Zhong-Wei Gao, Xiao-Qiang Ren

Abstract

Objectives: This study focused on PTEN and Livin expression and associations with malignancy in human renal clear cell carcinomas (RCCC). **Methods:** PTEN and Livin expression was assessed in 100 RCCC tissue samples, 50 paracarcinoma cases, and 20 normal renal tissue samples using the immunohistochemical Streptavidin peroxidase (SP) method. The relationships between binding and corresponding biological characteristics, such as histological grade, lymph node metastases, and clinical stages were analyzed. **Results:** Positive PTEN expression in RCCC was significantly lower than in renal tissue adjacent to carcinoma tissue and normal renal tissue ($P < 0.01$). Livin expression in the renal tissue adjacent to the carcinoma and normal renal tissues exhibited only low levels, whereas overall Livin expression in RCCC was statistically significant ($P < 0.01$). In RCCC, PTEN expression rate gradually decreased with an increase in clinical stage, whereas that of Livin increased to statistically significant levels ($P < 0.01$), PTEN and Livin levels being negatively correlated ($r = -0.395$, $P < 0.01$). **Conclusions:** PTEN and Livin are important in RCCC development. The two factors combined are expected to provide indices for estimating RCCC malignancy and progression levels, as well as references for RCCC diagnosis and treatment.

Keywords: Renal clear cell carcinoma (RCCC) - PTEN - livin - immunohistochemistry

Asian Pacific J Cancer Prev, 13, 2681-2685

Introduction

Renal cell carcinoma is the second most common urinary system cancer after bladder cancer. Kidney cancer has complex causes closely associated with multiple genes. Histological types of renal cell carcinoma include renal clear cell carcinoma (RCCC), renal granular cell carcinoma, and spindle cell carcinoma. RCCC has the highest incidence among all these histological types.

An increasing number of tumor suppressor genes have been found in recent in-depth tumor studies. Phosphatase and tensin homologue (PTEN), also known as TGF- β -regulated and epithelial cell-enriched phosphatase or mutated in multiple advanced cancers gene (Trotman et al., 2007), is a human tumor suppressor gene with the highest lost rate after P53 and the highest mutation rate (Huang and Kontos, 2002). The gene is located at 10q23 and contains nine exons encoding a 403-amino acid protein, mainly in the cytoplasm (Li and Sun, 1997). PTEN contains a PDZ (post synaptic density protein-q5, *Drosophila* disc large tumor suppressor, and zonula occludens-1) binding sequence, bird creatinine kinase-2 or -3 (melanoma antigen gene), and PDZ domain-binding and epithelial tight junctions, which regulate the AKT/PKB pathway. PTEN can downregulate the AKT/PKB pathway and inhibit cell proliferation and apoptotic function (Sun et al., 2011). At the same time, PTEN is a proven tumor suppressor gene phosphatase inhibitor

closely related to the mutation and development of several human malignancies, including breast cancer, glial brain cell tumors, bladder cancer, and prostate cancer (Hager, 2007).

The inhibitor of apoptosis protein family (IAPs) is an important human endogenous anti-apoptotic protein family. In 2000, Ashhab et al. (2001) reported IAP homologous sequences found in an IAP, which they named Livin. Livin contains a unique Baculovirus IAP repeat (BIR) domain and a Really Interesting New Gene (RING) finger motif domain. The gene also includes two subtypes, Livin- α and Livin- β . The Livin RING finger domain can promote its auto-ubiquitination, whereas the BIR domains may show decreased inhibitory activity. Livin BIR domain mutations greatly increase instability, thereby reducing apoptotic inhibition. Livin BIR domain mutations negatively regulate the second mitochondria-derived activator of caspases (SMAC)/direct IAP binding protein with low pI (DIABLO), as well as inhibit caspase-3 and caspase-7 enzymatic hydrolysis during in vitro direct interaction, caspase-9 function in vivo, and apoptosis. Livin exhibits E3 ubiquitin ligase activity to reduce the key apoptosis regulators in the SMAC/DIABLO, ubiquitin-proteasome pathway, thus inhibiting apoptosis (Kasof and Gomes, 2001). Livin expression in malignant tumors was first proposed in malignant melanoma (Vucic et al., 2000). Recently, Livin expression studies have been increasingly conducted on a variety of tumors,

Department of Urology, the 1st Affiliated Hospital of He'nan University of Science and Technology, Luoyang, China
*For correspondence: jianguozhangcn@163.com

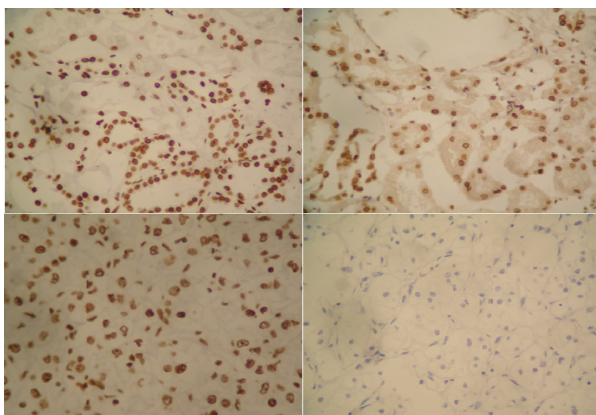


Figure 1. The Expression of PTEN (SP×400). A: Positive in normal renal tissues. B: Positive in in para carcinoma. C: Positive in clear cell renal carcinomas. D: negative in clear cell renal carcinomas

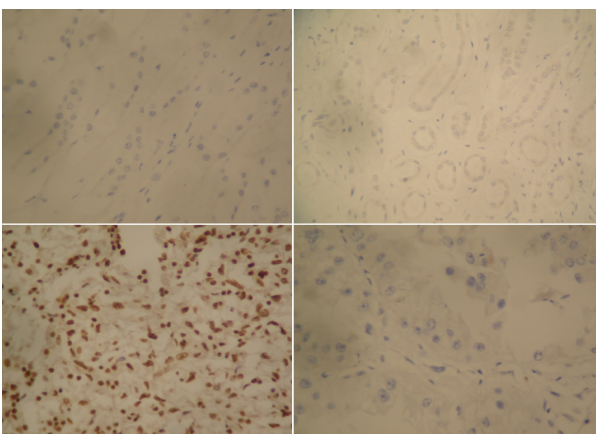


Figure 2. The Expression of Livin (SP×400). A: Negative in normal renal tissues. B: Negative in in para carcinoma. C: Positive in clear cell renal carcinomas. D: Negative in clear cell renal carcinomas

such as those in leukemia, bladder cancer, lung cancer, nasopharyngeal carcinoma, astrocytoma cancer, malignant pleural mesothelioma, pancreatic cancer, and kidney cancer.

Apoptosis and proliferation imbalance leading to tumorigenesis and progress is an important pathological basis in oncology (Feng et al., 2008; Gangar and Koul, 2008). PTEN and Livin are both involved in the apoptosis regulation. Although the two factors were investigated in relevant studies on various types of tumors, the current study was conducted to further clarify the relationship between the two factors and their roles in the occurrence and development of renal tumors. In this experiment, PTEN and Livin were detected using the immunohistochemistry SP method. The expression and mutual relations of the two factors in renal cell carcinoma were explored to provide a foundation for the diagnosis and prognosis of renal cell carcinomas.

Materials and Methods

Clinical Data

This study was conducted in accordance with the declaration of Helsinki. This study was conducted with approval from the Ethics Committee of Henan University of Science and Technology. Written informed consent

Table 1. The PTEN Expression in Clear Cell Renal Carcinomas, Para Carcinoma and Normal Renal Tissues

Tissue	n	Positive	Negative	χ^2	P
Cancer	100	40 (40.0%)	60 (60.0%)		
Para cancer	50	44 (88.0%)	6 (12.0%)	23.36	0
Normal	20	20 (100.0%)	0 (0.0%)		

Table 2. The Livin Expression in Clear Cell Renal Carcinomas, Para Carcinoma and Normal Renal Tissues

Tissue	n	Positive	Negative	χ^2	P
Cancer	100	44 (44.0%)	56 (56.0%)		
Para cancer	50	0 (0.0%)	50 (100.0%)	20.78	0
Normal	20	0 (0.0%)	20 (100.0%)		

was obtained from all participants. The subjects of this experiment (100 cases; 60 males and 40 females; aged 36 years to 74 years) were selected from the Department of Urology of the First Affiliated Hospital of Henan University of Science and Technology from 2010 to 2011. These renal cell carcinoma cases were confirmed using pathological methods. Eighteen cases were classified as Grade I, 48 cases as Grade II, and 34 cases as Grade III. Twenty cases were classified as Grade I, 56 cases as Grade II, and 24 cases as Grades III-IV using the clinical and pathological stages according to the Robson method. Lymph node metastasis was observed in 54 cases. Twenty cases of normal kidney tissue and 50 cases of cancer adjacent to kidney tissue were selected as control groups. No patients were candidates for preoperative radiotherapy or chemotherapy.

Determination of PTEN and Livin Expressions

Rabbit anti-human PTEN monoclonal antibody (concentrated), mouse anti-human Livin monoclonal antibody (concentrated), and the SP method were used in the immunohistochemistry kit (Fujian New Biotechnology Development Company, Fuzhou City, Fujian province, China). The paraffin-embedded specimens were sliced and analyzed using the immunohistochemical SP method and diaminobenzidine staining after dewaxing and hydration. Procedures in the experiment were performed with reference to the reagent instructions. The first working PTEN and Livin antibody concentration was 1:100. Tissue with known prostate cancer was used as positive control, whereas PBS instead of primary antibody was used as a negative control.

Positive PTEN and Livin expressions showed yellow or brown granules in the nucleus, respectively (Figure 1 and 2). The proportion of positive cells in each sample was calculated from five random high-power fields (400×). Determining positive cells from negative ones was performed according to the comprehensive judgment of the number of positive cells and staining intensity.

Statistical analysis

SPSS 17.0 statistical software was used for statistical analysis. The expression rate between the two samples was compared using the χ^2 test, whereas the correlation

Table 3. The PTEN, Livin Expression in Different Stage and Grade of Clear Cell Renal Carcinomas

Biological characteristics	n	PTEN		χ^2	P	Livin		χ^2	P
		Positive	Rate			Positive	Rate		
Histological classification									
I	18	14	77.80%	7.34	< 0.05	2	11.10%	9.24	< 0.01
II	48	18	37.50%			18	37.50%		
III	34	8	23.50%			24	70.60%		
Clinical stage									
I	20	14	70.00%	6.48	< 0.05	2	10.00%	9.39	< 0.01
II	56	20	35.70%			24	42.90%		
III-IV	24	4	16.70%			18	75.00%		
Lymphatic metastasis									
yes	54	30	55.60%	5.92	< 0.05	32	59.30%	5.55	< 0.05
no	46	10	21.70%			12	26.10%		

Table 4. The PTEN and Livin of Comparison Expression in Clear Cell Renal Carcinomas

PTEN	n	Livin		Rate	r	P
		Positive	Negative			
Positive	40	8	32	20.00%	-0.395	< 0.01
Negative	60	36	24	60.00%		
Total	100	44	56	44.00%		

between the two variables was determined using the Spearman rank correlation analysis. $P < 0.05$ indicated statistical significance.

Results

PTEN Expression

PTEN expression in 100 cases of renal cell carcinoma specimens were significantly lower than that in the cancerous tissue adjacent to normal renal and kidney tissues ($\chi^2=23.36$, $P<0.01$; Table 1).

Livin Expression

Livin expression in renal cell carcinoma was 44.0%, whereas it was absent in the adjacent tissues and normal kidney tissue. The positive expression rates in cancer tissues, cancerous tissue next to renal tissues, and normal tissue varied significantly ($\chi^2=20.78$, $P<0.01$; Table 2).

Relationship of PTEN and Livin positive expression and biological characteristics

Based on the histopathological grading system used, the differences among the PTEN positive expression rates in classes I (77.8%), II (37.5%), and III (23.5%) were statistically significant ($P<0.05$). Under the clinical stage classification, PTEN positive expression rate was 70.0% in stages I, 35.7% in II, and 16.7% in III-IV; the difference was statistically significant ($P<0.05$). Positive lymph node metastasis expression rate was 55.6%, whereas overall expression in lymph node metastasis was 21.7%; the difference was statistically significant ($P<0.05$). Positive Livin expression rate in class III tissues was 70.6%, which was much higher than in class I with 11.1% ($P<0.01$). The mid-term positive expression rate in clinical stages III-IV was 75.0%, which was much higher than in stages I and II with 10.0% and 42.9%, respectively ($P<0.01$). Livin expression in the lymph node metastasis-positive group

was 59.3%, which was higher than in the lymph node metastasis-negative group with 26.1% ($P<0.05$; Table 3).

Relationship between PTEN and Livin in renal cell carcinoma

Only 8 in 40 cases of PTEN-positive RCCC specimens were positively expressed Livin. However, 36 in the 60 cases of PTEN-negative specimens were Livin-positive. PTEN and Livin expressions were significantly negatively correlated ($r=-0.395$, $P<0.01$; Table 4).

Discussion

Brenner et al. (2002) showed that PTEN expression was strongly positive in normal proximal tubular kidney tissue, whereas the distal renal tubular epithelial cells showed no or only very weak expression. Proximal tubular epithelial cells are the most common kidney cancer precursor cells. PTEN in the cell membrane anchor was found in the proximal tubule. The loss of this membrane localization may result in the loss of PTEN function. In the present study, PTEN was highly expressed in normal renal tissue, but were significantly reduced in RCCCs (Table 1). Thus, the PTEN gene in normal renal tissue may function in tumor suppression. However, Rasheed et al. (1997) concluded that no correlation exists between PTEN expression and histological grade. PTEN expression in G1-phase renal cell carcinomas was significantly reduced compared with that in renal precursor cells (renal proximal tubule cells). However, this phenomenon was not observed from G2 to G3. PTEN expression decreased as mitosis proceeded, indicating that the loss of PTEN inhibition is an early indication of renal cell carcinoma. However, a correlation was found between PTEN expression and the histological grading of renal cell carcinoma in the current study. PTEN positive expression rate decreased with a higher cancer histological grade (Table 3). Therefore, considering the absence of the PTEN suppressor gene as an early indicator of renal cell carcinoma needs further study.

Apoptosis is a genetically controlled cell self-destruction process. Disorders in apoptosis regulatory mechanisms have been closely associated with tumorigenesis. At the same time, cell apoptosis occurs through multiple pathways and is regulated by a variety of factors. Livin directly or indirectly blocks the exogenous and endogenous pathways of apoptosis receptors and

mitochondrial. Livin can function in combination with a variety of apoptosis-stimulating factors to inhibit apoptosis (Ka and Hunt, 2003). Recent domestic and international studies revealed that Livin is mainly expressed in malignant and fetal tissues, with decreased or absent expression in the majority of adults in the terminal organization (Nachmias et al., 2007). However, few reports discussing Livin as a specific IAP are currently available. Xu et al. (2010) studied renal cell carcinoma using immunohistochemical methods and positively detected Livin expression in 22/54 cases (40.7%). In the present study, positive Livin expression rate was detected in 44% of 100 cases of renal cell carcinoma. However, no expression was detected in the adjacent tissues and normal kidney tissue; the difference was statistically significant ($P < 0.01$; Table 2). This result is similar with the findings of Xu et al. Livin expression is renal cell carcinoma-specific, considering expressionist absence in adjacent tissues and normal kidney tissue. Thus, Livin expression in renal cell carcinoma may have a certain relationship with renal cell carcinoma occurrence and development. Reports on the relationship between Livin and clinicopathological factors in a variety of tumors are mixed. A higher positive expression rate of Livin in installments high tumor has been reported (Tanabe et al., 2004). Some reports showed that positive Livin expression rate tended to increase in more advanced clinical and pathological stages. However, statistical analysis revealed no significant difference (Zhao et al., 2009). In the current study, Livin was exhibited significantly high positive expression rate in lymph node metastasis, with poor histological differentiation. Furthermore, a significant correlation between Livin expression in renal cell carcinoma and its degree of differentiation was found (Table 3). Livin functions as apoptosis inhibitor in renal cell carcinoma, thus, cancer cells show transition proliferation. Livin may also determine the invasiveness and malignancy of RCCCs. However, a study with bigger sample size is needed to confirm this conclusion further.

Based on the comparative study of the two factors, PTEN and Livin are significantly negatively correlated ($r = -0.395$, $P < 0.01$; Table 4). PTEN and Livin expressions among classes I and II and III and IV RCCCs varied significantly, as well as between the lymph node metastasis groups (Table 3). The results were consistent with Ni's study on renal cell carcinoma (Ni et al., 2011), Li's study on colorectal cancer (Li, 2009), Zhang's study on esophageal squamous cell carcinoma (Zhang et al., 2010), and Yin et al.'s study (Sui and Miao, 2009) on tongue squamous cell carcinoma. These studies also considered the two factors investigated in the present study.

Apoptosis inhibitory genes and pro-apoptotic genetic expression in RCCCs express a mutual inhibition of the mutual adjustment product, which is composed of a complex tumor suppressor and linkage promoter. A simple way of screening tumor-related factors was found in this experiment using the immunohistochemical retrospective methods. Livin was highly expressed in various stages of renal cell carcinoma tissue. The protein functions specifically to promote cancer cell growth and proliferation, and inhibits apoptosis directly or indirectly.

PTEN is important in the maintenance of normal cell growth and in oncogenic inhibition. Disorders in the expressions of these two factors may be important in the development of renal cell carcinoma. In addition to their individual functions, the two factors may function in synergy. However, this synergistic mechanism needs further research at the molecular level. Moreover, early detection of these two factors may contribute to the early diagnosis and prognosis of clinical RCCCs.

References

- Ashhab Y, Alian A, Polliack A, Panet A, Ben Yehuda D (2001). Two splicing variants of a new inhibitor of apoptosis gene with different biological properties and tissue distribution pattern. *FEBS Lett*, **495**, 56-60.
- Brenner W, Färber G, Herget T, et al (2002). Loss of tumor suppressor protein PTEN during renal carcinogenesis. *Int J Cancer*, **99**, 53-7.
- Feng Y, Tian ZM, Wan MX, Zheng ZB (2008). Low intensity ultrasound-induced apoptosis in human gastric carcinoma cells. *World J Gastroenterol*, **14**, 4873-9.
- Gangar SC, Koul A (2008). Histochemical, ultrastructural, and biochemical evidences for Azadirachta indica-induced apoptosis in benzo(a)pyrene-induced murine forestomach tumors. *J Environ Pathol Toxicol Oncol*, **27**, 219-32.
- Hager M (2007). PTEN expression in renal cell carcinoma and prognosis. *Pathology*, **39**, 482-5.
- Huang J, Kontos CD (2002). Modulates vascular endothelial growth factor-mediated signaling and angiogenic effects. *J Biol Chem*, **277**, 10760-6.
- Ka H, Hunt JS (2003). Temporal and spatial patterns of expression of inhibitors of apoptosis in human placentas. *Am J Pathol*, **163**, 413-22.
- Kasof GM, Gomes BC (2001). Livin, a novel inhibitor of apoptosis protein Family member. *J Biol Chem*, **276**, 3238-46.
- Li DM, Sun H (1997). TEP1, encoded by a candidate tumor suppressor locus, is a novel protein tyrosin phosphates regulated by transforming growth factor β . *Cancer Res*, **57**, 2124-9.
- Li RH (2009). Livin and PTEN in colorectal cancer tissues and its significance. *Chin J integrated traditional and Western Med*, **16**, 247-8.
- Nachmias B, Mizrahi S, Elmalech M, et al (2007). Manipulation of NK cytotoxicity by the IAP family member Livin. *Eur J Immunol*, **37**, 3467-6.
- Ni JH, Xin J, Wu BC, Xin MH, Wu WF (2011). Livin and PTEN in renal cell carcinoma and its clinical significance. *Practical J Cancer*, **26**, 42-4.
- Rasheed BK, Stenzel TT, Melendon RE, et al (1997). PTEN gene mutations are seen in high-grade but not in low-grade gliomas. *Cancer Res*, **57**, 4187-90.
- Sui CD, Miao B (2009). PTEN and Livin in tongue squamous cell carcinoma and its clinical significance. *Heilongjiang Pharmaceutical Science*, **32**, 26-7.
- Sun CH, Chang YH, Pan CC (2011). Activation of the p13k/Akt/mTOR pathway correlates with tumour progression and reduced survival in patients with urothelial carcinoma of the urinary bladder. *Histopathology*, **58**, 1054-63.
- Tanabe H, Yagihashi A, Tsuji N, Shijubo Y, Abe S, Watanabe N (2004). Expression of survivin mRNA and Livin mRNA in non-small-cell lung cancer. *Lung Cancer*, **46**, 299-304.
- Trotman LC, Wang X, Alimonti A, et al (2007). Ubiquitination regulates PTEN nuclear import and tumor suppression. *Cell*, **128**, 141-56.

- Vucic D, Stennicke HR, Pisabarro MT, Salvesen GS, Dixit VM (2000). LIVIN, a novel inhibitor of apoptosis that is preferentially expressed in human melanomas. *Curr Biol*, **10**, 1359-66.
- Xu ST, Yan CY, Huang YH, Ding X (2010). Research on expression of livin in human renal cell carcinoma. *Med J West China*, **22**, 217-9.
- Zhang Q, Gao Y, Wang XL, et al (2010). In esophageal squamous cell carcinoma tissue PTEN, Livin changes in protein expression and significance. *Shandong Med J*, **50**, 52-3.
- Zhao Y, Deng X, Wang Q (2009). Livin, Smac/DIABLO in stomach tissue PTEN and expression and the correlation and gastric cancer. *World Chinese J Digestol*, **17**, 1303-11.