

RESEARCH COMMUNICATION

Expression of Matrix Metalloproteinase-2, but not Caspase-3, Facilitates Distinction between Benign and Malignant Thyroid Follicular Neoplasms

Sanaz Sanii, Hiva Saffar, Hedieh M Tabriz, Mostafa Qorbani, Vahid Haghpanah, Seyed M Tavangar*

Abstract

Purpose: Definite diagnosis of follicular thyroid carcinoma (FTC) is based on the presence of capsular or vascular invasion. To date, no reliable and practical method has been introduced to discriminate this malignant neoplasm from follicular thyroid adenoma (FTA) in fine needle aspiration biopsy material. Matrix metalloproteinase-2 (MMP-2), by degrading extracellular matrix, and caspase-3, by induction of apoptosis, have been shown to play important roles in carcinogenesis and aggressive behavior in many tumor types. The aim of this study was to examine expression of MMP-2 and caspase-3 in thyroid follicular neoplasms and to determine their usefulness for differential diagnosis. **Method:** Sixty FTAs and 41 FTCs were analysed immunohistochemically for MMP-2 and caspase-3. **Result:** MMP-2 was positive in 4 FTCs (9.8%), but in none of FTAs, with statistical significance ($p=0.025$). Caspase-3 was positive in 30 (50%) of FTAs and in 27 (65.9%) of FTCs. **Conclusion:** Our results show MMP-2 expression only in FTCs and suggest that this protein may be a useful marker to confirm diagnosis of FTC versus FTA with 100% specificity and 100% predictive value of a positive test. We failed to show any differential diagnostic value for caspase-3 in thyroid follicular neoplasms.

Keywords: Caspase-3 - follicular thyroid adenoma - follicular thyroid carcinoma - immunohistochemistry

Asian Pacific J Cancer Prev, 13, 2175-2178

Introduction

Thyroid tumors with a follicular growth pattern include a broad range of lesions from benign hyperplastic nodules to malignant neoplasms (Carling & Udelsman, 2005). Follicular thyroid adenoma (FTA), a benign encapsulated tumor with evidence of follicular cell differentiation, is the most common thyroid neoplasm (Rosai, 2011). True follicular thyroid carcinoma (FTC) (not including follicular variant of papillary carcinoma) is the malignant thyroid tumor exhibiting evidence of follicular cell differentiation (Rosai, 2011). One of the most challenging tasks in pathologic evaluation of thyroid lesions, is the differentiation between FTC and FTA. Diagnosis of FTC is dependent on the presence of capsular or vascular invasion (Rosai, 2011; Bryson et al., 2008). Fine needle aspiration biopsy is not capable to discriminate between FTA and FTC based on the mentioned criteria (Goldstein et al., 2002).

Methods for distinguishing between FTA and FTC would obviate many unnecessary thyroid surgeries. However, to date no definitely reliable and feasible discriminatory marker has been introduced.

Matrix metalloproteinase-2 (MMP-2) is a zinc-

dependent endopeptidase able to degrade type IV collagen in extracellular matrix that affect early events in carcinogenesis and tumor invasion and/or metastasis (Tryggvason et al., 1993; Dubravka et al., 2000; Nelson et al., 2000; Nabeshima et al., 2002; Chomar et al., 2006). Over expression of MMP-2 has been documented in many tumors types (Nakamura et al., 1999; Dubravka et al., 2000).

Caspase-3 is a cystein-dependent aspartate-directed protease which is important mediator of apoptosis (Philchenkov et al., 2004; Vermeulen et al., 2005). An important feature in carcinogenesis is represented by aberrations in control of apoptosis (Weidinger et al., 2010).

In this study, expression of MMP-2 and caspase-3 was examined by immunohistochemistry (IHC) in sections of FTAs and FTCs. The aim was to examine expression of MMP-2 and Caspase-3 in thyroid follicular neoplasms and to determine their usefulness for differential diagnosis between adenoma and carcinoma.

Materials and Methods

Paraffin blocks of formalin-fixed samples representing 60 cases of FTA and 41 cases of FTC diagnosed during

the years 1988 - 2010 in the Department of Pathology, Shariati Hospital, Tehran, Iran, were examined to determine the expression of MMP-2 and Caspase-3. Cases of FTC were diagnosed based on capsular and/ or vascular invasion. The study was conducted according to the protocol of the Ethics Committee of Endocrinology & Metabolism Research Center.

The paraffin blocks containing minimal necrosis and hemorrhage, and representative amount of the tumor tissue were selected for IHC study using Novocastra™ Lyophilized Mouse Monoclonal Antibodies Matrix Metalloproteinase-2 (product code NCL-MMP2-507, Clone 17B11) and Caspase-3 (CPP32) (product code NCL-CPP32, clone JHM62).

Two 3-micrometer sections from representative blocks of every tumor were deparaffinized, rehydrated, placed in 0.5% hydrogen peroxide for 10 minutes. Antigen retrieval and unmasking was performed according to manufacturer’s instruction. Sections were separately incubated with primary antibodies, washed with TBS buffer, and then incubated with the appropriate biotinylated secondary antibody. Washing in TBS buffer, incubation in ABC reagent, washing in TBS buffer and incubation in suitable peroxidase substrate were then consecutively performed. Finally the slides were counterstained with hematoxyline, dehydrated and mounted. Expected staining pattern was cytoplasmic for both markers. For negative controls, the primary antibodies were substituted with normal serum at appropriate concentration. Tonsil and inflamed large bowel were used as positive controls for caspase-3 and MMP-2, respectively, as recommended by the manufacturer.

Immunoreactivity of tumor cells for each of the two markers were semi-quantitatively scored as to extent (Table 1).

After collection of data, the analysis of qualitative and

quantitative data was done using Statistical Package for Social Sciences (SPSS) version 15.0 (Chicago, Illinois, USA). P value < 0.05 was considered significant.

Results

Results of IHC study of FTAs and FTCs are summarized in Figure 1.

Thirty (50%) out of 60 FTAs and 14 (34.1%) out of 41 FTCs showed negative caspase-3 expression. Caspase-3 was expressed mildly in 9 FTAs (15%) and 10 FTCs (24.4%), moderately in 6 FTAs (10%) and 10 FTCs (24.4%) and markedly in 15 (25.5%) FTAs and 7 (17.1%) FTCs. No relationship was observed between caspase-3 expression and benign tumor behavior (p=0.092).

No FTA expressed MMP-2. Among FTCs, 32 (90.3%) cases were negative and 4 (9.7%) cases were mildly positive for MMP2 expression.

Statistically significant relationship was observed between MMP-2 expression and malignant tumor behavior (i.e. diagnosis of FTC) (p=0.025).

Discussion

Differential diagnosis between FTA and FTC is based on presence of capsular or vascular invasion in carcinoma (Rosai, 2011; Bryson et al., 2008) which cannot be evaluated in material obtained from thyroid fine needle aspiration biopsy (Goldstein et al., 2002). Suspicious nodules must therefore be surgically removed in subtotal or total thyroidectomy. With the diagnosis of follicular carcinoma confirmed in formal pathologic evaluation, a second operation may be necessary (Stolf et al., 2006).

Regarding the fact that 5-10% of the population will develop a clinically significant thyroid nodule during their lifetime (Mazzaferri, 1993; Barden et al., 2003) and that by fine needle aspiration biopsy approximately 20% of thyroid nodules are follicular neoplasms (Carling & Udelsman, 2005), methods for distinguishing between adenoma and carcinoma would obviate many unnecessary thyroid surgeries.

Furthermore, such methods would be of great value in cases of minimally invasive (or encapsulated) follicular carcinoma, where discrimination from adenoma based on vascular or capsular invasion suffers inter-observer variation among pathologists (Hirokava et al., 2002; France et al., 2003) and also, in pathology specimens in which capsular detachment, tissue fragmentation or distortion, or subtleness of vascular or capsular invasion makes the distinction between carcinoma and adenoma difficult.

It is suggested that in molecular analysis, follicular thyroid adenoma and carcinoma have different characteristic microarray expression profiles (Barden et al., 2003; Cerutti et al., 2004, Finley et al., 2004; Griffith et al., 2006). However, DNA microarray gene profiling is expensive, time consuming, and operator dependent and therefore not practical for clinical use (Bryson et al., 2008).

To overcome the difficulty in distinguishing between FTA and FTC by IHC study as a less costly and more available method, various markers have been evaluated.

Table 1. Interpretation of IHC Results

Interpretation	Extent of immunoreactivity (percentage of tumor cells with positive staining)
Negative	<10%
Positive: mildly	10-39%
moderately	40-69%
markedly	>70%

*Colon, unspecified' excluded from correlation analysis; UICC, Union for International Cancer Control

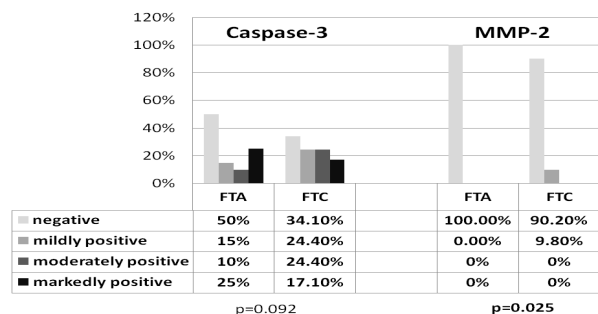


Figure 1. Expression of Caspase-3 and Matrix Metalloproteinase-2 (MMP-2) in Follicular Thyroid Adenoma (FTA) and Follicular Thyroid Carcinoma (FTC)

Despite some overlapping results, Dipeptidyl aminopeptidase IV (CD26) was reported to be useful for distinction between FTA and FTC, primarily in cytological specimens (Kotani et al., 1992; Maruta et al., 2004). Survivin (Hagh et al., 2006), HBME-1, CD15, thyroid peroxidase, CD10 (a zinc-dependent metalloproteinase, that may share certain functions with some MMPs) and cell proliferation markers have also been reported to be useful (Cho et al., 2006). In a previous experience, we failed to show any discriminating role for nm-23 in this regard (Moradi et al., 2009).

In a study by Chen et al, EMMRPIN has been implicated in the metastatic potential of FTCs (Chen et al., 2001), Barden et al. (Barden et al., 2003) confirmed the differential expression of EMMRPIN by means of immunoblot analysis; however, no evaluation of its diagnostic potential was analyzed. A multicenter study demonstrated that IHC detection of galectin-3 (an enzyme regulating cell-cell communication and implicated in the initiation and regulation of cell growth and malignant transformation) in FNA biopsy samples from thyroid nodules served as a highly specific and sensitive means of identifying malignant lesions of the thyroid (Bartolazzi et al., 2001). Other studies disprove the utility of galectin-3 as a single protein marker, especially in the case of follicular lesions (Bryson et al., 2008).

Prasad et al. reported that a panel consisting of galectin-3, fibronectin-1 and HBME-1 may enhance the sensitivity and specificity for diagnosis of FTC versus FTA (Prasad ML, et al 2005). Some studies have suggested trefoil factor 3 (TFF3) as a useful biomarker at the RNA level in thyroid cancer, and this gene was listed as 1 of 12 (of a total of 1795 genes) to have the most clinical promise (based on results of the array analysis) for the preoperative thyroid diagnosis (Griffith et al., 2006). IHC results of another study did not substantiate the anticipated promise of TFF3 as a clinical marker (Bryson et al., 2008).

Despite all the studies, of which only some were mentioned, no definitely reliable and feasible discriminatory marker has been introduced to date.

Matrix metalloproteinases (MMPs), including MMP-2, are a group of zinc-dependent endopeptidases with extracellular matrix-degrading properties that affect early events in carcinogenesis and tumor invasion and/or metastasis (Nelson et al., 2000; Nabeshima et al., 2002; Cho et al., 2006).

Over expression of MMP-2 in tumor tissue compared to adjacent normal tissue has been documented in many types of solid tumors, including breast, colorectal and pancreatic carcinomas, as well as squamous carcinomas of the head and neck. Human thyroid carcinoma tissues have been also reported to express MMP-2 (Nakamura et al., 1999; Dubravka et al., 2000). Others proposed MMPs, could not be shown to definitely distinguish between widely invasive and minimally invasive follicular thyroid carcinomas or between the latter and adenomas (Cho et al., 2006).

However, in a study by Liang et al. 113 patient samples were analyzed for expression of several biomarkers including MMP2, which was determined as independent factor associated with the metastatic status in thyroid

Table 2. Sensitivity (9.7%), Specificity (100%), Predictive Value of a Positive Test (PPV=100%) and Predictive Value of a Negative Test (NPV=61.8%) of MMP-2 for Discrimination Between FTA and FTC

Test	DX		Total
	FTC	FTA	
+	4	0	4
-	37	60	97
Sum	41	60	101

cancers. Finally, MMP2 was considered as a potential tumor marker to identify greater risk of metastasis (Liang et al., 2011). Moreover, MMPs are known to promote tumor metastasis and are determined as targets of 3,3'-diindolylmethane(DIM), which is believed to have anti-estrogen like property and can be considered as a potential novel preventive/therapeutic dietary supplement in thyroid cancers (Rajoria et al., 2011).

Caspases, including caspase-3, are cysteine-dependent aspartate-directed proteases and important mediators of apoptosis. Many studies confirm contribution of deregulated apoptotic pathways in cancer development and progression; particularly, an important feature in thyroid carcinogenesis is represented by aberrations in control of apoptosis (Veidinger et al., 2010). Inactivation of proapoptotic and/ or activation of antiapoptotic components, including decreased expression of caspase-3 and other caspases has been documented in many cancers shown to correlate with response to treatment and prognosis in some cancers, including those of breast, lung colon, uterine cervix and thyroid. (Kotani et al., 1992; Devarajan et al., 2002; Philchenkov et al., 2004; Fennel et al., 2005; Furuya, 2007; Moradi et al., 2009;) .

It could be inferred from the mentioned facts that expression of MMP-2 and caspase-3, could potentially be related to -respectively- aggressive and indolent tumor behavior. In this study, expression of MMP-2 and caspase-3 was examined by IHC in samples of FTA and FTC in order to determine their usefulness for preoperative differential diagnosis between FTA and FTC.

We have observed a statistically significant relationship between positive expression of MMP-2 and malignant behavior of thyroid follicular neoplasm. This means that positive expression of MMP-2 in a follicular thyroid neoplasm could be equal to the diagnosis of FTC (versus FTA) with 9.7% sensitivity, 100% specificity, 100% Predictive value of a positive test (PPV) and 61.8% predictive value of a negative test (NPV) (Table 2).

We failed to show any relationship between expression of caspase-3 and the probability of a thyroid follicular neoplasm, being diagnosed as FTA or FTC.

In this study, MMP-2 was differentially expressed by FTAs and FTCs. Alas, because of low sensitivity of positive expression of MMP-2, this is not a suitable test for screening follicular thyroid neoplasms for diagnosis of FTC. However, in cases with equivocal criteria of malignancy (vascular or capsular invasion) or in a panel with potential sensitive marker, positive IHC result for MMP-2 could be of great value to confirm the diagnosis of FTC with 100% specificity and 100% PPV.

References

- Barden CB, Shister KW, Zhu B, et al (2003). Classification of follicular thyroid tumors by molecular signature: results of gene profiling. *Clin Cancer Res*, **9**, 1792-800.
- Bartolazzi A, Gasbarri A, Papotti M, et al (2001). Application of an immunodiagnostic method for improving preoperative diagnosis of nodular thyroid lesions. *Lancet*, **357**, 1644-50.
- Bryson PC, Shores CG, Hart C, et al (2008). Immunohistochemical Distinction of Follicular Thyroid Adenomas and Follicular Carcinomas. *Arch Otolaryngol Head Neck Surg*, **134**, 581-6.
- Carling T, Udelsman R, (2005). Follicular Neoplasms of the Thyroid: What to Recommend. *THYROID*, **15**, 583-7.
- Cerutti JM, Delcelo R, Amadei MJ, et al (2004). A preoperative diagnostic test that distinguishes benign from malignant thyroid carcinoma based on gene expression. *J Clin Invest*, **113**, 1234-42.
- Chen K-T, Lin J-D, Chao T-C, et al (2001). Identifying differentially expressed genes associated with metastasis of follicular thyroid cancer by cDNA expression array. *Thyroid*, **11**, 41-6.
- Cho Mar K, Eimoto T, Tateyama H, et al (2006). Expression of matrix metalloproteinases in benign and malignant follicular thyroid lesions. *Histopathology*, **48**, 286-94.
- Devarajan E, Sahin AA, Chen JS, et al (2002). Down-regulation of caspase 3 in breast cancer: a possible mechanism for chemoresistance. *Oncogene*, **21**, 8843-51.
- Dubravka C, Svetlana S, Ivan P, et al (2000). Immunohistochemical localization of matrix metalloproteinase-2 (MMP-2) in medullary thyroid carcinoma. *Arch Oncol*, **8**, 95-7.
- Fennell DA (2005). Caspase regulation in non-small cell lung cancer and its potential for therapeutic exploitation. *Clin Cancer Res*, **11**, 2097-105.
- Finley DJ, Zhu B, Barden CB, et al (2004). Discrimination of benign and malignant thyroid nodules by molecular profiling. *Ann Surg*, **240**, 425-37.
- France B, De La Salmonie P, Lange F, et al (2003). Inter observer and intra observer reproducibility in the histopathology of follicular thyroid carcinoma. *Hum Pathol*, **34**, 1092-9.
- Furuya F, Lu C, Willingham MC, et al (2007). Inhibition of phosphatidylinositol 3-kinase delays tumor progression and blocks metastatic spread in a mouse model of thyroid cancer. *Carcinogenesis*, **28**, 2451-8.
- Goldstein RE, Nettekville JL, Burkey B, et al (2002). Implications of follicular neoplasms, atypia, and lesions suspicious for malignancy diagnosed by fine-needle aspiration of thyroid nodules. *Ann Surg*, **235**, 656-62.
- Griffith OL, Melck A, Jones SJ, et al (2006). Meta-analysis and meta-review of thyroid cancer gene expression profiling studies identifies important diagnostic biomarkers. *J Clin Oncol*, **24**, 5043-50.
- Haghpanah V, Shooshtarizadeh P, Heshmat R, et al (2006). Immunohistochemical analysis of survivin expression in thyroid follicular adenoma and carcinoma. *Appl Immunohistochem Mol Morphol*, **14**, 422-5.
- Hirokawa M, Carney JA, Goellner JR, et al (2002). Observer variation of encapsulated follicular lesions of the thyroid gland. *Am J Surg Pathol*, **26**, 1508-14.
- Kotani T, Asada Y, Aratake Y, et al (1992). Diagnostic usefulness of dipeptidyl aminopeptidase IV monoclonal antibody in paraffin-embedded thyroid follicular tumors. *J Pathol*, **168**, 41-5.
- Liang H, Zhong Y, Luo Z, et al (2011). Diagnostic value of 16 cellular tumor markers for metastatic thyroid cancer: an immunohistochemical study. *Anticancer Res*, **31**, 3433-40.
- Maruta J, Hashimoto H, Yamashita H, et al (2004). Diagnostic applicability of dipeptidyl aminopeptidase IV activity in cytological samples for differentiating follicular thyroid carcinoma from follicular adenoma. *Arch Surg*, **139**, 83-8.
- Mazzaferrri EL (1993). Management of a solitary thyroid nodule. *N Engl J Med*, **328**, 553-9.
- Moradi Tabriz H, Adabi Kh, Lashkari A, et al (2009). Immunohistochemical analysis of nm23 protein expression in thyroid papillary carcinoma and follicular neoplasm. *Pathol Res Pract*, **205**, 83-7.
- Nabeshima K, Inoue T, Shimao Y, et al (2002). Matrix metalloproteinases in tumor invasion: role for cell migration. *Pathol Int*, **52**, 255-64.
- Nakamura H, Ueno H, Yamashita K, et al (1999). Enhanced production and activation of progelatinase A mediated by membrane type I matrix metalloproteinase in human papillary thyroid carcinomas. *Cancer Res*, **59**, 467-73.
- Nelson AR, Fingleton B, Rothenberg ML, et al (2000). Matrix metalloproteinases: biologic activity and clinical implications. *J Clin Oncol*, **18**, 1135-49.
- Philchenkov A, Zavelevich M, Krocak TJ, et al (2004). Caspases and cancer: mechanisms of inactivation and new treatment modalities. *Exp Oncol*, **26**, 82-97.
- Prasad ML, Pellegata NS, Huang Y, et al (2005). Galectin-3, fibronectin-1, CITED-1, HBME1 and cytokeratin-19 immunohistochemistry is useful for the differential diagnosis of thyroid tumors. *Mod Pathol*, **18**, 48-57.
- Rajoria S, Suriano R, George A et al (2011). Estrogen induced metastatic modulators MMP-2 and MMP-9 are targets of 3,3'-diindolylmethane in thyroid cancer. *PLoS One*, **18**, 15879.
- Rosai J, Tallini G (2011). Thyroid gland. In: Juan Rosai, editor. Rosai and Ackerman's Surgical Pathology. 10th ed. Elsevier: Mosby, **1**, 487-565.
- Stolf BS, Santos MMS, Simao DF, et al (2006). Class distinction between follicular adenomas and follicular carcinomas of the thyroid gland on the basis of their signature expression. *Cancer*, **106**, 1891-900.
- Tryggvason K, Hoyhtya M, Ryke C (1993). Type IV collagenases in invasive tumors. *Breast Cancer Res Treat*, **24**, 209-18.
- Vermeulen K, Van Bockstaele DR, Berneman ZN (2005). Apoptosis: mechanisms and relevance in cancer. *Ann Hematol*, **84**, 627-39.
- Weidinger C, Karger S, Krause K, et al (2010). Distinct regulation of intrinsic apoptosis in benign and malignant thyroid tumors. *Horm Metab Res*, **42**, 553-6.