

RESEARCH COMMUNICATION

Significance and Expression of Aquaporin 1, 3, 8 in Cervical Carcinoma in Xinjiang Uygur Women of China

Yong-Hua Shi^{1*}, Rui Chen², Tuokan Talafu¹, Rehemu Nijiati¹, Suzuke Lalai¹

Abstract

Overexpression of several aquaporins (AQPs) has been reported in different types of human cancer but their role in carcinogenesis, for example in the cervix, have yet to be clearly defined. In this study, expression of AQPs in cervical carcinoma was investigated by real-time PCR, immunofluorescent and immunohistochemical assays and evaluated for correlations with clinicopathologic variables. AQP1, 3, 8 exhibited differential expression in cervical carcinoma, corresponding CIN and mild cervicitis. AQP1 was predominantly localized in the microvascular endothelial cell in the stroma of mild cervicitis, CIN and cervical carcinoma. AQP3 and AQP8 were localized in the membrane of normal squamous epithelium and carcinoma cells, local signals being more common than diffuse staining. AQP1 and AQP3 expression was remarkably stronger in cervical cancer than in mild cervicitis and CIN2-3 ($P < 0.05$). AQP8 expression was highest in CIN2-3 (91.7%), but levels in cervical carcinoma were also higher than in mild cervicitis. AQP1, AQP3, AQP8 expression significantly increased in advanced stage, deeper infiltration, metastatic lymph nodes and larger tumor volume ($P < 0.05$). Our findings showed that AQPs might play important roles in cervical carcinogenesis and tumour progression in Uygur women.

Keywords: AQPs - cervical carcinoma - differential expression - Uygur women - China

Asian Pacific J Cancer Prev, 13, 1971-1975

Introduction

The aquaporins (AQPs) are a family of hydrophobic, small, and integrated transmembrane glycoproteins (30kDa monomer) that distribute widely in the bodies of animals and plants, closely related with transmembrane water transport, and so far the discovery of AQPs, 13 mammalian homologs (AQPs 0~12) have been identified (Verkman et al., 2008). All vital movements of cancer cells depend on water microenvironment, especially transmembrane transport. Recent studies alluded to the key role of AQPs in human carcinogenesis. For example, AQPs abnormally expressed in the tumor cells and stroma of the female malignant tumors such as breast carcinoma and endometrial carcinoma (Pan et al., 2008; Otterbach et al., 2010). The research on correlation of AQPs with cervical cancer is uncommon in document reports. In this study, we probed the effects of AQP1, AQP3, AQP8 on cervical carcinogenesis, invasion, metastasis and their clinical significance for Xinjiang Uygur women of China.

Materials and Methods

Human cervical lesion tissues and reagents

Real-time PCR examination of AQP1, AQP3, AQP8 in the tissues were performed using 30 cases of fresh tissues containing mild cervicitis and invasive cervical cancers, obtained from gynecological operation of Department of

Gynecology, Third Affiliated Hospital of Xinjiang Medical University. These samples were obtained from 11th month of 2008 to 8th month of 2010, and included 10 cases of mild cervicitis, 10 cases of early cervical cancer and 10 cases of advanced cervical cancer. Paraformaldehyde-fixed and paraffin-embedded tissues were used to immunohistochemistry, including 36 cases of CIN2-3, 98 cases of cervical carcinoma and 42 cases of mild cervicitis. Tumor clinical stage was according to FIGO (federation international of gynecology and obstetrics).

Trizol (Invitrogen, USA); First strand cDNA synthesis kit (Promega, USA); PCR kit (Fermentas, Lithuania); AQP1, 3, 8 primary rabbit polyclonal antibody (Santa-Cruz); Secondary goat antibody (Zhongshan Goldenbridge, China).

Real-time PCR

Total RNA from human cervical lesion tissues was extracted using Trizol, cDNA synthesis was performed according to the manufacturer's instructions. Real-time PCR procedure: fore-denaturalization 95 °C 5 min, denaturalization 95 °C 30 s, renaturation 60 °C 30 s, amplification 72 °C 30 s, for 35 cycles, extension 72 °C 5 min. PCR products were identified by 1.5% agarose gel electrophoresis. Expressing abundance of AQP genes was calculated according to AQP/actin. Primer sequences are listed in (Table 1), actin being considered as a house keeping gene.

¹Department of Pathology, Basic Medicine School of Xinjiang Medical University, ²Department of Gynecology, Third Affiliated Hospital of Xinjiang Medical University, Urumqi, Xinjiang, China *For correspondence: z5826711@126.com

Table 1. Primer Sequences and Size of AQP1, AQP3, AQP8 and House Keeping Gene Actin

Primer	Sequences	Size of products (bp)
AQP1 sense	GCTGGTGCTATGCGTGCTG	250
AQP1 antisense	CAGGATGAAGTCGTAGATGAGTACAG	
AQP3 sense	CATTGCGGGTGTCTTCGTG	177
AQP3 antisense	GGACAGTCAGTGGATGCTCAAG	
AQP8 sense	GCCATCAATGAGAAGACAAAGG	213
AQP8 antisense	CCTAATGAGCAGTCCAACAAGC	
Actin sense	CATGTACGTTGCTATCCAGGC	250
Actin antisense	CTCCTTAATGTCACGCACGAT	

Immunofluorescence analysis

Tissues were embedded by OCT, frozen sections were made and fixed for 10 min in cold acetone, washed 3 times with PBS, 5 min /time and stained with primary antibody of anti-AQP1, AQP3, AQP8 overnight at 4 °C, followed by fluorescein isocyanate-labeled secondary antibody for 45 min. After washing, mounting media including buffering glycerine was added, and coverslips were mounted. PBS instead of primary antibody was used as negative control, AQP positive normal cervical tissue was used as control. Repeated experiments were performed for doubtful cases.

Immunohistochemistry

4% paraformaldehyde-fixed cervical lesion tissues were prepared for 2 μm thickness sections on the slides. The sections were labeled by anti-AQP1, AQP3, AQP8 primary antibody (1:400, 1:100, 1:100, respectively) at 4 °C overnight, then by Polymer Helper for 20 min, secondary antibody for 30 min at room temperature. Following DAB (3, 3'-diaminobenzidine) coloration, hematoxylin counterstaining, dehydration, transparency, mounting were performed. AQP3, AQP8 immunolabeling was reviewed by expert pathologists, the intensity and proportion were scored as negative (-), dilute brown (score 1), brown (score 2), and deep brown (score 3). Proportions of positive tumor cells were scored as 0~4% (-), 5%~25% (score 1), 26%~50% (score 2), 51%~75% (score 3), and ~75% (score 4). Intensity was negative (score 0~1), +(score 2~3), ++(score 4~5), +++(score 6~7). Microvessel density (MVD) was used as AQP1 immunolabeling interpretation. Counting method of MVD: brown-staining endothelial cell membrane or cytoplasm was positive. Three areas of highest neovascularization were found by scanning the sections at low power (100x), MVD were counted at high power (200x), excluding hemorrhage, inflammatory reaction and borderline areas.

Statistical analysis

Data were expressed as the mean ± standard deviation. Statistical differences among groups were compared using the one-ANOVA for measurement data and X² test for numeration data. P<0.05 was considered significant.

Results

AQP1, AQP3, AQP8 mRNA levels

Real-time PCR was performed, AQP1, AQP3, AQP8 mRNA were detected, and the PCR products

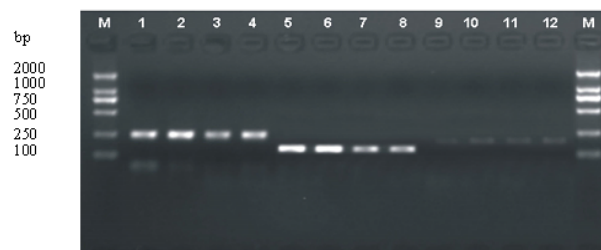


Figure 1. 1, 2, 3, 4: AQP1 electrophotogram, 1, 2 for mild cervicitis, 3 for cervical cancer in early stage, 4 for cervical cancer in advanced stage; 5, 6, 7, 8 : AQP3 electrophotogram, 5, 6 for mild cervicitis, 7 for cervical cancer in early stage, 8 for cervical cancer in advanced stage; 9, 10, 11, 12: AQP8 electrophotogram, 9, 10 for mild cervicitis, 11 for cervical cancer in early stage, 12 for cervical cancer in advanced stage

Table 2. AQP1, AQP3, AQP8 mRNA Expression Among Groups (x̄±s)

AQPs	groups	n	Expressing abundance	F value	P value
AQP1	Mild cervicitis	10	1.007±0.016	210.9	<0.01
	Early cervical cancer	10	1.770±0.006		
	Advanced cervical cancer	10	3.954±0.262		
AQP3	Mild cervicitis	10	1.008±0.019	227.5	<0.01
	Early cervical cancer	10	1.999±0.064		
	Advanced cervical cancer	10	3.721±0.166		
AQP8	Mild cervicitis	10	1.011±0.023	210.21	<0.01
	Early cervical cancer	10	1.874±0.029		
	Advanced cervical cancer	10	3.545±0.188		

were electrophoresed (Figure 1). Difference of AQP1, AQP3, AQP8 expressing abundance among groups was significant (P<0.05) (Table 2).

Localization and abnormally high expression of AQP1, AQP3, AQP8 in cervical carcinoma tissues

Immunofluorescence and immunohistochemistry assays were performed. AQP1, AQP3, AQP8 proteins expressed in mild cervicitis, CIN and cervical carcinoma. AQP1 was observed to be predominantly localized in the microvascular endothelial cell in the stroma of mild cervicitis and cervical carcinoma (Figure 2A), and AQP1 expression in cervical carcinoma was significantly higher than CIN and mild cervicitis (Table 3). AQP3, AQP8 localized in the membrane of normal squamous epithelium and carcinoma cells, local positive signals were more common than diffuse positive signals (Figure 2B, Figure 2C, Figure 3, Figure 4). AQP3 expression gradually increased in mild cervicitis, CIN2-3, and cervical cancer groups (P<0.05). AQP8 expression was highest in CIN2-3 group which was 91.67%, AQP8 expression in cervical carcinoma was higher than in mild cervicitis (P<0.05) (Table 4).

AQP1, AQP3, AQP8 expression in cervical carcinoma is correlated with clinicopathologic parameters

Correlation of AQP1, AQP3, AQP8 expression in cervical carcinoma with clinicopathologic parameters was analyzed (see Table 5). AQP1, AQP3, AQP8 expression significantly increased in advanced stage, in deeper infiltration, in metastatic lymph nodes and in larger tumor volume (P<0.05). AQP1, AQP3, AQP8 expression in

Table 3. AQP1 Expression in Cervical Lesion Tissues

groups	n	AQP1 (MVD)
Mild cervicitis	42	37.51±14.62*
CIN2-3	36	56.05±27.51**
Cervical cancer	98	69.84±34.93***

***P<0.01 vs Mild cervicitis; **P<0.01 vs cervical cancer; *P<0.05 vs CIN2-3

Table 4. AQP3, AQP8 Expression in Cervical Lesion Tissues

groups	n	AQP3		AQP8			
		+ x ² value	P value	+ x ² value	P value		
Mild cervicitis	42	7	14.5	<0.01	22	20.76	<0.01
CIN2-3	36	10			33		
Cervical cancer	98	44			55		

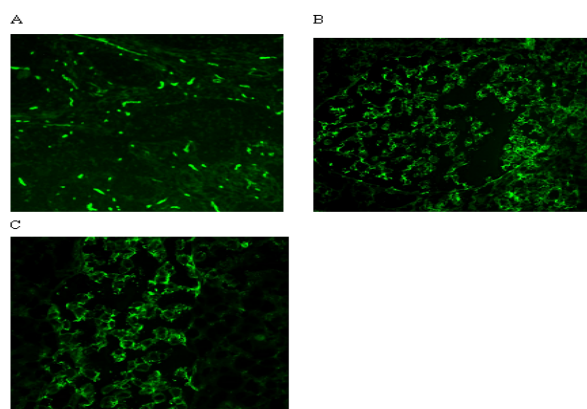


Figure 2. (A) AQP1 Expression in Microvascular Endothelial Cell of Cervical Carcinoma; (B) AQP3 expression in the membrane of cervical carcinoma cells; (C) AQP8 expression in the membrane of cervical carcinoma cells (x200)

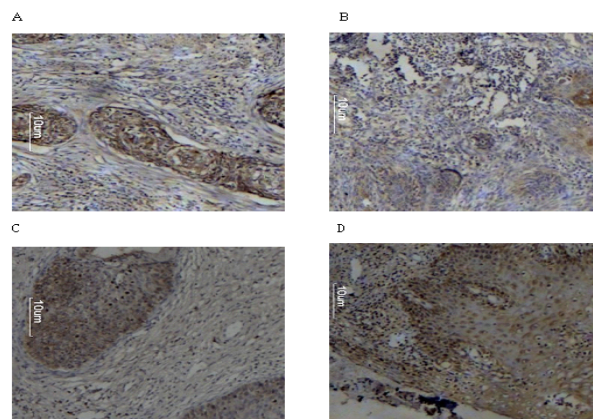


Figure 3. (A) AQP3 Diffuse Expression in Cervical Cancer; (B) AQP3 local expression in cervical cancer; (C) AQP3 expression in CIN; (D) AQP3 expression in mild cervicitis

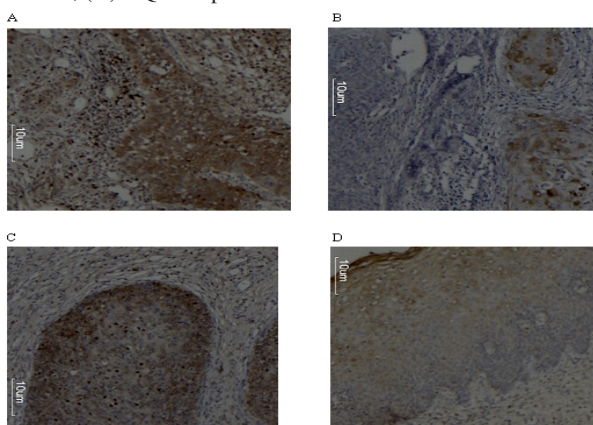


Figure 4. (A) AQP8 Diffuse Expression in Cervical Cancer; (B) AQP8 local expression in cervical cancer; (C) AQP8 expression in CIN; (D) AQP8 expression in mild cervicitis

Table 5. Correlation of AQP1, AQP3, AQP8 Expression in Cervical Carcinoma with Clinicopathologic Parameters

Clinico-pathologic parameter	n	AQP1		P value	AQP3			AQP8		
		MVD	F value		+	x ² value	P value	+	x ²	P value
Stage										
I	14	59.83±18.56	6.633	0.002	4	6.39	0.048	6	7.79	0.02
II	52	68.53±21.59			20			23		
III	32	79.87±19.89			20			25		
Grade										
G1+G2	62	67.29±19.83	1.237	0.296	29	0.657	0.72	38	1.676	0.433
G3	36	75.16±21.00			15			17		
Infiltrating depth										
≤1/2	55	68.71±23.77	6.76	0.011	19	4.28	0.043	26	3.987	0.046
>1/2	43	72.07±20.86			25			29		
Metastatic lymph node										
-	42	65.01±21.94	12.038	0.001	20	12.513	0	26	6.661	0.01
+	56	78.16±14.23			24			29		
Age										
≤45	50	70.53±19.61	0.249	0.619	21	2.785	0.249	28	2.629	0.269
>45	48	70.62±20.73			23			27		
Tumor diameter										
≤5cm	40	66.41±19.12	5.987	0.001	14	16.45	0	17	26.584	<0.01
<5cm	58	76.28±23.10			30			38		
Gross type										
Exogenic	27	77.85±27.73	3.343	0.022	13	3.153	0.369	13	7.035	0.071
Ulceric	25	75.52±15.97			11			12		
Nodular	22	60.84±15.78			10			11		
Endogenic	24	75.10±21.96			10			19		

cervical carcinoma was not related with pathological grade and patient age ($P > 0.05$).

Discussion

Cervical cancer is generally the most common cancer in developing countries and the second most common in women globally (Farivar et al., 2012). In Xinjiang of China, especially South of Xinjiang, incidence of cervical carcinoma for Uygur women is very high, and its prevalence is 527/100,000, and about 80% patients are in the advanced stage while visiting doctors' office (Peng et al., 2003). Studies confirmed that AQPs overexpressed in many kinds of tumor tissues, their vascular endothelial cell and tumor cell lines, and this hinted that AQPs were close to tumorigenesis and tumor progress. For example, AQP5 overexpression was related with in cell growth and metastasis of human breast cancer (Jung et al., 2011). Human AQP1 expression was close to brain glioma (Hayashi et al., 2007). AQP3 and AQP5 expression increased in the gastric carcinoma tissues, both AQP3 and AQP5 expression were associated with lymph node metastasis and lymphovascular invasion in patients (Shen et al., 2010). But there is few reports concerning the expression and role of AQPs in human cervical carcinogenesis so far.

In this study, we detected AQP1, AQP3, AQP8 expression in cervical lesion tissues of Uygur women by real-time PCR, immunofluorescence, and immunohistochemistry, respectively, and analyzed correlation of their expression with clinicopathologic characteristics of patients. We found that AQP1, AQP3, AQP8 exhibited differential expression among cervical carcinoma, corresponding CIN and normal tissues at the levels of mRNA and protein. Immunohistochemical and immunofluorescence assays showed that AQP1 protein was expressed mainly in vascular endothelial cell, and AQP3, AQP8 was localized in the epithelial membrane of mild cervicitis, CIN and cervical carcinoma tissues. AQP1, AQP3 expression were detected remarkably stronger in carcinoma tissues than corresponding CIN and mild cervicitis, AQP8 expression was highest in CIN, and AQP1, AQP3, AQP8 expression increased markedly in advanced stage, metastatic lymph node, larger tumor size, deeper infiltration. MVD is used to represent tumor angiogenesis, and it is an accepted reliable indicator to evaluate tumor angiogenesis. In this study, MVD is used to represent AQP1 protein expression. Our results showed that AQP1 was close to tumor vascularization and played an important role in the invasion and metastasis of cervical carcinoma. There are no blood vessels in the initial phase of tumor growth, tumor tissues mainly acquire nutrition by interstitial fluid diffusion. When a tumor grows to 1-2 mm, the formation of neovessels will occur. Formation of neoplasm metastasis focus demands neovessels provide nutrition too. Some animal experiment confirmed that in AQP1- knockout mice, tumor growth slowed down, angiogenesis decreased and general necrosis emerged from tumor tissues (Saadoun et al., 2005). Our results indicated that AQP3, AQP8 may play a certain role in advancement, infiltration and metastasis of cervical carcinomas.

Similar reports were also seen in relative documents. For example, Kusayama et al. (2011) reported that a high level expression of AQP3 was observed in tumor areas of primary squamous cell carcinomas such as esophageal and lingual cancers, and lymph node metastasis. Galamb et al. (2007) pointed that AQP8 overexpressed in colorectal cancer by using gene chips. In this study, AQP8 expression rate in CIN was 91.67%, higher than in cervical cancer and normal tissues, we proposed that AQP8 played an important role in the process of precancerous lesion CIN transforming into cervical cancer. But Jablonski et al. (2007) reported that AQP8 expression down-regulated in mouse hepatocellular carcinoma model. Our results do not coincide with theirs. It is necessary to deeply probe AQP8 effects in tumorigenesis.

AQPs are a family of small transmembrane proteins that facilitate osmotically driven water transport, we propose that AQPs overexpression in cervical cancer may increase tumor cells permeability to water to alter tumor cells volume and shape, accordingly facilitate advancement, infiltration and metastasis of cervical carcinoma.

In summary, AQP1, AQP3, AQP8 expression abnormally increase in cervical carcinoma of Uygur women of China, and facilitate the advancement, invasion and metastasis, suggesting AQPs as targets potential for curing cervical carcinoma in future.

Acknowledgements

The authors thank Mingjun Duan and Qin Wei for helpful advice in the process of immunofluorescence assay. This study is supported by National Natural Science Foundation of China (Grant Number: 81060216).

References

- Farivar TN, Johari P, Shafei S, et al (2012). Lack of association between herpes simplex virus type 2 infection and cervical cancer--Taq Man realtime PCR assay findings. *Asian Pac J Cancer Prev*, **13**, 339-42.
- Galamb O, Gyorffy B, Sipos F (2007). Identification of colorectal cancer, adenoma, and inflammatory bowel disease specific gene expression patterns using whole genomic -oligonucleotide microarray system. *Orv Hetil*, **148**, 2067-79.
- Hayashi Y, Edwards NA, Proescholdt MA, et al (2007). Regulation and function of aquaporin-1 in glioma cells. *Neoplasia*, **9**, 777-87.
- Jablonski EM, Mattocks MA, Sokolov E, et al (2007). Decreased aquaporin expression leads to increased resistance to apoptosis in hepatocellular carcinoma. *Cancer Lett*, **250**, 36-46.
- Jung HJ, Park J-Y, Jeon H-S, et al (2011). Aquaporin-5: A marker protein for proliferation and migration of human breast cancer Cells. *PLoS one*, **6**, e28492.
- Kusayama M, Wada K, Nagata M, et al (2011). Critical role of aquaporin 3 on growth of human esophageal and oral squamous cell carcinoma. *Cancer Sci*, **102**, 1128-36.
- Otterbach F, Callies R, Adamzik M, et al (2010). Aquaporin 1 (AQP1) expression is a novel characteristic feature of a particularly aggressive subgroup of basal-like breast carcinomas. *Breast Cancer Res Treat*, **120**, 67-76.

- Pan H, Sun CC, Zhou CY, et al (2008). Expression of aquaporin-1 in normal, hyperplastic, and carcinomatous endometria. *Gynaecol Obstet*, **101**, 239-44.
- Peng YH, La-lai SZK, Zhou K, et al (2003). Clinical analysis for 4505 cases of cervical cancer. *Zhonghua Fu Chan Ke Zazhi*, **38**, 764-5.
- Saadoun S, Papadopoulos MC, Hara-Chikuma M, et al (2005). Impairment of angiogenesis and cell migration by targeted aquaporin-1 gene disruption. *Nature*, **34**, 786-92.
- Shen L, Zhu Z, Huang Y, et al (2010). Expression profile of multiple aquaporins in human gastric carcinoma and its clinical significance. *Biomed Pharmacother*, **64**, 313-8.
- Verkman AS, Hara-Chikuma M, Papadopoulos MC (2008). Aquaporins new players in cancerbiology. *J Mol Med*, **86**, 523-9.