

Maxillary expansion with the memory screw: a preliminary investigation

Koray Halicioğlu,^a
Ali Kiki,^b
İbrahim Yavuz^c

^a Assistant Professor, Department of
Orthodontics, Faculty of Dentistry,
Abant İzzet Baysal University, Bolu,
Turkey.

^b Assistant Professor, Department of
Orthodontics, Faculty of Dentistry,
Atatürk University, Erzurum, Turkey.

^c Professor and Chair, Department of
Orthodontics, Faculty of Dentistry,
Erciyes University, Kayseri, Turkey.

Objective: The purpose of this study was to investigate the effects of a newly developed rapid maxillary expansion screw-the memory screw-over 6 months.
Methods: Five subjects, aged between 11.7 and 13.75 years, were enrolled in this study. All subjects underwent placement of a maxillary expansion appliance containing superelastic nickel-titanium open-coil springs in its screw bed. The parents of the patients and/or the patients themselves were instructed to activate the expansion screw by 2 quarter-turns 3 times a day (morning, midday, and evening; 6 quarter-turns a day). The mean expansion period was 7.52 ± 1.04 days. Dentoskeletal effects of the procedure, including dentoalveolar inclination, were evaluated. Measurements of all the parameters were repeated after 6 months of retention in order to check for relapse. **Results:** Sella-Nasion-A point (SNA) and Sella-Nasion/Gonion-Menton angles increased, and Sella-Nasion-B point (SNB) angle decreased in all the subjects during the expansion phase. However, they approximated to the initial values at the end of 6 months. On the other hand, the increments in maxillary apical base (Mxr-Mxl) and intermolar widths was quite stable. As expected, some amount of dentoalveolar tipping was observed. **Conclusions:** The newly developed memory expansion screw offers advantages of both rapid and slow expansion procedures. It widens the midpalatal suture and expands the maxilla with relatively lighter forces and within a short time. In addition, the resultant increments in the maxillary apical base and intermolar width remained quite stable even after 6 months of retention.

[Korean J Orthod 2012;42(2):73-79]

Key words: Expansion, Appliances, Cephalometrics, Retention and stability

<http://dx.doi.org/10.4041/kjod.2012.42.2.73>

Received November 14, 2011; Last Revision February 6, 2012; Accepted February 7, 2012.

Corresponding author: İbrahim Yavuz.
Department of Orthodontics, Faculty of Dentistry, Erciyes University, Rektörlüğü 38039,
Kayseri, Turkey.
Tel +90 352 207 66 00 (29102) e-mail iyavuz@atauni.edu.tr

The authors report no commercial, proprietary, or financial interest in the products or companies described in this article.

This is an Open Access article distributed under the terms of the Creative Commons Attribution Non-Commercial License (<http://creativecommons.org/licenses/by-nc/3.0>) which permits unrestricted non-commercial use, distribution, and reproduction in any medium, provided the original work is properly cited.

INTRODUCTION

Posterior crossbite is one of the most frequent malocclusions diagnosed clinically.¹ Rapid maxillary expansion (RME) is the most common approach used to correct this anomaly. RME is the rapid physical separation of bones that embryologically develop from both sides and fuse at the midpalatal suture, thereby forming the premaxilla and the bony palate.²

The RME procedure, first described by Angell³ in 1860, is commonly used in the treatment of maxillary transverse deficiency. Almost a century later, Haas⁴ reintroduced RME into modern-day orthodontics. Thereafter, remarkable progress has been made in this procedure.

Several previous studies have been undertaken by Isaacson et al.,⁵ Isaacson and Ingram,⁶ and Zimring and Isaacson⁷ to investigate the forces generated during and after RME. The authors observed that the activation of the RME screw by 1 quarter-turn generated 3 - 10 pounds (1.4 - 4.5 kg) of force, which increased cumulatively, reaching 22 pounds (10 kg) on the 15th day of the RME protocol. The intensity of these forces has been reported to reduce sometime later in the retention period and continue decreasing thereafter. The authors stated that pressure sensations in the entire face, infraorbital region, or nose were the result of the accumulated forces. Isaacson and Ingram⁶ hypothesized that the expansion might become physiologically stable earlier, thereby reducing the net treatment time, if the expansion procedure involves lower forces.

Orthopedic loads generated during RME force the displacement of the bones adjacent to the maxilla. If these forces are not tolerated by the structures forming the maxillary complex, they may cause severe relapse and tipping of the anchorage teeth.

Darendeliler et al.⁸ and Vardimon et al.⁹ reported that maxillary expansion with light but continuous forces is feasible and might be less traumatic. This prompted many studies and the development of several appliances aimed at decreasing the heavy forces generated during maxillary expansion or applying only light but continuous forces.

Harberson and Myers¹⁰ reported that midpalatal sutural opening and crossbite correction can be achieved by using the W appliance in the deciduous or mixed dentition. Arndt¹¹ introduced the nickel-titanium (Ni-Ti) Expander, which is activated by oral temperature and applies 230 - 300 g force. Darendeliler et al.⁸ reported that they accomplished maxillary sutural expansion by using magnets that generate 250 - 500 g force.

In a more recent study, Wichelhaus et al.¹² introduced the "Memory Palatal Split Screw" (Forestadent, Pforzheim, Germany; Forestadent USA, 2315 Weldon Parkway, St. Louis, MO 63146; Catalog No: 167M1529). They tested this screw both in clinical practice and in the laboratory

by using the Instron universal testing machine and plotted force (N)/deflection (mm) curves for the 6th, 12th, and 24th activations. The investigators found that when the screw was activated 6 times a day, it produced a constant force of 12 - 14 N (1,224 - 1,428 g), which is 2 - 3 times lower than that produced by the conventional screw. In the light of the suggestion by Isaacson and Ingram⁶ that a constant force with a low load deflection rate might be the most ideal approach, our preliminary study was aimed at examining the dentoskeletal effects of the memory screw in 5 cases followed up for 6 months.

MATERIAL AND METHODS

Preparation of the appliance and the activation schedule

Informed consents were obtained from the subjects and their parents on enrollment of the patients. Bands of appropriate sizes were seated on the maxillary first premolars and first molar teeth of both sides. An impression with alginate was made, and the bands were transferred to it. Next, a working model was poured in plaster.

The "Memory Palatal Split Screw" described by Wichelhaus et al.¹² was used in the present study. It incorporates superelastic Ni-Ti open-coil springs in the screw bed, which reduce excessive expansion forces. Special precaution was taken to position the screw body parallel to the occlusal plane and as close as possible to the palatal mucosa. Anterior arms of the screw were soldered to the first premolar bands, and the posterior arms were soldered to the first molar bands. In addition, a piece of stainless steel wire (diameter, 1 mm) was soldered between the first premolar and first molar bands. The appliance was cemented using glass ionomer cement. Parents of the patients and/or the patients themselves were instructed to activate the screw by 2 quarter-turns (0.4 mm) 3 times a day (morning, midday, and evening), as proposed by Wichelhaus et al.¹² The expansion was stopped when the palatal cusp of the upper molar teeth occluded with the buccal cusp of the lower molar teeth. The minimum and maximum degrees of expansion were 40 quarter-turns (8 mm) and 50 quarter-turns (10 mm), respectively, and the mean expansion period was 7.52 ± 1.04 days. For stabilization, the appliances were retained in the mouth for 6 months after expansion was completed. The dentoskeletal changes induced by RME were evaluated by lateral (Fig 1) and posteroanterior (Fig 2) cephalograms.

Determination of dentoalveolar tipping

Several methods have been developed for the evaluation of dentoalveolar tipping occurring during RME. Since it has been claimed to be an easy procedure, the method proposed by Oktay and Kiliç¹³ was used in the present

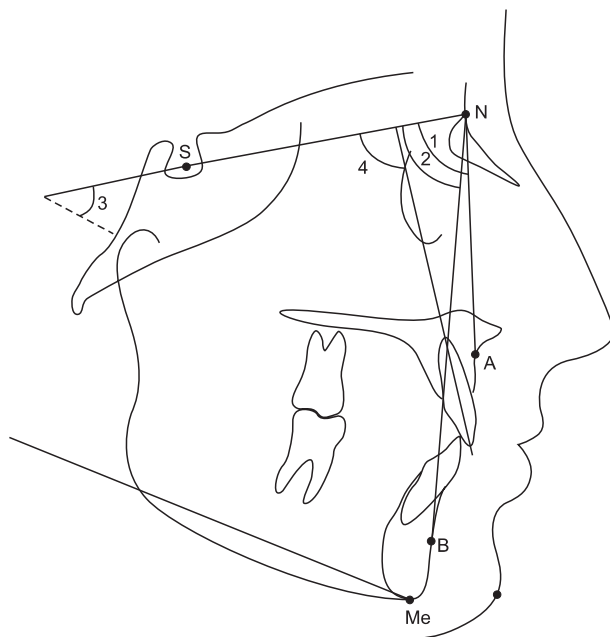


Fig 1. Landmarks and angular measurements on lateral cephalometric radiograph. The sella-nasion-A point (SNA) (1) angle relates to the anteroposterior position of the maxillary apical base to a line passing through the anterior cranial base. The sella-nasion-B point (SNB) (2) angle relates to the anteroposterior position of the mandibular apical base to a line passing through the anterior cranial base. The mandibular plane–anterior cranial base plane (sella-nasion/gonion-menton [SN-GoMe]) (3) angle relates to the cant of the mandibular plane to a line passing through the anterior cranial base. The maxillary incisor to anterior cranial base plane (1-SN) (4) angle relates to the axial inclination of the most labial maxillary incisor to a line passing through the anterior cranial base.

study. As described by the authors, a thin line (1 mm in diameter) was drawn on maxillary stone casts with a paintbrush by using barium sulphate solution. The line was started at the gingival margin of the mesio-buccal cusp of the upper right first molar, passed through the tips of the mesio-buccal and mesio-palatal cusps of the tooth and the palatal vault between the first molars, and ended at the vestibular gingival margin of the upper left first molar. Then, the plaster models were placed in a plastic box with cabinets to allow the passage of X-rays, and a radiographic image was obtained.

Right ($\alpha 1$) and left molar crown tipping ($\alpha 2$) and alveolar process inclination ($\alpha 3$) caused by RME were determined with the aid of landmarks traced on the image (Fig 3). Treatment progress of a patient has been demonstrated in Figs 4-7.

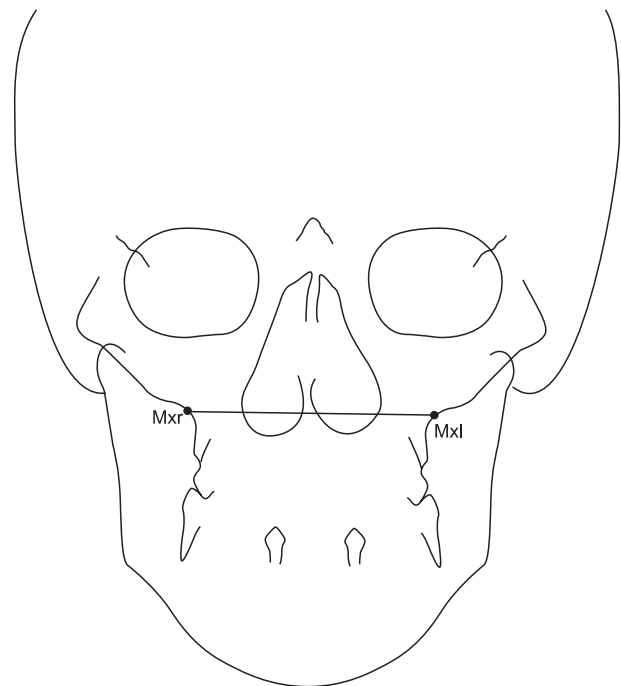


Fig 2. Landmarks and linear measurement on postero-anterior radiograph. Maxillary-maxillary apical base width (Mxr-Mxl) was defined as the horizontal distance between the right and left intersections of the lateral contour of the maxillary alveolar process and the lower contour of the zygomatic process of the maxilla.

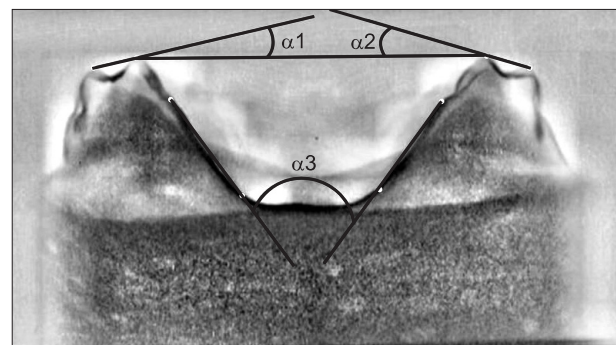


Fig 3. Formation of the angles used for inclination assessment. $\alpha 1$ (right molar tipping angle) and $\alpha 2$ (left molar tipping angle), inner angles between the transversal occlusal line connecting the mesio-palatal cusp tips of the right and left molars and the lines passing through the mesio-buccal and mesio-palatal cusp tips of the molars. $\alpha 3$ (palatal tipping angle), inner angle between the right and left alveolar lines connecting the upper and lower alveolar tipping points on each side.

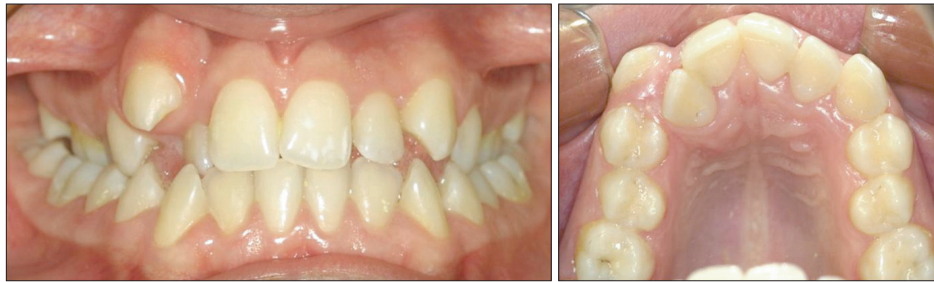

Fig 4. Pretreatment photographs of a patient.

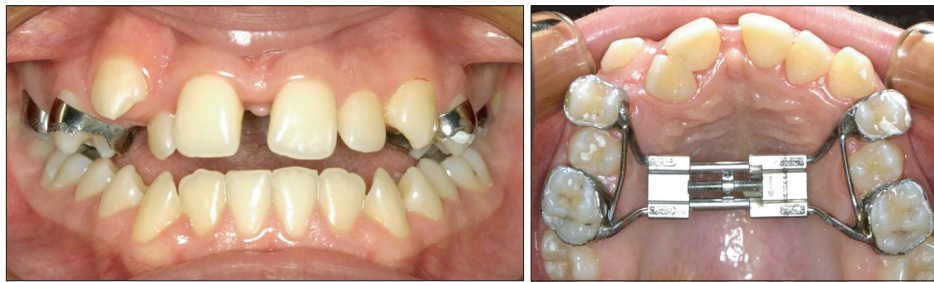

Fig 5. Photographs after the completion of maxillary expansion.

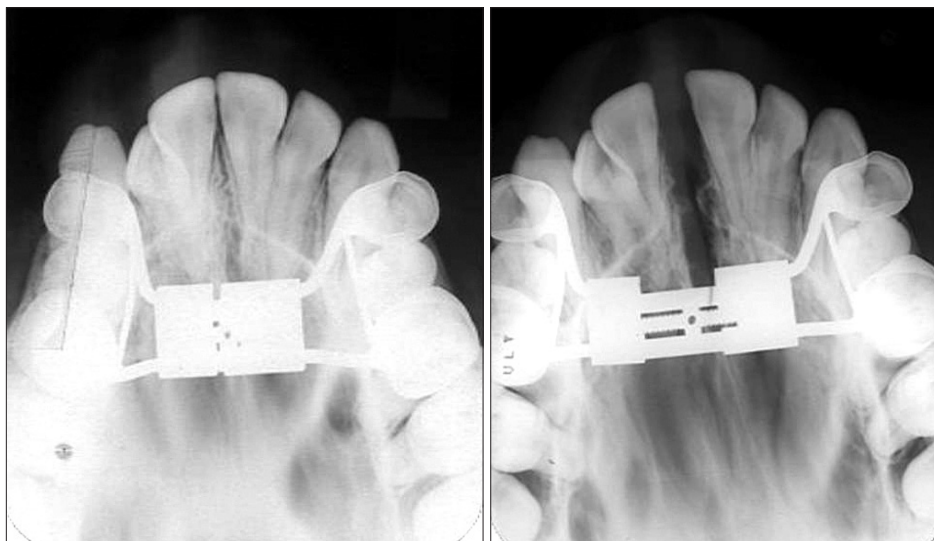


Fig 6. Occlusal radiograph showing sutural separation.

RESULTS

Dentoskeletal effects

Parameters measured in each individual during the observation period are listed below. The measurements are provided in Table 1.

Sella-nasion-A point (SNA): In all subjects, the SNA angle increased at the expansion phase and some recovery took place at retention. However, at the end of 6 months (T2), the SNA angle was still greater than that at the beginning (T0).

Sella-nasion-B point (SNB): With RME, the SNB angle decreased in every subject; however, it was restored

almost totally by the end of the retention period.

Sella-nasion/Gonion-menton (SN-GoMe): This angle increased by approximately 2 degrees in each patient during the expansion phase. A partial recovery took place by retention.

Upper incisor inclination (I-SN): In all the subjects, a slight increase was seen in this angle at first, but it decreased thereafter.

Maxillary apical base width (Mxr-Mxl): The maxillary apical base width increased by more than 4 mm in all subjects but one. The increments remained fairly stable during the retention period.

Intermolar width: The increment in this dimension was

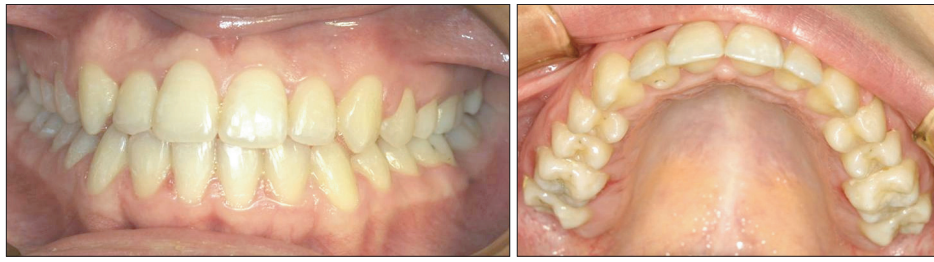


Fig 7. Post-treatment photographs.

Table 1. Dentoskeletal measurements during the observation period

	Patient	1	2	3	4	5
	Sex Age (yr)	Male 12.7	Female 13.75	Female 13.25	Male 11.7	Female 13
Sella-nasion-A point (SNA) (°)	T0	75.7	77.0	77.7	76.9	70.8
	T1	77.9	77.6	79.2	79.1	71.8
	T2	76.0	77.3	78.3	78.5	71.2
Sella-nasion-B point (SNB) (°)	T0	72.3	78.3	76.6	77.0	70.0
	T1	72.0	75.7	76.0	76.6	68.5
	T2	72.2	77.3	76.4	77.1	70.9
Sella-nasion/Gonion-menton (SN-GoMe) (°)	T0	36.1	37.3	36.1	35.2	37.9
	T1	38.1	39.3	38.1	37.1	39.6
	T2	36.9	38.7	37.4	36.4	39.1
Upper incisor inclination (I-SN) (°)	T0	88.5	104.2	103.1	102.6	96.4
	T1	89.3	107.1	104.8	103.2	98.0
	T2	88.0	99.8	102.5	101.8	95.2
Maxillary apical base width (Mxr-Mxl) (mm)	T0	64.6	63.7	57.3	56.6	57.9
	T1	69.3	67.9	61.6	60.4	62.3
	T2	69.3	67.8	61.7	60.2	62.3
Intermolar distance (mm)	T0	41.84	38.87	37.33	38.33	38.53
	T1	50.78	46.65	44.16	46.55	47.46
	T2	51.78	46.99	44.85	47.78	48.41
Right molar crown tipping (α_1) (°)	T0	3.80	3.20	8.60	4.40	1.10
	T1	12.80	11.20	13.60	17.30	12.40
	T2	13.10	11.40	10.30	21.60	11.10
Left molar crown tipping (α_2) (°)	T0	11.80	5.60	15.80	5.90	1.40
	T1	19.70	16.40	16.80	20.00	12.60
	T2	20.10	16.80	19.00	21.60	13.20
Alveolar process inclination (α_3) (°)	T0	61.00	44.50	67.10	49.80	59.10
	T1	72.90	54.10	73.50	62.70	68.40
	T2	73.00	54.50	74.20	63.10	68.50

between 6.83 and 8.94 mm. It continued to increase during the retention period.

Right molar tipping: All subjects showed increases in right molar tipping as a result of RME. In 2 patients, recovery was seen to some extent at retention; however, tip-

ping continued to increase in the remaining subjects.

Left molar tipping: In all the subjects, the degree of left molar tipping increased during both the active and retention periods.

Alveolar process inclination: Alveolar processes tipped

by an average of 10.02 degrees with expansion and remained relatively stable during retention.

DISCUSSION

Several screw-activation schedules have been advocated for RME. In the study by Haas,⁴ on the first day, the screw was given a full turn over a 15-minute period, i.e., a quarter-turn every 5 minutes; thereafter, the screw was activated twice daily. Biederman¹⁴ began the schedule with 3 quarter-turns daily, followed by 1 quarter-turn each in the morning and night. Zimring and Isaacson⁷ recommended that a regimen of quarter-turns twice daily for the first 4 to 5 days, followed by activation once a day throughout the remaining treatment period. Thus, activation twice daily is the most commonly recommended schedule. However, the screw introduced by Wichelhaus et al.¹² is activated 6 quarter-turns per day, and the present study was aimed at evaluating the dentoskeletal effects of this unusual procedure over a 6-month period.

The maxillary expansion procedure has both dental and skeletal effects. During RME, heavy forces are applied to induce skeletal expansion, and although unwanted, dentoalveolar tipping occurs unavoidably.¹⁵⁻²⁰

RME is thought to bring about a forward displacement of the maxilla.^{4,18,21} However, during the period of stabilization, the predominant movement of the maxilla is reported to be in the direction of recovery, as noted in our study.¹⁸ Further, according to Wertz,¹⁶ RME almost always causes the mandibular plane angle to open, and this opening is usually accompanied by a diminished SNB angle. This finding is also in agreement with ours. Moreover, maxillary incisors have been reported to drop back and decrease their angulations, as observed in our study.¹⁸

Although relapse after maxillary expansion is a common concern discussed in the literature,^{17,22,23} we did not find any decrease in MxR-MrL and intermolar dimensions in the present study during the 6-month retention period. Conversely, intermolar width continued to increase in this period. This was most probably the effect of the Ni-Ti springs present in the screw bed. In fact, during the retention period, these Ni-Ti springs may resist the residual forces, which are believed to be the cause of relapse.

Right molar, left molar, and palatal tipping values (9.24, 9, and 10.02 degrees, respectively) measured at the completion of the expansion phase (T1) in this study were similar to those noted in the study by Kiliç et al.¹⁵ (9.47, 9.16, and 11.30 degrees, respectively), which used the same method for tipping evaluation.

In contrast, molar teeth are expected to tip during expansion and are upright at retention.¹⁷ However, in the

present study, the right and left molar tipplings ($\alpha 1$ and $\alpha 2$) were noted to generally increase during the retention period. This, again, can be attributed to the Ni-Ti springs in the screw that exert continuous force and prevent molar teeth from becoming upright.

Considering the aforementioned points, the maxillary expansion procedure using the memory screw introduced by Wichelhaus et al.¹² can be considered a combination of rapid and slow expansion protocols. Since the screw is activated 6 times a day and the active phase of the treatment is completed in almost a week, it is a very rapid (maybe an ultra-rapid) expansion procedure. Moreover, the integrated springs have been reported to produce forces 2 - 3 times weaker (1,224 - 1,428 g) than those generated by conventional screws.^{9,12} Therefore, the force generated is almost similar to that generated in the slow expansion procedure. (Hicks¹⁷ described a slow maxillary expansion by using 2 pounds-approximately 900 g-of force.)

CONCLUSION

We postulated that the use of the newly developed memory screw, which generates relatively low and constant forces, enables the completion of the active phase of maxillary expansion in almost a week. The dentoskeletal effects of the procedure appear similar to those of conventional screws, except for increased dentoalveolar tipping, which occurred with the memory screw. Neither relapse nor any complications were observed during the observation period of 6 months. However, long-term investigations on larger samples may be more conclusive.

REFERENCES

1. Kuroi J, Berglund L. Longitudinal study and cost-benefit analysis of the effect of early treatment of posterior cross-bites in the primary dentition. *Eur J Orthod* 1992;14:173-9.
2. Lamparski DG Jr, Rinchuse DJ, Close JM, Sciote JJ. Comparison of skeletal and dental changes between 2-point and 4-point rapid palatal expanders. *Am J Orthod Dentofacial Orthop* 2003;123:321-8.
3. Angell EC. Treatment of irregularities of the permanent or adult teeth. *Dent Cosmos* 1860;1:540-4.
4. Haas AJ. Rapid expansion of the maxillary dental arch and nasal cavity by opening the midpalatal suture. *Angle Orthod* 1961;31:73-90.
5. Isaacson RJ, Wood JL, Ingram AH. Forces produced by rapid maxillary expansion. I. Design of the force measuring system. *Angle Orthod* 1964;34:256-60.
6. Isaacson RJ, Ingram AH. Forces produced by rapid maxillary expansion. II. Forces present during treatment. *Angle Orthod* 1964;34:261-70.

7. Zimring JF, Isaacson RJ. Forces produced by rapid maxillary expansion. III. forces present during retention. *Angle Orthod* 1965;35:178-86.
8. Darendeliler MA, Strahm C, Joho JP. Light maxillary expansion forces with the magnetic expansion device. A preliminary investigation. *Eur J Orthod* 1994;16:479-90.
9. Vardimon AD, Graber TM, Voss LR. Stability of magnetic versus mechanical palatal expansion. *Eur J Orthod* 1989;11:107-15.
10. Harberson VA, Myers DR. Midpalatal suture opening during functional posterior cross-bite correction. *Am J Orthod* 1978;74:310-3.
11. Arndt WV. Nickel titanium palatal expander. *J Clin Orthod* 1993;27:129-37.
12. Wichelhaus A, Geserick M, Ball J. A new nickel titanium rapid maxillary expansion screw. *J Clin Orthod* 2004;38:677-80.
13. Oktay H, Kiliç N. Evaluation of the inclination in posterior dentoalveolar structures after rapid maxillary expansion: a new method. *Dentomaxillofac Radiol* 2007;36:356-9.
14. Biederman W. Rapid correction of Class 3 malocclusion by midpalatal expansion. *Am J Orthod* 1973;63:47-55.
15. Kiliç N, Kiki A, Oktay H. A comparison of dentoalveolar inclination treated by two palatal expanders. *Eur J Orthod* 2008;30:67-72.
16. Haas AJ. Palatal expansion: just the beginning of dentofacial orthopedics. *Am J Orthod* 1970;57:219-55.
17. Hicks EP. Slow maxillary expansion. A clinical study of the skeletal versus dental response to low-magnitude force. *Am J Orthod* 1978;73:121-41.
18. Wertz RA. Skeletal and dental changes accompanying rapid midpalatal suture opening. *Am J Orthod* 1970;58:41-66.
19. Mossaz-Joëlsion K, Mossaz CF. Slow maxillary expansion: a comparison between banded and bonded appliances. *Eur J Orthod* 1989;11:67-76.
20. Ciambotti C, Ngan P, Durkee M, Kohli K, Kim H. A comparison of dental and dentoalveolar changes between rapid palatal expansion and nickel-titanium palatal expansion appliances. *Am J Orthod Dentofacial Orthop* 2001;119:11-20.
21. Sarver DM, Johnston MW. Skeletal changes in vertical and anterior displacement of the maxilla with bonded rapid palatal expansion appliances. *Am J Orthod Dentofacial Orthop* 1989;95:462-6.
22. Krebs AA. Expansion of mid palatal suture studied by means of metallic implants. *Acta Odontol Scand* 1959;17:491-501.
23. Sarnäs KV, Björk A, Rune B. Long-term effect of rapid maxillary expansion studied in one patient with the aid of metallic implants and roentgen stereometry. *Eur J Orthod* 1992;14:427-32.