



Discrepancies in Soft Tissue Profile of Patients for Orthognathic Surgery between Preoperative Lateral Facial Photograph, Lateral Cephalogram and Supine Position on Operation Table

Young-Eun Jung, Hoon Joo Yang, Soon Jung Hwang

Department of Oral and Maxillofacial Surgery, School of Dentistry, Seoul National University

Abstract

Purpose: An accurate preoperative analysis of the patient is essential in orthognathic surgery in order to acquire superior results. In profile, the location of the chin's position may change according to the neck's inclination. This may ultimately affect the amount of surgical movement. During acquisition of cephalometric radiographs, or in supine position, there is a discrepancy in the neck's inclination. This means that there are also various discrepancies between the actual profile and the various preoperative profile images. In the clinical situation, the decision in performing genioplasty usually lies in the analysis of the patient's profile on the operating table at the final stages of orthognathic surgery. This study aims to analyze the different preoperative profile images and to compare their discrepancies.

Methods: Fifty eight patients undergoing orthognathic surgery were chosen. These patients were divided into three groups according to angle's classification of malocclusion, as class I, II or III. The right profile of these patients in centric occlusion was taken in natural head position (NHP). This was set as the 'actual profile image.' Another right profile image was taken on the operating table after insertion of the nasotracheal intubation and with muscle relaxants in effect. This was also taken in centric occlusion. The angle (denoted 'A') between the soft tissue glabella-pogion and the true vertical plane was found in the above-mentioned profile images and in the cephalometric radiographs. The differences of these values were analyzed.

Results: There were differences in Angle 'A' in all of the preoperative images. These values were however, not statistically significant.

Conclusion: In order to gain an esthetic profile during orthognathic surgery, the NHP is shown to be the most reliable position. Images reproducing such head positions should be used in the treatment planning process.

Key words: Cephalometry, Facial profile, Orthognathic surgery, Natural head position, Supine position

Introduction

An accurate analysis of the patient is essential in orthognathic surgery in order to acquire an optimal surgical plan

suited for each individual. Usually the preoperative analytical modalities consist of radiographs (including cephalometric radiographs), clinical photos, study casts, and rapid protocols. All of these in combination aid in constructing

RECEIVED November 15, 2011, REVISED March 19, 2012, ACCEPTED May 4, 2012

Correspondence to Soon Jung Hwang

Department of Oral and Maxillofacial Surgery, Seoul National University Dental Hospital, School of Dentistry, Seoul National University 62-1, Changgyeonggung-ro, Jongno-gu, Seoul 110-768, Korea
Tel: 82-2-2072-3061, Fax: 82-2-766-4948, E-mail: sjhwang@snu.ac.kr

© This is an open access article distributed under the terms of the Creative Commons Attribution Non-Commercial License (<http://creativecommons.org/licenses/by-nc/3.0>) which permits unrestricted non-commercial use, distribution, and reproduction in any medium, provided the original work is properly cited.

an ideal individualized treatment plan for each patient[1].

Usually, the lateral cephalogram is used for profile analysis because it displays both hard and soft tissue. During acquisition of the cephalometric radiograph, the patient is required to stand with the clinical Frankfurt horizontal plane parallel to the floor. In normal circumstances, however, the patient usually places one's head in the natural head position. Natural head position (NHP) is the usual, balanced position of the head which is adopted for viewing the horizon or an object at eye level[2]. There are many influencing factors that could result in the production of differing profile radiographs. Such include the inclination of the neck, large discrepancies between centric occlusion and centric relation, lip tension, craniofacial morphology, and respiratory needs[3,4]. For example, patients with insufficient lip closure tend to force their lips closed during acquisition of lateral cephalograms thus, the acquired profile image may not be consistent with the patient's actual natural profile. The location of the soft tissue pogonion may also change according to the neck's inclination. All of these may influence the preoperative analysis, which may ultimately affect the amount of surgical movement[4].

There is usually a discrepancy between the profile in cephalometric radiographs and the profile in supine position. This is mainly because there is a change in the neck's inclination. Also, the forces of gravity cannot be ignored. This may be connected in the surgical situation. Lying on the operation table, the way a person's head is positioned may play a critical role in deciding the method of operation. This is especially sensitive in genioplasty, where the decision of performing genioplasty lies in the analysis of the patient's profile on the operating table at the final stages of orthognathic surgery. Other factors such as the way a person's spine is shaped may also have an effect in this.

The aim of this study is to analyze these different preoperative profile images and to compare their discrepancies, and finally to find best method for the reproduction of the patient's NHP.

Methods

Fifty eight patients (27 males and 31 females) ranging in age of 16 to 45 years, with a mean age of 24.2 were

identified for this study. The patients were all scheduled for bimaxillary orthognathic surgery. These patients were divided into three groups according to angle's classification of malocclusion, as class I (8 patients), II (8 patients), or III (42 patients). The distribution of patients is summarized in Table 1.

The preoperative photograph of the right profile in centric occlusion was taken in NHP. This was set as the 'actual profile image.' The photographs were taken with the patients in a relaxed standing position looking into the horizon ahead of them at eye level. Another right profile image was taken on the operating table on the day of the operation with the nasotracheal intubation in place and with muscle relaxants in effect. This was also taken in centric occlusion aided by rubber boxing. Thus, the preoperative images used were as follows:

- 1) Cephalograms
- 2) Right profile photograph taken in NHP
- 3) Right profile photograph taken in supine position

The angle (denoted 'A') between the soft tissue glabella-pogonion and the true vertical plane was found in the above-mentioned profile images and in the cephalometric radiographs (Fig. 1). The true vertical plane was set as 0° . If the pogonion was in a more anterior position than the glabella, the 'A' value was considered to be a negative value. The above-mentioned images were grouped in pairs and the differences in angle 'A' were analyzed for each patient (Fig. 1). Twenty seven of these patients did not have supine photographs available thus, they were excluded. However, these patients were included in the comparison between the cephalogram and the photograph taken in NHP.

Statistical data analysis was done between these groups using the paired t-test. All calculations were performed with a commercial statistical software package (SPSS 12.0 for Windows[®], SPSS Inc., Chicago, IL, USA). The level

Table 1. Patient distribution with relations to Angle's classification of malocclusion

Angle's classification	No. of patients	Percentage (%)
Class I	8	13.79
Class II	8	13.79
Class III	42	72.41
Total	58	100

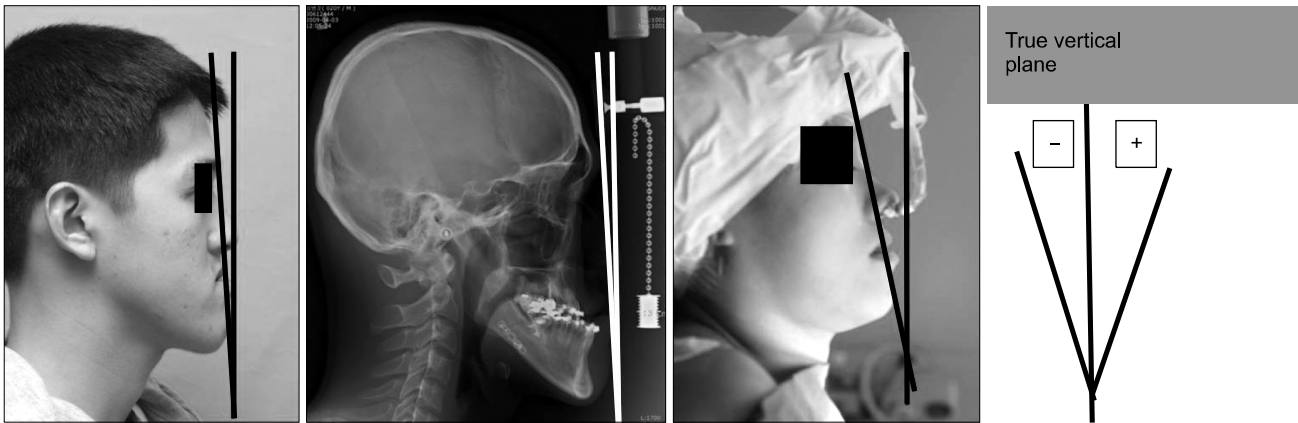


Fig. 1. The angle (denoted 'A') between the soft tissue glabella-pogonion and the true vertical plane was found in the three pre-operative images.

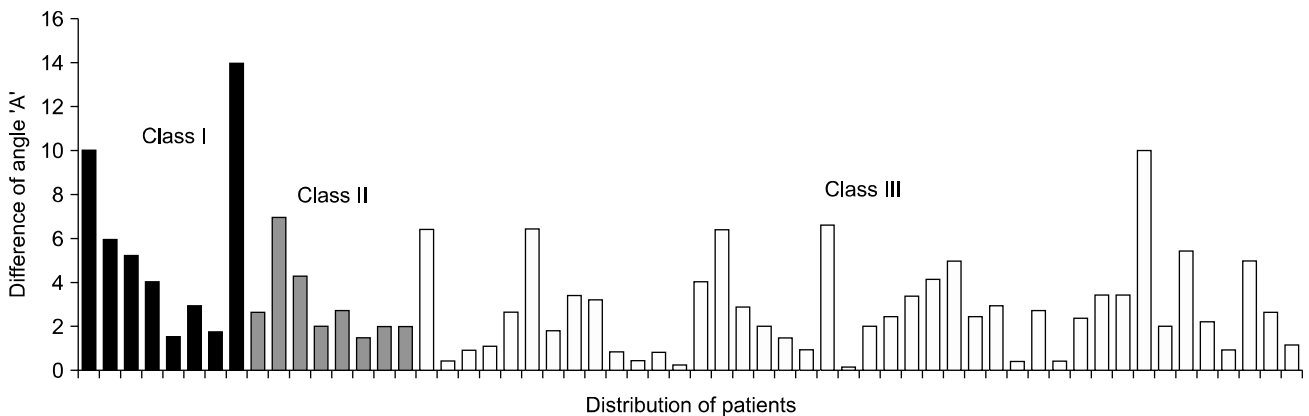


Fig. 2. Difference of angle 'A' between cephalograms and photographs taken in NHP in class I, II, III angle's classification for malocclusion. NHP, natural head position.

of statistical significance was set at $P \leq 0.05$.

Results

1. Cephalogram vs. photograph taken in NHP

The difference in angle 'A' of the two images ranged between 0.2 to 10 degrees, with a mean value of 3.62 degrees. Class I patients (n=8) showed a range of 1.8 to 10 degrees with a mean value of 5.71 degrees. Class II patients (n=8) displayed a range of 2 to 7 degrees with a mean value of 3.04 degrees. Class III patients (n=42) displayed a range of 0.2 to 10 degrees, with a mean value of 2.85 degrees. These values with respect to angle's classification are summarized in Table 2 and Fig. 2. These differences did not show to have statistical significance in relation to the different groups.

Table 2. Differences of angle 'A' between cephalogram and photograph taken in NHP

	Class I	Class II	Class III
n	8	8	42
Range (°)	1.8~10	2~7	0.2~10
Mean (°)	5.71	3.04	2.85
Standard deviation (°)	4.03	1.61	2.14

NHP, natural head position.

2. Clinical photograph taken in NHP vs. photograph taken in supine position

The difference in angle 'A' ranged between 0 to 13.5 degrees, with a mean value of 4.34. Class I patients (n=4) showed a range of 2.5 to 10 degrees with a mean value of 6.3 degrees. Class II patients (n=3) displayed a range of 2 to 6 degrees with a mean value of 3.67 degrees. Class III patients (n=24) displayed a range of 0 to 13.5

degrees. These values with respect to angle's classification are summarized in Table 3 and Fig. 3. These differences did not show to have statistical significance in relation to the different groups.

3. Cephalogram vs. photograph taken in supine position

The difference in angle 'A' ranged between 0 to 24 degrees, with a mean value of 5.07 degrees. Class I patients (n=4) showed a range of 5 to 24 degrees with a mean value of 11.75 degrees. Class II patients (n=3) displayed

a range of 0 to 4.75 degrees with a mean value of 4.17 degrees. Class III patients (n=24) displayed a range of 0 to 11.3 degrees, with a mean value of 4.07 degrees. These values with respect to angle's classification are summarized in Table 4 and Fig. 4. These differences displayed statistical significance in relations to the different groups ($P < 0.05$).

Discussion

The NHP is the usual, balanced position of the head

Table 3. Difference of angle 'A' in photographs taken in NHP and photographs taken in supine position

	Class I	Class II	Class III
n	4	3	24
Range (°)	2.5~10	2~6	0~13.5
Mean (°)	6.3	3.67	4.1
Standard deviation (°)	3.46	1.7	3.74

NHP, natural head position.

Table 4. Difference of angle 'A' in lateral cephalograms and photographs taken in supine position

	Class I	Class II	Class III
n	4	3	24
Range (°)	5~24	0~4.75	0~11.3
Mean (°)	11.75	4.17	4.07
Standard deviation (°)	7.67	3.12	3.02

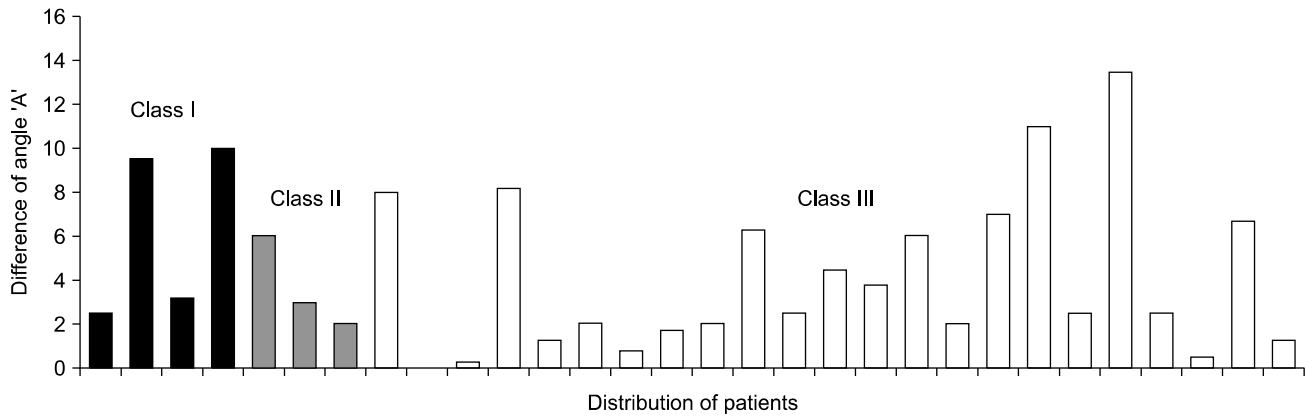


Fig. 3. Difference of angle 'A' between photographs taken in NHP and photographs taken in supine position in class I, II, III angle's classification for malocclusion. NHP, natural head position.

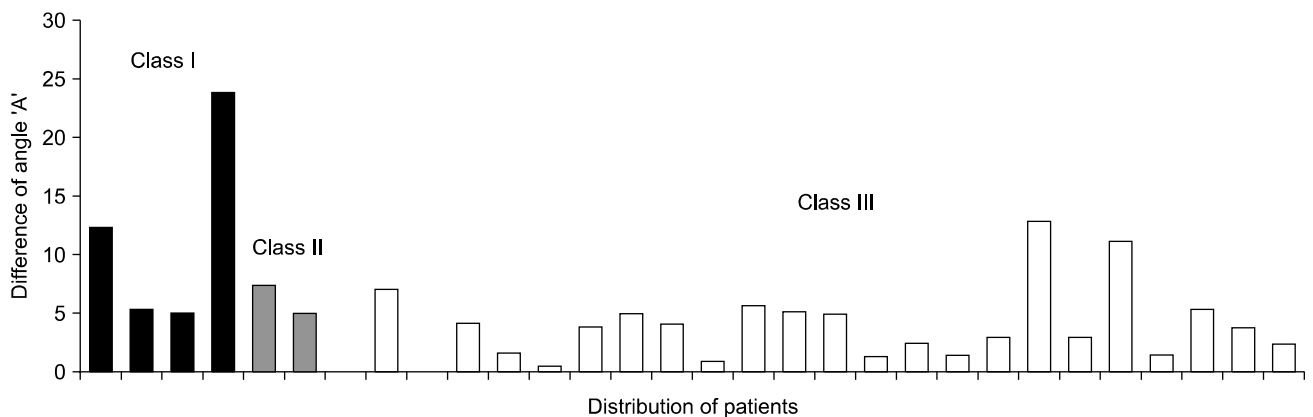


Fig. 4. Difference of angle 'A' between lateral cephalograms and photographs taken in supine position in class I, II, III angle's classification for malocclusion.

which is adopted for viewing the horizon or an object at eye level[2]. Because NHP is a physiological position it is considered to represent the esthetic and functional anatomical form of the craniofacial complex[2]. There have been many studies in the literature suggesting the NHP as a form of evaluation of the profile since it represents the true-life appearance of human beings[5]. However, there have been many debates on the reproducibility of this physiological position. Numerous studies have been done on the reproducibility/stability of NHP and have shown positive outcomes, both in short and long intervals[3,6-8].

The object of this study was to evaluate the discrepancies between the preoperative soft tissue profile analytical methods for orthognathic surgery, which includes the lateral cephalograms and clinical photographs (in NHP). These results provide a basis to determine the accuracy of the various preoperative data, thus providing a foundation for constructing a more accurate treatment plan for each patient when undergoing orthognathic surgery.

We used a specific angle in our study. The angle (denoted 'A') was the angle between the soft tissue glabella-pogonion and the true vertical plane (Fig. 1). Our results show that there are discrepancies in these angles between the various images. The angles in these images were compared in pairs for each patient. The difference in angle 'A' of the two types of images ranged from as little as 0 degrees to 24 degrees. The patients were divided according to the Angle's classification of malocclusion, however, this had no statistical significance. The discrepancy in the angles was clear in our results, however, they did not show statistical significance. There was however, a statistical significance in the difference of angle 'A' in the lateral cephalogram and the profile in supine position. The statistical difference shown in these two types of images could be attributed to the difference in neck inclination and the effects of muscle relaxants on the operating table. Our results suggest that the soft tissue appears different according to the different images and in the clinical situation, such as the operating table. This would be an important point to remember especially in procedures such as genioplasty where the decision in the amount and the method of this procedure rests upon the patient's profile at the final stages of orthognathic surgery.

Evaluation of the patients as they appear in life (i.e., according to NHP) seems of high clinical interest, where both esthetic and functional factors are to be considered. Several authors[6,9-11] proposed cephalometric analyses based on NHP determinations, which are probably of higher functional significance than standard intracranial references. Usually, the patient places one's head in the NHP which would display "true life appearance", thus it would be more esthetic to develop a treatment plan according to this. However, there are problems of reproducibility with regards to NHP. Some reports suggest that NHP is highly reproducible, irrespective of patient's age, gender or race, of the time lag between repeated recordings, of the radiographic or photographic technique, of the experience, or the cultural background of the operator[5,6,9]. However, other studies suggest that reproducible positioning of the patient in a cephalostat is less reliable than the NHP because of the use of external points which are difficult to determine, such as orbitale or nasion[12].

Conclusion

In order to gain an esthetic profile after orthognathic surgery, the NHP is shown to be the most logical position for treatment planning, as it represents the head position in the everyday-life. Preoperative cephalometric images show discrepancies to the NHP and this point should be considered in the treatment planning process. Attempts reproducing such head positions should be used in the diagnosis and treatment planning for orthognathic surgery.

References

1. Cooke MS, Wei SH. A summary five-factor cephalometric analysis based on natural head posture and the true horizontal. *Am J Orthod Dentofacial Orthop* 1988;9:213-23.
2. Barbera AL, Sampson WJ, Townsend GC. An evaluation of head position and craniofacial reference line variation. *Homo* 2009;60:1-28.
3. Peng L, Cooke MS. Fifteen-year reproducibility of natural head posture: a longitudinal study. *Am J Orthod Dentofacial Orthop* 1999;116:82-5.
4. Dvorsin DP, Ye Q, Pruijm GJ, Dijkstra PU, Ren Y. Reliability of the integrated radiograph-photograph method to obtain natural head position in cephalometric diagnosis. *Angle Orthod* 2011;81:889-94.
5. Lundström A, Lundström F, Le Bret LM, Moorrees CF. Natural head position and natural head orientation: basic consid-

- erations in cephalometric analysis and research. *Eur J Orthod* 1995;17:111-20.
6. Cooke MS. Five-year reproducibility of natural head posture: a longitudinal study. *Am J Orthod Dentofacial Orthop* 1990;97:489-94.
 7. Ferrario VF, Sforza C, Germanò D, Dalloca LL, Miani A Jr. Head posture and cephalometric analyses: an integrated photographic/radiographic technique. *Am J Orthod Dentofacial Orthop* 1994;106:257-64.
 8. Bister D, Edler RJ, Tom BD, Prevost AT. Natural head posture-considerations of reproducibility. *Eur J Orthod* 2002;24:457-70.
 9. Bass NM. The aesthetic analysis of the face. *Eur J Orthod* 1991;13:343-50.
 10. Showfety KJ, Vig PS, Matteson S, Phillips C. Associations between the postural orientation of sella-nasion and skeletal dental morphology. *Angle Orthod* 1987;57:99-112.
 11. Michiels LY, Tourne LP. Nasion true vertical: a proposed method for testing the clinical validity of cephalometric measurements applied to a new cephalometric reference line. *Int J Adult Orthodon Orthognath Surg* 1990;5:43-52.
 12. Luyk NH, Whitfield PH, Ward-Booth RP, Williams ED. The reproducibility of the natural head position in lateral cephalometric radiographs. *Br J Oral Maxillofac Surg* 1986;24:357-66.