

## Second Complete Remission of Relapsed Stage IV Non-Small Cell Lung Cancer Following Retreatment

Su Jin Yoo, M.D., Jeong Eun Lee, M.D., Sun Young Jung, M.D., Dong Il Park, M.D., Myoung Rin Park, M.D., Hee Sun Park, M.D., Sung Soo Jung, M.D., Ju Ock Kim, M.D., Sun Young Kim, M.D., Ph.D.

*Department of Internal Medicine, Chungnam National University Hospital & Cancer Research Institute, Chungnam National University School of Medicine, Daejeon, Korea*

Non-small cell lung cancer (NSCLC) is the leading cause of cancer related deaths. Most patients were presented with advanced disease at the time of diagnosis. In advanced NSCLC, it is almost impossible to anticipate complete remission by using only cytotoxic chemotherapy or molecularly targeted agents. In our case, two patients were diagnosed as advanced NSCLC and received chemotherapy. They achieved complete response (CR). After finishing treatment, disease recurred. They were retreated with the same regimens and achieved second CR. Until now, they have received each regimen, continuously, and the CR state has been maintained.

**Key Words:** Carcinoma, Non-Small-Cell Lung; Remission Induction; Retreatment; Maintenance Chemotherapy

### Introduction

Non-small cell lung cancer (NSCLC) is the leading cause of cancer related death worldwide. Most patients present with advanced disease at diagnosis, and approximately 75% of patients require chemotherapy after diagnosis or for disease recurrence<sup>1</sup>. The modest improvement in quality of life and overall survival with traditional chemotherapy has reached a plateau, and therefore more effective agents are needed. Newly developed molecularly targeted agents have improved overall survival or have demonstrated superior efficacy with reduced therapeutic toxicities in advanced NSCLC<sup>2</sup>. However, in advanced NSCLC, it is almost impossible to anticipate complete remission by using only cytotoxic chemotherapy or molecularly targeted agents.

We report two cases of advanced stage NSCLC with complete response (CR) after chemotherapy, followed by disease recurrence, and then finally with CR after retreatment.

### Case Report

#### 1. Case 1

In October 2006, a 51-year-old female without remarkable medical, social, or family history was admitted for cough. On the chest posteroanterior (PA) radiograph, a 7.2 cm sized mass was identified in the left upper lobe (LUL). It was diagnosed as an adenocarcinoma by bronchoscopic biopsy (positive immunohistochemical staining for cytokeratin [CK]-20 and negative for CK-7 and p63). The disease stage was IV (T4N3M1) (Figure 1A~C).

Six cycles of docetaxel (75 mg/m<sup>2</sup>) and cisplatin (75 mg/m<sup>2</sup>) combination therapy was administered as a first-line chemotherapy. Erlotinib, an epidermal growth factor receptor-tyrosine kinase inhibitor (EGFR-TKI) was administered for 2 months as second-line therapy. Because of disease progression, subsequent treatment with pemetrexed (500 mg/m<sup>2</sup>) was initiated as third-line

Address for correspondence: **Sun Young Kim, M.D., Ph.D.**

Department of Internal Medicine, Chungnam National University Hospital & Cancer Research Institute, Chungnam National University School of Medicine, 640, Daesa-dong, Jung-gu, Daejeon 301-721, Korea

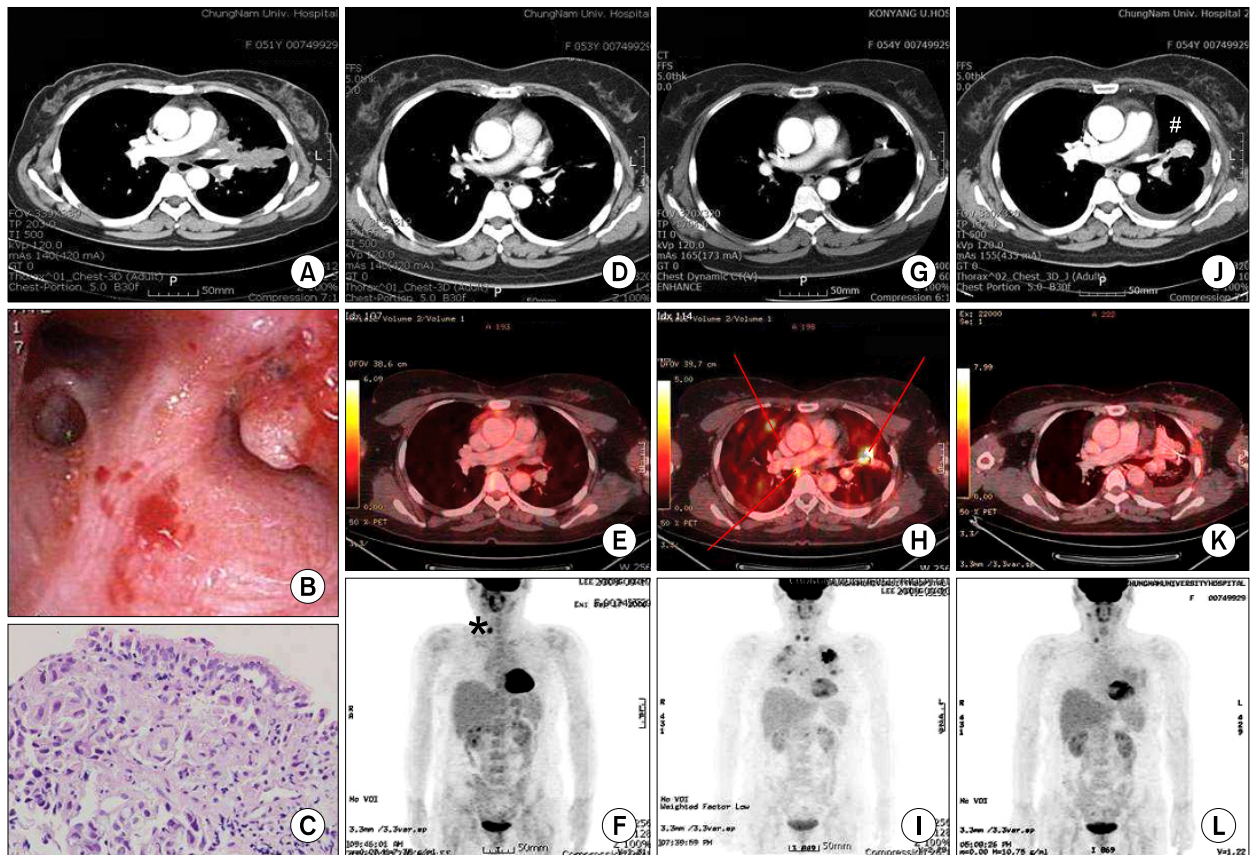
Phone: 82-42-220-7154, Fax: 82-42-257-5753

E-mail: sykim@cnu.ac.kr

Received: Sep. 2, 2011

Revised: Sep. 16, 2011

Accepted: Sep. 27, 2011



**Figure 1.** Summary from the initial diagnostic investigation to last follow-up. (A~C) Initial diagnostic investigation. (A) Chest computed tomography (CT). (B) Bronchoscopy. (C) Bronchoscopic biopsy (H&E stain,  $\times 400$ ). (D~F) Response evaluation after third-line pemetrexed treatment. \*Indicates hyroiditis confirmed by fine needle aspiration. (G~I) Response evaluation at 9 months after discontinuation of pemetrexed treatment. (J~L) Second complete response state after four cycles of pemetrexed retreatment. #Indicates fibrotic scar after CyberKnife treatment. (D, G, J) Chest CT. (E, F, H, I, K, L) Positron emission tomography-CT.

therapy from September 2007 at 3-week intervals. Positron emission tomography (PET)-computed tomography (CT) performed after nine cycles did not detect any metabolic evidence of cancer, and this was considered to indicate CR. Sixteen cycles of pemetrexed were administered as maintenance therapy. Chest CT and PET-CT, performed in September 2008, revealed a CR state (TONOMO) (Figure 1D, F). Although increased glucose metabolism was not detected, abnormal findings were observed in the brain area. Brain magnetic resonance imaging (MRI) indicated a Schwannoma, which was removed using a gamma knife. After the operation, the patient complained of generalized weakness and stopped chemotherapy. Follow-up was performed

regularly.

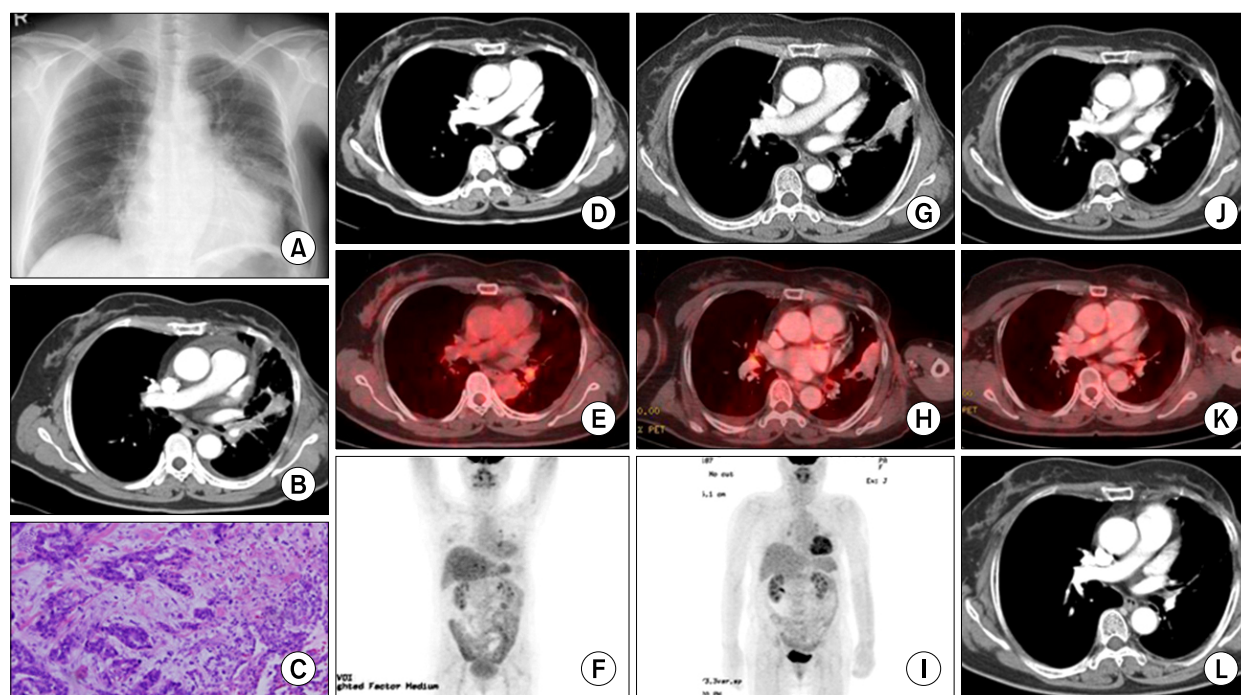
A recurred lung mass at the primary mass site was confirmed on a chest CT performed in June 2009, which was 15 months after CR and 9 months after therapy termination (Figure 1G). New lung and bone metastases appeared on PET-CT in September 2009 (Figure 1H, I). In October 2009, pemetrexed at the same dose was administered every 3-weeks. After four cycles in January 2010, no fluoro-2-deoxy-d-glucose uptake on PET-CT was observed (Figure 1J~L). This was deemed the second remission, and pemetrexed treatment has been subsequently maintained. The CR state was maintained on chest CT in July 2011.

## 2. Case 2

In September 2005, a 58-year-old female with a tuberculosis history, and without a history of drinking, smoking, or special findings in the family history, was admitted for cough. A mass in the LUL was detected on a chest PA radiograph (Figure 2A). The mass was diagnosed as an adenocarcinoma by wedge lung resection (positive immunohistochemical staining for thyroid transcription factor-1 (TTF-1) and CK-7 and negative for CK-20, CK-5/6, and calretinin (Figure 2C). The disease stage was IIIB (T4N2M0) (Figure 2B). No brain or bone metastases were detected on brain MRI or a whole body bone scan. Gemcitabine (1,000 mg/m<sup>2</sup>) and cisplatin (75 mg/m<sup>2</sup>) combination therapy was administered at 3-week intervals as first-line chemotherapy. However, progression was detected on a chest CT performed after three cycles. Subsequently, treatment with daily 150 mg erlotinib as second-line therapy was initiated in Decem-

ber 2005. A partial response (PR) continued on every follow-up chest CT scan. The lesions had almost disappeared on a chest CT performed after 5 months (Figure 2D). A PET-CT performed after 13 months did not detect any metabolic evidence of cancer and this was considered to indicate CR (Figure 2E, F). Erlotinib was administered for 38 months as maintenance therapy. The patient complained of severe anorexia and nausea, and she wanted to stop the erlotinib treatment. Follow-up was performed regularly.

A chest CT and PET-CT were performed in July 2009, and a recurred lung mass at the primary mass site was confirmed (Figure 2G~I), which was 38 months after CR and 5 months after therapy termination. The mass was diagnosed as an adenocarcinoma by percutaneous needle lung biopsy (positive immunohistochemical staining for TTF-1 and CK-7 and negative for CK-20, CK-5/6, and calretinin). After confirming disease progression in August 2009, erlotinib was administered at



**Figure 2.** Summary from the initial diagnostic investigation to last follow-up. (A~C) Initial diagnostic investigation. (A) Chest X-ray. (B) Chest computed tomography (CT). (C) Lung biopsy (H&E stain,  $\times 200$ ). (D) Response evaluation after 5 months treatment. (E, F) Response evaluation after 13 months treatment. (G~I) Response evaluation at 5 months after discontinuation of erlotinib treatment. (J, K) Second complete response state after 2 months of erlotinib retreatment. (D, G, J) Chest CT. (E, F, H, I, K) Positron emission tomography-CT. (L) Chest CT (July 2011).

the initial dose. The lesions had almost disappeared on the chest CT and the PET-CT after 2 months (Figure 2J, K). This was deemed the second remission, and erlotinib treatment has been subsequently maintained. A chest CT in July 2011 indicated that the CR state was maintained (Figure 2L).

## Discussion

In our cases, the two patients were diagnosed with advanced NSCLC and received chemotherapy with pemetrexed as the third-line and erlotinib as the second-line therapy, respectively, and they achieved CR. However, they unfortunately stopped treatment, resulting in disease recurrence. After recurrence, they were retreated with the same regimens (pemetrexed and erlotinib, respectively) and achieved a second CR. Until now, they have received these regimens continuously and have maintained a CR state.

The efficacy of chemotherapy is modest or disappointing in patients with advanced NSCLC. These cases are worthy of noting due to the dramatic response and CR achieved by the same drug. In these cases, we must consider characteristics of relapsed cancer cells and the importance and duration of maintenance therapy.

Relapsed cancer cells are probably homogenous with specific characteristics that meet the targets of each drug. Predictable markers for specific drugs should be identified at the initial work-up. Recently, EGFR-TKI was approved as first-line treatment in an *EGFR* mutation positive group. Searching for specific targets in patients will allow for prolonged survival and a good quality of life.

Another issue concerning NSCLC treatment is maintenance therapy, in which the duration of chemotherapy is prolonged by administering additional drugs in patients who have not progressed or who have achieved a response. According to the National Comprehensive Cancer Network guideline 2011 v3, maintenance treatment is divided into continuation maintenance and switch maintenance. Continuation maintenance refers to

the use of at least one of the agents given first-line, beyond 4~6 cycles, in the absence of disease progression. Bevacizumab (category 1), cetuximab (category 1), and pemetrexed (category 2B) can be used for continuation maintenance. Switch maintenance refers to the initiation of a different agent, not included as part of the first-line regimen, in the absence of disease progression after 4~6 cycles of initial therapy. Pemetrexed, erlotinib (category 2B), and docetaxel (category 3) can be used. We expect prolonged progression free survival (PFS) through the use of maintenance therapy and a decreased dropout rate after first-line treatment based on previous data. In the phase III, placebo-controlled Sequential Tarceva in Unresectable NSCLC (SATURN) study, PFS was significantly prolonged by erlotinib vs. a placebo in the overall population, irrespective of gender, ethnic origin, smoking status, or EGFR status (median PFS, 12.3 weeks vs. 11.1 weeks; hazard ratio [HR], 0.71; 95% confidence interval [CI], 0.62~0.82;  $p < 0.0001$ ) and in patients who are EGFR immunohistochemistry positive (median PFS, 12.3 weeks vs. 11.1 weeks; HR, 0.69; 95% CI, 0.58~0.82;  $p < 0.0001$ )<sup>3</sup>. Yokouchi et al.<sup>4</sup> retrospectively evaluated the clinical courses of 27 patients with NSCLC who received gefitinib and achieved either a CR or PR. Some of the patients who experienced disease progression after responding to gefitinib were again sensitive to readministration of gefitinib following temporary cessation of gefitinib and other treatments<sup>4</sup>. There is great potential to produce a dramatic response after maintenance therapy in homogenous tumors such as these cases. However, they were likely to acquire a good response by retreatment for the progression after the general treatment schedule. Intermittent treatment is an option in this group.

However, acquired resistance to chemotherapeutic agents easily appears and we can not predict acquired resistance. But, it is certain that someone had homogenous characteristics regardless of advanced stage and less acquired resistance.

Retreatment of patients with small cell lung cancer (SCLC) with the original regimen was used in a sensitive

relapse group that maintained a response over 6 months after the original regimen<sup>5</sup>. This rule cannot be applied in patients with NSCLC. If valid markers for sensitive relapse are discovered, these controversies will be solved.

We must also consider the toxicity of retreatment or maintenance treatment. Cara and Tannock<sup>6</sup> reviewed 18 articles regarding retreatment toxicity for relapsed cancer with the same therapy, including four studies about SCLC. Toxicity associated with retreatment was similar or greater than that experienced during initial treatment<sup>6</sup>.

No guidelines exist to determine how long maintenance therapy is needed for patients who reach CR. Furthermore, there are no guidelines of how to treat relapsed cancer after CR. We need guidelines for retreatment using the same therapy and maintenance therapy considering toxicity and more predictable biomarkers for sensitive relapse, tumor heterogeneity, and acquired resistance. We also require additional clinical trials about duration or schedule of treatment in cases that have reached CR, particularly those with a homogenous tumor character.

## References

1. DeVita VT, Hellman S, Rosenberg SA. Cancer: principles and practice of oncology. 7th ed. Philadelphia: Lippincott Williams & Wilkins; 2005.
2. Lee SY, Park JY. Personalized therapy in lung cancer: focused on molecular targeted therapy. *J Lung Cancer* 2011;10:1-12.
3. Cappuzzo F, Ciuleanu T, Stelmakh L, Cicens S, Szczésna A, Juhász E, et al. Erlotinib as maintenance treatment in advanced non-small-cell lung cancer: a multicentre, randomised, placebo-controlled phase 3 study. *Lancet Oncol* 2010;11:521-9.
4. Yokouchi H, Yamazaki K, Kinoshita I, Konishi J, Asahina H, Sukoh N, et al. Clinical benefit of readministration of gefitinib for initial gefitinib-responders with non-small cell lung cancer. *BMC Cancer* 2007;7: 51.
5. National Comprehensive Cancer Network. NCCN clinical practice guidelines in oncology: small cell lung cancer, v.3. Fort Washington, PA: National Comprehensive Cancer Network; 2011.
6. Cara S, Tannock IF. Retreatment of patients with the same chemotherapy: implications for clinical mechanisms of drug resistance. *Ann Oncol* 2001;12:23-7.