

## A Case of Balsalazide-Induced Limited Form of Granulomatosis with Polyangiitis with Bronchiolitis Obliterans Organizing Pneumonia-like Variant in Ulcerative Colitis

Shin Myung Kang, M.D.<sup>1</sup>, Young Rock Jang, M.D.<sup>1</sup>, Hyun-Hwa Yoon, M.D.<sup>1</sup>, Suji Kim, M.D.<sup>1</sup>, Eun Young Kim, M.D.<sup>2</sup>, Seung Yeon Ha, M.D.<sup>3</sup>, Jeong-Woong Park, M.D.<sup>1</sup>

Departments of <sup>1</sup>Pulmonary and Critical Care Medicine, <sup>2</sup>Radiology, and <sup>3</sup>Pathology, Gachon University Gil Hospital, Incheon, Korea

5-Aminosalicylate agents are the main therapeutic agents for ulcerative colitis. Balsalazide is a prodrug of 5-aminosalicylate and has fewer side effects than the other 5-aminosalicylate agents. Pulmonary complications resembling granulomatosis with polyangiitis in ulcerative colitis are extremely rare. Here, we report a patient with ulcerative colitis on balsalazide presenting respiratory symptoms and multiple pulmonary nodules from a chest radiography that was pathologically diagnosed with a limited form of granulomatosis with polyangiitis with bronchiolitis obliterans organizing pneumonia-like variant. To our knowledge, this is the first report of a balsalazide-induced limited form of granulomatosis with polyangiitis with bronchiolitis obliterans organizing pneumonia-like variant.

**Key Words:** Balsalazide; Wegener Granulomatosis; Colitis, Ulcerative

### Introduction

Balsalazide is a non-sulfa-based 5-aminosalicylate (5-ASA) prodrug used for the treatment of ulcerative colitis (UC)<sup>1,2</sup>. To reduce the adverse effects caused by a sulfapyridine moiety of sulfasalazine, balsalazide was developed to liberate 5-ASA by colonic bacteria from an inert carrier molecule instead of the sulfapyridine moiety. Due to clinical efficacy, good tolerability, and fewer side effects of balsalazide, balsalazide is now widely used as the first choice for the treatment of UC<sup>1,2</sup>.

Sulfasalazine or mesalazine could induce pulmonary toxicities, such as eosinophilic and interstitial pneumo-

nitic, bronchiolitis obliterans organizing pneumonia (BOOP), and eosinophilic pleural effusion, but their occurrence is rare<sup>3-7</sup>. Pulmonary complications resembling granulomatosis with polyangiitis (GPA) in UC are extremely rare<sup>8-12</sup>. Here, we report a patient with UC on balsalazide presenting respiratory symptoms and multiple pulmonary nodules on chest radiography and pathologically diagnosed with a limited form of GPA with BOOP-like variant. To our knowledge, this is the first report of a balsalazide-induced limited form of GPA with BOOP-like variant.

### Case Report

A 31-year-old female patient was referred to our hospital for further evaluation of multiple nodular lesions observed on chest radiography and chest computed tomography (CT) scans. She complained of left-side chest pain on inspiration and dry cough over the previous two weeks. The physical examination was noncontributory except for inspiratory crackles on the left lower

Address for correspondence: **Jeong-Woong Park, M.D.**

Department of Pulmonary and Critical Care Medicine, Gachon University Gil Hospital, 1198, Guwol-dong, Namdong-gu, Incheon 405-760, Korea

Phone: 82-32-460-8416, Fax: 82-32-469-4320

E-mail: jwpark@gilhospital.com

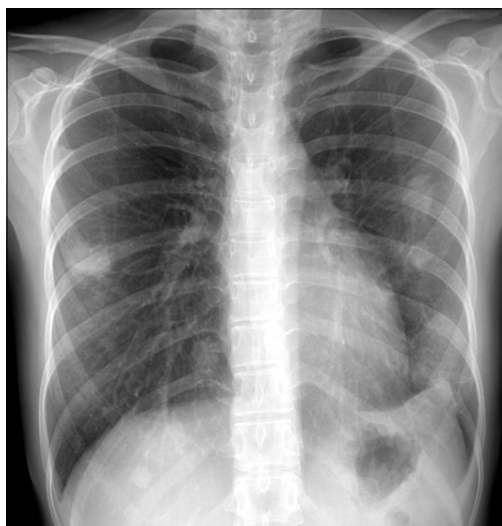
Received: Jan, 9, 2012

Revised: Jan, 12, 2012

Accepted: Jan, 27, 2012

lung fields. Seven months before the visit, she had received a diagnosis of UC at a general hospital. Balsalazide (Colazal<sup>TM</sup>; Chong Kun Dang, Seoul, Korea; 2.25 g, orally, three times a day) was started from the diagnosis and used regularly until the visit of our hospital. She was also treated with mesalazine enemas (2 g/30 mL, twice daily) for 4 weeks after the diagnosis.

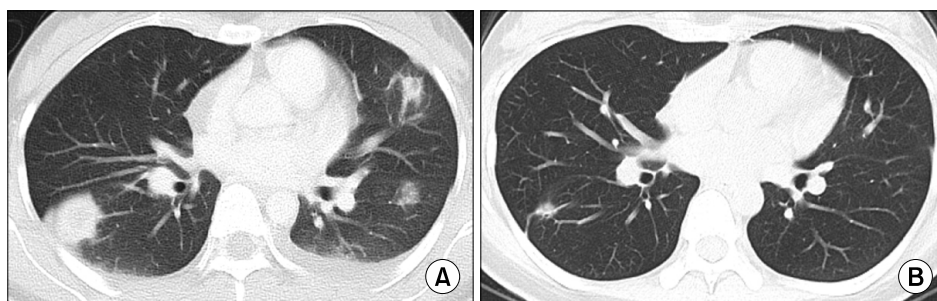Chest radiography showed multiple nodular opacities of varying size in both lungs (Figure 1). Chest CT scan revealed multiple focal consolidative lesions located predominantly in the periphery of both lower lobes, and a small amount of left pleural effusion (Figure 2A).



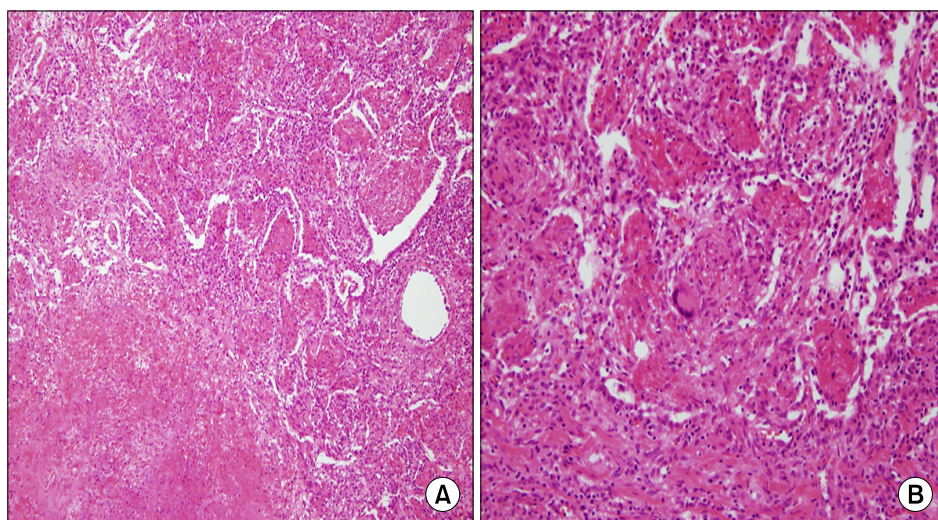
**Figure 1.** Chest radiography shows multiple nodular opacities of varying size in both lungs.

Laboratory tests revealed normal values of complete blood cell count, electrolytes, chemistry profile, and arterial blood gas analysis. Erythrocyte sedimentation rate (30 mm/hr) and C-reactive protein concentration (3.30 mg/dL; reference range,  $\leq 0.5$  mg/dL) were slightly increased. Tests for serum rheumatoid factor and fluorescent antinuclear antibodies were negative. Antineutrophil cytoplasmic antibodies (ANCA) against proteinase 3 (cANCA) or myeloperoxidase (pANCA) tests were negative. There is no abnormal finding in urine analysis. Pulmonary function tests showed a mild restrictive pattern: forced vital capacity (FVC) of 1.89 L (69% of predicted value), forced expiratory volume in the first second (FEV<sub>1</sub>) of 2.14 L (62% of predicted value), and FEV<sub>1</sub>/FVC of 88%.

Bronchoscopy with bronchoalveolar lavage (BAL) was performed to evaluate nodular infiltrative lesions and rule out infection or malignancy. There is no endobronchial lesion on bronchoscopy. BAL fluid recovered from the lingular segment of the left upper lobe showed prominent lymphocytosis (40% of lymphocytes, 55% of macrophages, and 5% of neutrophils). No malignant cells were observed in BAL cytological analysis. BAL cultures for viruses, bacteria and fungi were negative. For confirmative diagnosis of the pulmonary lesions, video-assisted thoracoscopic surgery was performed. Surgical specimens obtained from the left lower lobe revealed extensive necrosis with intraluminal organization that resembled BOOP (Figure 3A). Distinct multinu-



**Figure 2.** (A) Initial chest computed tomography (CT) image shows multiple nodular infiltrates located predominantly in the periphery of both lower lobes and a small amount of pleural effusion in the left hemithorax. (B) Three months after the discontinuation of balsalazide, a chest CT shows marked improvements or complete resolution of nodular infiltrates in both lungs and disappearance of the left pleural effusion.



**Figure 3.** (A) Extensive necrosis with plugs of fibroblasts and fibrin within the alveolar space and alveolar duct look like BOOP (H&E stain,  $\times 100$ ). (B) High magnification shows a small granuloma with multinucleated giant cells (H&E stain,  $\times 200$ ). BOOP: bronchiolitis obliterans organizing pneumonia.

cleated giant cells were observed within the intraalveolar fibrosis (Figure 3B). Necrotizing vasculitis was also observed. These pathologic findings are consistent with GPA with BOOP-like variant. The patient had no abnormalities in nasopharyngoscopic examination. Therefore, we could conclude that the patient had a limited form of GPA with BOOP-like variant.

Predominant BAL lymphocytosis (lymphocyte  $\geq 25\%$ ) is likely to be caused by interstitial lung disease associated with granuloma formation such as sarcoidosis or hypersensitivity pneumonitis<sup>13</sup>. Drug toxicity, cellular nonspecific interstitial pneumonia, lymphoid interstitial pneumonia, or lymphoproliferative disorders also cause predominant BAL lymphocytosis<sup>13</sup>. Because infectious or malignant conditions were excluded and there were no clinical manifestations suggesting the above-mentioned interstitial lung diseases, balsalazide toxicity is highly suspected for the development of a limited form of GPA with BOOP-like variant in this patient. To assess the possible relationship, we decided to follow up on the patient without balsalazide treatment. Three weeks after the discontinuation of balsalazide, the nodular infiltrative lesions decreased in size and the amount of pleural effusion was reduced on chest radiography. Thereafter, we used 20 mg of prednisolone for one week with the expectation of rapid resolution of symptoms and radiographic abnormalities. A chest CT obtained three months after the discontinuation of balsala-

zide displayed marked improvements or the complete disappearance of nodular infiltrative lesions and left pleural effusion (Figure 2B). Finally, we concluded that the patient had a balsalazide-induced limited form of GPA with BOOP-like variant.

## Discussion

Balsalazide is a prodrug of 5-ASA which is linked via a diazo-bond to 4-aminoenzoyl- $\beta$ -alanine, an inert and biologically inactive carrier molecule<sup>1,2</sup>. After being orally administered, colonic bacteria split balsalazide into 5-ASA and 4-aminoenzoyl- $\beta$ -alanine. Thus, balsalazide is active in the colon with minimal systemic absorption. Mesalazine, on the other hand, is absorbed into the terminal ileum and/or colon. Clinically, balsalazide has gained popularity for use in the treatment of UC due to equivalent efficacy and fewer side effects to comparable medications.

Pulmonary manifestations of UC are rare. Bronchiectasis, inflammatory tracheal stenosis, panbronchiolitis, chronic bronchitis, and BOOP have been reported as pulmonary manifestations of UC<sup>8</sup>. Sulfasalazine or mesalazine could induce pulmonary toxicities including interstitial pneumonitis, eosinophilic pneumonia, BOOP, and eosinophilic pleural effusion<sup>3-8</sup>.

Pulmonary complications resembling GPA in UC are extremely rare. We could find only 7 cases reported<sup>8-12</sup>.

Of these cases, 5 were associated with 5-ASA agents at the time of lung presentations<sup>8-12</sup>, but 2 cases were manifested in the absence of 5-ASA agents<sup>8,12</sup>. There is no report of balsalazide-associated GPA as a pulmonary complication during the treatment of UC up to now. Among the seven cases, 4 cases were identified as a limited form of GPA<sup>8,9,12</sup>. Yano et al,<sup>9</sup> reported a case of a limited form of GPA with BOOP-like variant similar to ours. But this case was associated with mesalazine.

The interval from diagnosis of UC to pulmonary complications resembling GPA varies widely from 9 months to 25 years in previous cases<sup>8-12</sup>. In our case, 7 months elapsed from the diagnosis of UC to the development of a limited form of GPA with BOOP-like variant, which is the shortest time interval ever recorded. Thus, development of GPA should be considered at any time in the course of UC, especially on 5-ASA agents.

In this case, tests for ANCA were negative. The majority of patients with UC (50~80%) showed pANCA-positive. Up to 90% of patients with active GPA are ANCA positive, of whom the majority are cANCA positive. All the previous cases of pulmonary complications resembling GPA in UC were ANCA-positive<sup>8-12</sup>. A small portion of ANCA-negative GPAs was reported in individuals with GPA symptoms limited to the ears, nose, throat, and lungs<sup>14</sup>.

Most cases of GPA in UC were treated with glucocorticoids<sup>10</sup>. But the clinical responses to therapeutic interventions were diverse. One case showed a relapse of lung disease after adding prednisolone without discontinuation of mesalazine, thus mesalazine should have to be stopped<sup>9</sup>. One case showed clinical and radiographic improvements with only the discontinuation of sulfasalazine<sup>11</sup>, but another one showed radiographic improvements without any treatment or discontinuation of mesalazine<sup>10</sup>. Our case showed marked improvements with the discontinuation of balsalazide and a one-week course of prednisolone.

Drug lymphocyte stimulation test for balsalazide may be helpful to support the causal relationship between balsalazide use and the development of GPA. But we did not perform it. A drug lymphocyte stimulation test

was performed in two cases to show the association of drugs and GPA in patients with UC<sup>9,10</sup>. Since respiratory symptoms and radiographic abnormalities were markedly improved after the discontinuation of balsalazide under the high suspicion of balsalazide as the cause of them, we considered this case a balsalazide-induced limited form of GPA with BOOP-like variant.

Here, we described a patient with UC on balsalazide presenting respiratory symptoms and multiple pulmonary nodules from a chest radiography and pathologically diagnosed with a limited form of GPA with BOOP-like variant. To our knowledge, this is the first report of a limited form of GPA with BOOP-like variant induced by balsalazide. A limited form of GPA with BOOP-like variant should be considered in the differential diagnosis as a pulmonary complication in patients with UC on balsalazide.

## References

1. Wiggins JB, Rajapakse R. Balsalazide: a novel 5-aminosalicylate prodrug for the treatment of active ulcerative colitis. *Expert Opin Drug Metab Toxicol* 2009;5:1279-84.
2. Tursi A. Balsalazide in treating colonic diseases. *Expert Opin Drug Metab Toxicol* 2009;5:1555-63.
3. Muzzi A, Ciani F, Bianchini D, Festini G, Volpe C. Adverse pulmonary effects of mesalamine. *Chest* 1995; 108:1181.
4. Park JE, Hwangbo Y, Chang R, Chang YW, Jang JY, Kim BH, et al. Mesalazine-induced eosinophilic pneumonia in a patient with Crohn's disease. *Korean J Gastroenterol* 2009;53:116-20.
5. Tanigawa K, Sugiyama K, Matsuyama H, Nakao H, Kohno K, Komuro Y, et al. Mesalazine-induced eosinophilic pneumonia. *Respiration* 1999;66:69-72.
6. Bitton A, Peppercorn MA, Hanrahan JP, Upton MP. Mesalamine-induced lung toxicity. *Am J Gastroenterol* 1996;91:1039-40.
7. Foster RA, Zander DS, Mergo PJ, Valentine JF. Mesalamine-related lung disease: clinical, radiographic, and pathologic manifestations. *Inflamm Bowel Dis* 2003;9: 308-15.
8. Camus P, Piard F, Ashcroft T, Gal AA, Colby TV. The lung in inflammatory bowel disease. *Medicine (Baltimore)* 1993;72:151-83.

9. Yano S, Kobayashi K, Kato K, Nishimura K. A limited form of Wegener's granulomatosis with bronchiolitis obliterans organizing pneumonitis-like variant in an ulcerative colitis patient. *Intern Med* 2002;41:1013-5.
10. Kasuga A, Mandai Y, Katsuno T, Sato T, Yamaguchi T, Yokosuka O. Pulmonary complications resembling Wegener's granulomatosis in ulcerative colitis with elevated proteinase-3 anti-neutrophil cytoplasmic antibody. *Intern Med* 2008;47:1211-4.
11. Salerno SM, Ormseth EJ, Roth BJ, Meyer CA, Christensen ED, Dillard TA. Sulfasalazine pulmonary toxicity in ulcerative colitis mimicking clinical features of Wegener's granulomatosis. *Chest* 1996;110:556-9.
12. Stebbing J, Askin F, Fishman E, Stone J. Pulmonary manifestations of ulcerative colitis mimicking Wegener's granulomatosis. *J Rheumatol* 1999;26:1617-21.
13. Meyer KC, Raghu G. Bronchoalveolar lavage for the evaluation of interstitial lung disease: is it clinically useful? *Eur Respir J* 2011;38:761-9.
14. Khan A, Lawson CA, Quinn MA, Isdale AH, Green MJ. Successful treatment of ANCA-negative Wegener's granulomatosis with rituximab. *Int J Rheumatol* 2010;2010:846063.